

Transcatheter interventions for left-sided valvular heart disease complicated by cardiogenic shock: a consensus statement from the European Association of Percutaneous Cardiovascular Interventions (EAPCI) in collaboration with the Association for Acute Cardiovascular Care (ACVC) and the ESC Working Group on Cardiovascular Surgery

Chiara Fraccaro^{1*}, MD, PhD; Nicole Karam², MD, PhD; Helge Möllmann³, MD, PhD; Sabine Bleiziffer⁴, MD; Nikolaos Bonaros⁵, MD, PhD, MSc; Rui Campante Teles⁶, MD, PhD; Pedro Carrilho Ferreira⁷, MD; Alaide Chieffo⁸, MD; Martin Czerny^{9,10}, MD; Erwan Donal¹¹, MD; Dariusz Dudek¹², MD; Nicolas Dumonteil¹³, MD; Giovanni Esposito¹⁴, MD, PhD; Stephane Fournier¹⁵, MD, PhD; Christian Hassager¹⁶, MD, DMSc; Won-Keun Kim³, MD, PhD; Konstantin A. Krychtiuk^{17,18}, MD; Julinda Mehilli^{19,20}, MD; Jerzy Pręgowski²¹, MD; Giulio G. Stefanini^{22,23}, MD, PhD; Julien Ternacle^{24,25}, MD, PhD; Holger Thiele²⁶, MD, PhD; Matthias Thielmann²⁷, MD; Flavien Vincent²⁸, MD; Ralph Stephan von Bardeleben²⁹, MD; Giuseppe Tarantini¹, MD, PhD

The authors' affiliations can be found in the Appendix paragraph.

C. Fraccaro, N. Karam and H. Möllmann contributed equally to this work.

This paper also includes supplementary data published online at: <https://eurointervention.pconline.com/doi/10.4244/EIJ-D-23-00473>

KEYWORDS

- acute heart failure
- aortic regurgitation
- aortic stenosis
- mitral regurgitation
- mitral stenosis
- TAVI

Abstract

Valvular heart disease (VHD) is one of the most frequent causes of heart failure (HF) and is associated with poor prognosis, particularly among patients with conservative management. The development and improvement of catheter-based VHD interventions have broadened the indications for transcatheter valve interventions from inoperable/high-risk patients to younger/lower-risk patients. Cardiogenic shock (CS) associated with severe VHD is a clinical condition with a very high risk of mortality for which surgical treatment is often deemed a prohibitive risk. Transcatheter valve interventions might be a promising alternative in this setting given that they are less invasive. However, supportive scientific evidence is scarce and often limited to small case series. Current guidelines on VHD do not contain specific recommendations on how to manage patients with both VHD and CS. The purpose of this clinical consensus statement, developed by a group of international experts invited by the European Association of Percutaneous Cardiovascular Interventions (EAPCI) Scientific Documents and Initiatives Committee, is to perform a review of the available scientific evidence on the management of CS associated with left-sided VHD and to provide a rationale and practical approach for the application of transcatheter valve interventions in this specific clinical setting.

*Corresponding author: Interventional Cardiology Unit, Department of Cardiac, Thoracic, Vascular Sciences and Public Health, University of Padua, 2, Via Giustiniani, 35100 Padova, Italy. E-mail: chiarafaccaro980@gmail.com

Abbreviations

AMI	acute myocardial infarction
AR	aortic regurgitation
AS	aortic stenosis
BAV	balloon aortic valvuloplasty
BVF	bioprosthetic valve failure
CAD	coronary artery disease
CO	cardiac output
CS	cardiogenic shock
EACTS	European Association for Cardio-Thoracic Surgery
EAPCI	European Association of Percutaneous Cardiovascular Interventions
ESC	European Society of Cardiology
HF	heart failure
HVD	haemodynamic valve deterioration
IABP	intra-aortic balloon pump
ICA	invasive coronary angiography
LA	left atrium/atrial
LV	left ventricular
LVAD	left ventricular assist device
LVEF	left ventricular ejection fraction
MCS	mechanical circulatory support
MR	mitral regurgitation
MS	mitral stenosis
MSCT	multislice computed tomography
PCI	percutaneous coronary intervention
PMBV	percutaneous mitral balloon valvuloplasty
PVL	paravalvular leak
RCT	randomised controlled trial
SCAI	Society for Cardiovascular Angiography and Interventions
SVD	structural valve deterioration
TAVI	transcatheter aortic valve implantation
TEER	transcatheter edge-to-edge repair
TMVI	transcatheter mitral valve implantation
TOE	transoesophageal echocardiography
TTE	transthoracic echocardiography
VA-ECMO	venoarterial extracorporeal membrane oxygenation
VHD	valvular heart disease

Introduction

Valvular heart disease (VHD) is among the most frequent causes of heart failure (HF) and is associated with poor prognosis, particularly when managed conservatively^{1,2}. Acute valvular emergencies comprise approximately 8% of coronary care unit admissions³, but it is unclear how many patients with acute HF develop cardiogenic shock (CS)⁴⁻⁷. Transcatheter valve interventions provide treatment options for a subset of patients with VHD at prohibitive or very high surgical risk. Moreover, technological advances have broadened their indication to younger or lower-risk patients and even to less symptomatic or moderate VHD⁸. Conversely, patients with VHD and CS are generally excluded from randomised controlled trials (RCT) exploring these technologies, and less evidence is

available in this setting. Therefore, the 2021 European Society of Cardiology (ESC) and European Association for Cardio-Thoracic Surgery (EACTS) Guidelines for VHD⁹ did not include specific sections for VHD patients presenting with CS. Treatment strategies are left to the discretion of multidisciplinary Heart Teams in a case-by-case fashion, weighing risks and benefits to identify those likely to benefit from interventions and avoid futility.

The purpose of this consensus statement, developed by international experts invited by the European Association of Percutaneous Cardiovascular Interventions (EAPCI) Scientific Documents and Initiatives Committee, is to provide a practical approach to transcatheter valve intervention use in patients with left-sided VHD and CS, based on the available scientific evidence.

Definition of cardiogenic shock

Cardiogenic shock (CS) is a clinical syndrome characterised by life-threatening organ hypoperfusion, which is caused by low cardiac output (CO) due to primary cardiac pump failure despite adequate volume preload¹⁰⁻¹⁴. Varying definitions of CS exist (**Supplementary Table 1**). A consistent part of CS evidence stems from patients with acute myocardial infarction (AMI), while evidence for other aetiologies is increasing¹⁵. The Society for Cardiovascular Angiography and Interventions (SCAI) recently published a disease severity classification in an effort to make CS patients more comparable for clinical and research purposes^{16,17}.

We defined CS associated with VHD as significant VHD combined with systolic blood pressure <90 mmHg for >30 mins OR the need of vasopressors to maintain systolic blood pressure >90 mmHg, elevated serum lactate levels and clinical signs of end-organ hypoperfusion (including cool sweaty extremities, altered mental status, oliguria), corresponding to SCAI stage \geq C.

Clinical scenarios of CS and VHD

ACUTE ONSET OF NEW SEVERE VHD

CS may be due to an acute onset of severe VHD, such as ischaemic mitral regurgitation (MR), often related to AMI. Functional MR due to left ventricular (LV) global or regional remodelling or ischaemic papillary muscle dysfunction may resolve after revascularisation and recovery of LV function, or it may persist and require treatment. Acute MR may also be related to chord rupture. Acute severe AR commonly leads to CS^{18,19} and is caused by type A aortic dissection, rupture of a fenestrated aortic valve or endocarditis, typically requiring surgical correction¹⁹. Other rare situations are iatrogenic or traumatic aortic valve injury, or AR in left ventricular assist device (LVAD) patients. Acute severe VHD may also be related to bioprosthetic valve failure (BVF)^{19,20}.

DETERIORATION OF CHRONIC VHD

Pre-existing moderate to severe clinically stable VHD can turn into acute decompensated HF and CS with various cardiac or non-cardiac triggers.

For BVF, patients in CS should have at least severe haemodynamic valve deterioration (HVD) (i.e., Stage 3)²⁰ for valve-related

haemodynamic instability. All causes of BVF may lead to severe HVD, including 1) structural valve deterioration (SVD; i.e., cusp tear); 2) non-structural valve dysfunction (i.e., paravalvular leak [PVL]); 3) thrombosis; or 4) endocarditis (**Figure 1**).

The primary approach should address the triggering condition. However, transcatheter interventions can be used as a bailout strategy in complex cases or when the trigger, such as pregnancy, persists.

CARDIOVASCULAR TRIGGERS

a. *Atrial fibrillation and other (supra)ventricular arrhythmias*: while left-sided VHD precipitates the occurrence of atrial fibrillation, the latter complicates moderate to severe left-sided valvular stenosis. In the SEAS trial, at 4-year follow-up, 6% of patients with mild to moderate aortic stenosis (AS) developed atrial fibrillation²¹. In AS and mitral stenosis (MS), a rapid heart rate and loss of the atrial contraction limit the filling time of the LV. Restoration of sinus rhythm is crucial, although this is difficult to achieve, particularly in MS.

b. *AMI*: AS is not uncommon in AMI patients, and this combination is independently associated with short- and long-term mortality²². Impaired ischaemic LV contractility further reduces CO, and AS increases afterload, creating a vicious circle that leads

to CS. Treatment is challenging because inotropic drugs and diuretics increase intraventricular pressure, increasing haemodynamic impairment and gradient.

c. *Hypertensive crises* and rapid *volume overload* (intravascular intravenous fluid infusion or blood transfusion) can also cause CS in severe VHD but can generally be treated medically.

d. *Takotsubo syndrome* has been associated with pulmonary oedema in AS²³. Moreover, dynamic LV outflow tract obstruction, typical of apical ballooning, may create severe MR through systolic anterior motion of the anterior mitral leaflet, which may result in CS²⁴. As with AMI, medical treatment is challenging and may aggravate haemodynamic impairment and CS in AS. Conversely, cautious use of beta blockers (ideally starting with intravenous, short-acting beta blockers like esmolol) with fluid resuscitation reduces LV outflow tract obstruction by decreasing basal hypercontractility, increasing LV filling and size, and reducing the heart rate, all potentially leading to MR reduction and haemodynamic stabilisation²⁵.

NON-CARDIOVASCULAR TRIGGERS

a. *Pregnancy* carries a high risk of cardiac decompensation in VHD due to pregnancy-related haemodynamic changes. Stenotic VHD, particularly MS, are generally less tolerated during pregnancy

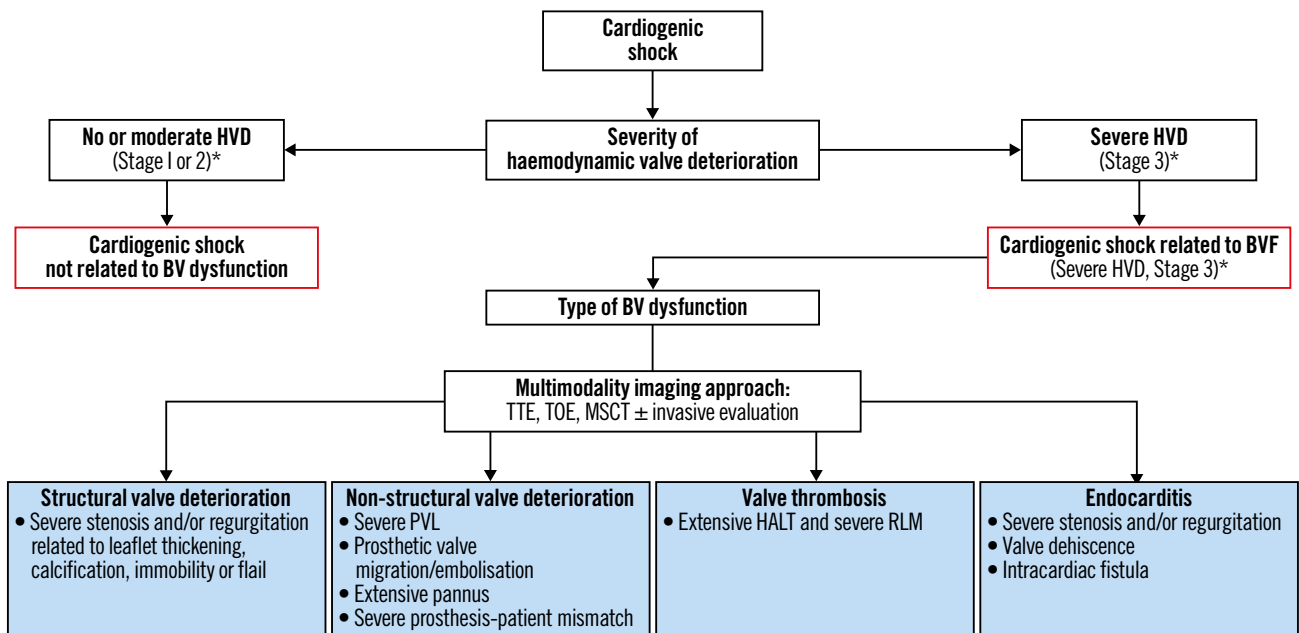


Figure 1. Identification of BVF mechanisms associated with cardiogenic shock. *for HVD severity definition. *Stage 1 HVD definition: evidence of SVD, non-structural valve dysfunction (other than paravalvular regurgitation or prosthesis-patient mismatch), thrombosis, or endocarditis without significant haemodynamic changes. *Stage 2 HVD definition: increase in mean transvalvular gradient ≥ 10 mmHg resulting in a mean gradient ≥ 20 mmHg with a concomitant decrease in EOA ≥ 0.3 cm² or $\geq 25\%$ and/or decrease in Doppler velocity index ≥ 0.1 or $\geq 20\%$ compared with echocardiographic assessment performed 1-3 months post-procedure, OR new occurrence or increase of ≥ 1 grade of intraprosthesis AR resulting in \geq moderate AR. *Stage 3 HVD definition: increase in mean transvalvular gradient ≥ 20 mmHg resulting in a mean gradient ≥ 30 mmHg with a concomitant decrease in EOA ≥ 0.6 cm² or $\geq 50\%$ and/or decrease in Doppler velocity index ≥ 0.2 or $\geq 40\%$ compared with echocardiographic assessment performed 1-3 months post-procedure, OR new occurrence or increase of ≥ 2 grades of intraprosthesis AR resulting in severe AR²⁰. AR: aortic regurgitation; BV: bioprosthetic valve; BVF: bioprosthetic valve failure; EOA: effective orifice area; HALT: hypoattenuated leaflet thickening; HVD: haemodynamic valve deterioration; MSCT: multislice computed tomography; PVL: paravalvular leak; RLM: reduced leaflet motion; TOE: transoesophageal echocardiography; TTE: transthoracic echocardiography

than regurgitant lesions, as increased heart rate, stroke volume and CO increase the transvalvular gradient by approximately 50%, mainly between the first and second trimesters, worsening both the patient's and foetus' prognoses²⁶⁻³⁰. Accordingly, MS should be treated preconceptionally when diagnosed. Otherwise, transcatheter valve interventions provide a minimally invasive option for an acutely decompensated condition that is not responsive to medical treatment³¹.

b. *Severe infection/sepsis* can lead to decreased systemic vascular resistance and hypovolaemia, causing a compensatory increase in heart rate and hypotension despite increased CO, which are poorly tolerated in severe MS or AS patients. Besides, a decreased preload increases valvular gradients, aggravating pre-existing stenosis. Cardiovascular comorbidities are risk factors for septic shock³², while infection is the main cause of non-cardiac deaths (up to 31%) in AS patients³³⁻³⁵.

In most patients with septic non-CS, VHD is a bystander and does not require specific urgent intervention. However, a valvular intervention might be advisable for selected patients when standard medical therapy fails or when weaning and recovery seem challenging. Emergency percutaneous mitral balloon valvuloplasty (PMBV) has been effective in this context³⁶. Balloon valvuloplasty avoids prosthetic valve implantation in infected patients at risk of endocarditis. However, it carries an acute MR or AR risk. Weighing the risk-benefit ratio is challenging, and the decision should be tailored to the patient's condition.

a. *Other precipitating factors* include severe anaemia, acute renal failure, hyperthyroidism and hypoalbuminaemia, all usually improving after treatment and not requiring emergent valve intervention.

Emergent diagnostic workup

NON-INVASIVE DIAGNOSTIC TOOLS

TRANSTHORACIC ECHOCARDIOGRAPHY

Transthoracic echocardiography (TTE) is the optimal imaging modality in CS³⁷, determining the cause and severity of underlying VHD and whether or not it is responsible, at least partially, for the clinical presentation of the patient. Limited point-of-care cardiac ultrasound focusing on two-dimensional assessment of the LV function, such as left ventricular ejection fraction (LVEF), may miss important VHD lesions³⁸. Discrimination of the severity of VHD using TTE requires high image quality, precise measurement, complex calculations, and integration of multiple criteria. Moreover, the low-flow status of CS should be accounted for, as it might underestimate transvalvular gradients. Conversely, medications used in CS, such as dobutamine, might increase transvalvular gradients, therefore, overestimating the VHD. We herein propose a diagnostic workflow for the assessment of patients presenting with CS. (**Figure 2, Table 1**).

TRANSOESOPHAGEAL ECHOCARDIOGRAPHY

Transoesophageal echocardiography (TOE) may increase diagnostic accuracy, especially in case of a poor acoustic TTE window, and is relatively straightforward to perform in patients under

mechanical ventilation. TOE may be able to identify BVF aetiology, differentiate PVL from valvular regurgitation, and help in suspected endocarditis. It is mandatory for transcatheter mitral valve therapies to evaluate eligibility and guide interventions. It may be used for aortic valve sizing if a computed tomography (CT) scan is not available (**Table 1**).

MULTISLICE COMPUTED TOMOGRAPHY

Multislice CT (MSCT) is complementary to TTE. Calcium scoring using non-contrast MSCT can confirm AS severity (likely severe if >2,000 Agatston units [AU] in men and >1,200 AU in women) in discordant AS grading (aortic valve area <1 cm² and mean gradient <40 mmHg) related to low CO. MSCT with contrast injection is the gold standard for feasibility studies and planning of valvular interventions, such as transcatheter aortic valve implantation (TAVI). MSCT acquisition protocol should include a contrast-enhanced electrocardiogram (ECG)-gated or triggered heart and aortic root scan and a non-ECG-gated vascular bed scan from the subclavian arteries to superficial femoral arteries, reconstructed at a slice thickness of 1.0 mm or less for accurate multiplanar evaluations (at least 64-detector technology).

High spatial resolution of MSCT by multiplanar and three-dimensional volume reconstructions provides an accurate analysis of valve morphology (tricuspid vs bicuspid, calcium distribution), the aortic root anatomy, vascular access route, and coronary arteries, the latter being challenging in CS due to tachycardia and low CO. Contrast-enhanced MSCT is also useful in BVF to discriminate SVD, thrombosis, pannus, and infective endocarditis and in planning valve-in-valve procedures (**Table 1**).

INVASIVE DIAGNOSTIC TOOLS

INVASIVE CORONARY ANGIOGRAPHY

Coronary artery disease (CAD) is diagnosed in 20-80% of symptomatic severe AS patients, according to age group, and increases operative risk³⁹. In addition, among patients with CS undergoing TAVI, 10% and 20% present with significant left main CAD and proximal left anterior descending artery stenosis, respectively⁴⁰. The coexistence of CAD and secondary MR is much more frequent; more than two-thirds of patients undergoing transcatheter edge-to-edge repair (TEER) have relevant CAD⁴¹. Therefore, invasive coronary angiography (ICA) is mandatory to rule out CAD. The objectives of ICA are to 1) identify treatable CAD that is aggravating the CS; 2) perform myocardial revascularisation when needed; and 3) obtain safe and adequate arterial access for percutaneous mechanical circulatory support (MCS). Except for CS in AMI patients, there is a lack of robust scientific evidence about the optimal therapeutic strategy for patients with coexisting CAD requiring revascularisation and significant VHD. For this reason, the time sequence of events – placement of MCS, revascularisation and emergency balloon valvuloplasty/TAVI or TEER – depends on team experience, patient clinical status and VHD (**Table 1**).

INVASIVE RIGHT HEART CATHETERISATION

Alongside diagnosing pulmonary hypertension, right heart catheterisation was previously broadly used for haemodynamic monitoring and treatment adjustment. However, several registries reported considerable

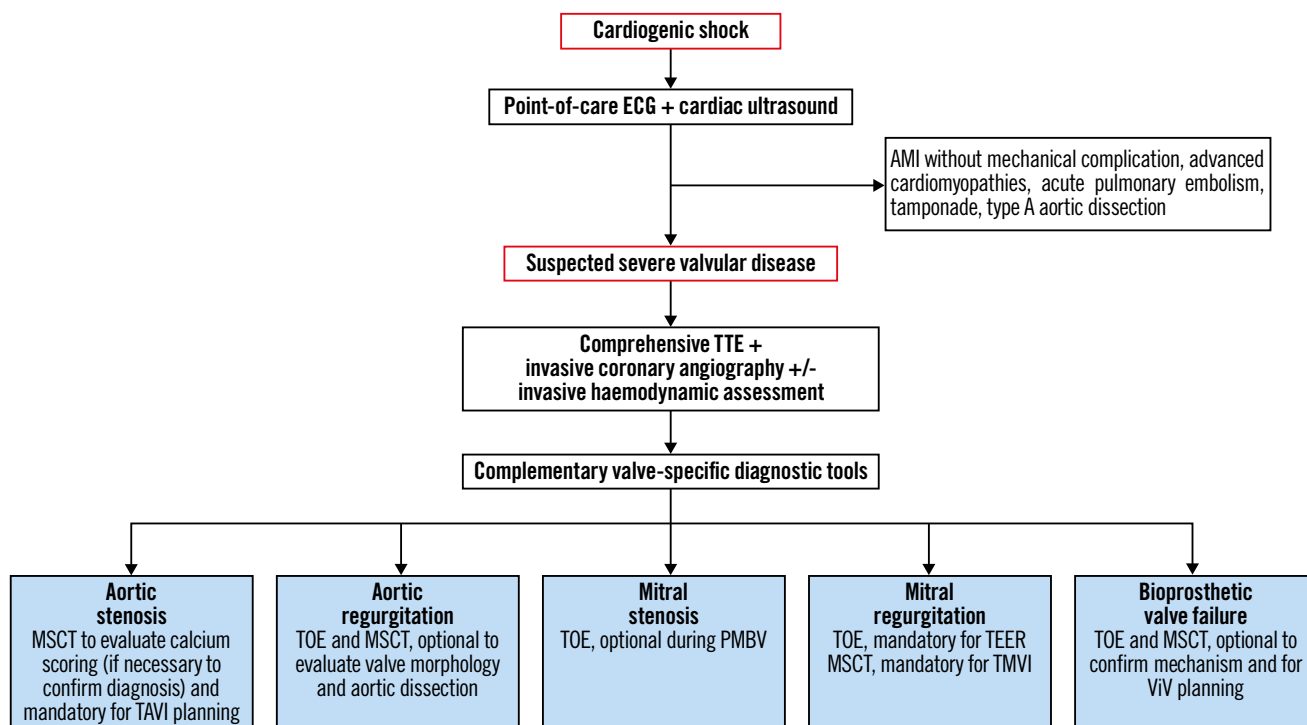


Figure 2. Proposed diagnostic workflow for the assessment of patients presenting with CS. *Step 1. Point-of-care cardiac ultrasound.* A point-of-care cardiac ultrasound is generally useful as it provides the first clues of severe VHD¹⁴⁶. However, it is rarely sufficient. In this phase, ruling out acute myocardial ischaemia, advanced cardiomyopathies, untolerated arrhythmias, acute pulmonary embolism, tamponade or type A acute aortic dissection potentially responsible for the CS, is crucial¹⁴⁷. When a point-of-care cardiac ultrasound reveals hyperdynamic LV function in a patient with severe acute decompensated heart failure or CS, urgent assessment with comprehensive transthoracic echocardiography (TTE) is warranted to exclude VHD emergencies. *Step 2. Comprehensive TTE.* Comprehensive TTE is generally adequate to accurately investigate valve structure and function. Importantly, increased flow due to sepsis or anaemia can elevate Doppler gradients, potentially leading to overestimation of the severity of stenotic valve lesions. Likewise, volume overload and systemic hypertension often lead to reversible worsening of regurgitant lesion severity. Conversely, low-flow status might underestimate the severity of valvular diseases. Invasive coronary angiography±invasive haemodynamic assessment can give additional information in this step. At this step, an invasive coronary angiography is indicated to rule out concomitant CAD according to guideline criteria⁹. Alternatively, owing to its high negative predictive value, MSCT may be used in patients who are at low risk of atherosclerosis. *Step 3. Complementary valve-specific diagnostic tools* include TOE and/or multislice computed tomography. Accurate quantification of VHD severity is essential, as only severe valvular dysfunction can cause CS¹⁴⁸. Hence, TOE, including three-dimensional modalities, is useful in the detailed assessment of valve anatomy and function (native or prosthetic)¹⁴⁹ and should be systematically performed when TTE is inconclusive. In stabilised patients, MSCT should be performed if required for the planification of the transcatheter heart valve intervention. AMI: acute myocardial infarction; CAD: coronary artery disease; CS: cardiogenic shock; ECG: electrocardiogram; LV: left ventricular; MSCT: multislice computed tomography; PMBV: percutaneous mitral balloon valvuloplasty; TAVI: transcatheter aortic valve implantation; TEER: transcatheter edge-to-edge repair; TMVI: transcatheter mitral valve implantation; TOE: transoesophageal echocardiography; VHD: valvular heart disease; ViV: valve-in-valve

complications related to its routine use for treatment monitoring, and, despite conflicting registry evidence^{42,43}, the only RCT demonstrated no additional benefit compared to TTE^{44,45}. Therefore, right heart catheterisation is not recommended for daily monitoring. It can be useful, alone or in combination with left heart catheterisation for decision-making or, in selected cases, during the peri-interventional phase, in experienced hands (**Table 1**). Moreover, selective use of right heart catheterisation can be considered to guide medical decisions in CS, particularly in patients considered for or supported by MCS^{46,47}.

Therapeutic strategies: general concepts

Both the 2021 ESC/EACTS Guidelines for the management of VHD⁹ and the 2021 ESC Guidelines for diagnosis and treatment

of acute and chronic HF¹¹ contain few recommendations on VHD management in CS patients. CS is time-sensitive with rapidly increasing mortality, for which diagnosis and management should start as early as possible. Early identification and treatment of the underlying cause, along with haemodynamic stabilisation and management of organ dysfunction, are key.

MEDICAL TREATMENT AND ANCILLARY PROCEDURES

After initial fluid challenge (if appropriate), pharmacological management of CS consists of intravenous (I.V.) vasoactive agents to improve organ perfusion by increasing CO and blood pressure^{11,48}. The selection of pharmacological agents is largely empirical, and they must be used with caution, starting at low doses

Table 1. Checklist for VHD imaging assessment and eligibility for transcatheter procedures.

		FOR DIAGNOSIS	FOR ELIGIBILITY FOR TRANSCATHETER PROCEDURES
AV disease	TTE	Confirm AV disease severity Evaluate valve morphology Check for associated VHD, LV/RV function, PASP	
	TOE	Confirm diagnosis (optional)	Confirm annular sizing (3D evaluation, only if MSCT not available)
	MSCT	Confirm VHD severity (calcium score) in LFLG AS Rule out CAD in selected cases	Confirm annular sizing Evaluate valve morphology and calcium distribution General aortic root assessment (sinus of Valsalva and STJ dimensions, coronary ostia height) Evaluate aorta and vascular access
	ICA	Rule out CAD	
	L-RHC	Confirm disease severity in selected cases	
MV disease	TTE	Confirm MV disease severity Evaluate valve morphology and mechanism of VHD Check for associated VHD, LV/RV function, PASP	
	TOE	Confirm diagnosis in selected cases	Evaluate valve morphology and mechanism of MR for TEER and TMVI Rule out LAA and LA clots
	MSCT	Rule out CAD in selected cases	Evaluate annulus size for TMVI eligibility Predict LVOT obstruction for TMVI eligibility
	ICA	Rule out CAD	
	L-RHC	Confirm disease severity in selected cases	
BVF	TTE	Confirm BVF severity Evaluate valve morphology and mechanism of failure Check for associated VHD, LV/RV function, PASP	
	TOE	Confirm mechanism of bioprosthetic valve dysfunction (SVD, non-SVD, thrombosis, endocarditis) Discriminate between PVL and intravalvular AR	Rule out LAA and LA clots in case of planned valve-in-valve in mitral position Identify PVL location to select the most appropriate vascular access for transcatheter occlusion
	MSCT	Confirm mechanism of bioprosthetic valve dysfunction (SVD, non-SVD, thrombosis, endocarditis) Rule out CAD in selected cases	Confirm valve size Identify PVL location to select the most appropriate vascular access for transcatheter occlusion Evaluate vascular access + IN AORTIC POSITION: General aortic root assessment (sinus of Valsalva and STJ dimension, coronary ostia height) Check for interference with coronary ostia Evaluate aorta and vascular access + IN MITRAL POSITION: Predict LVOT obstruction
	ICA	Rule out CAD	
	L-RHC	Confirm disease severity in selected cases	

3D: three-dimensional; AR: aortic regurgitation; AS: aortic stenosis; AV: aortic valve; BVF: bioprosthetic valve failure; CAD: coronary artery disease; ICA: invasive coronary angiography; LA: left atrial; LAA: left atrial appendage; LFLG: low-flow low-gradient; L-RHC: left-right heart catheterisation; LV: left ventricular; LVOT: left ventricular outflow tract; MSCT: multislice computed tomography; MV: mitral valve; PASP: pulmonary artery systolic pressure; PVL: paravalvular leak; RV: right ventricular; STJ: sinotubular junction; SVD: structural valve deterioration; TOE: transoesophageal echocardiography; TEER: transcatheter edge-to-edge repair; TMVI: transcatheter mitral valve implantation; TTE: transthoracic echocardiography; VHD: valvular heart disease

and up-titrating with close monitoring^{19,48,49}. Norepinephrine is the vasopressor of choice, despite a potentially harmful increase in stroke volume and transvalvular gradient in cases of AS and an increase in LV afterload¹¹. Accordingly, medical stabilisation is often difficult in the presence of VHD, and a rapid escalation to other strategies (mechanical support and/or intervention) is strongly advisable.

Triggering factors must be recognised and treated immediately. In cases of acute coronary syndrome, urgent revascularisation is required regardless of VHD. Nishino et al showed that a shorter symptom onset-to-reperfusion time was an independent predictor

of early MR improvement in AMI patients⁵⁰. Out of 51 patients from the TAVI-shock registry, 33% had CAD, but only 1 (2%) presented with AMI⁵¹.

Other causative factors include valve thrombosis, especially within 12 months of prosthetic valve implantation, when it is the most common cause of valve dysfunction^{52,53}. Anticoagulation using vitamin K antagonists and/or unfractionated heparin is the first-line treatment of biological valve thrombosis. Fibrinolysis is an option (streptokinase was the most commonly used fibrinolytic agent, followed by tissue plasminogen activator and urokinase – all at standard recommended doses) in obstructive,

especially mechanical, valve thrombosis⁵⁴. However, considering the risks of bleeding, systemic embolism and recurrent thrombosis, emergency surgical valve replacement is recommended over fibrinolysis if immediately available and not contraindicated⁹.

MECHANICAL CIRCULATORY SUPPORT DEVICES

Evidence regarding outcomes of MCS in CS patients with VHD remains scarce, deriving mainly from small case series or registries^{51,55-59}, and there are no published guidelines for short-term MCS in this setting. Hence, unselected use of MCS is not supported and requires multidisciplinary expertise for device selection, implantation, and management. In persistent severe haemodynamic deterioration and CS despite medical support and removal of the triggering factor, early MCS could increase CO and end-organ perfusion as a bridge-to-recovery, bridge-to-destination or bridge-to-bridge^{11,19,46}. Different temporary MCS are currently available, including intra-aortic balloon pump (IABP), venoarterial extracorporeal membrane oxygenation (VA-ECMO), the Impella (Abiomed), the TandemHeart percutaneous system (LivaNova) and implantable LVAD. Device selection requires an in-depth understanding of anatomy, physiology, and the pathology of VHD^{19,46,47}.

In severe AS, most MCS options may be used⁴⁷. VA-ECMO may increase LV afterload and, in some cases, concomitant LV unloading is mandatory, requiring unloading devices such as a microaxial flow pump device, if not contraindicated, or through atrial septostomy.

In MS, where LV end-diastolic pressure is generally low, the optimal device would be the TandemHeart (with direct left atrial [LA] drainage). However, especially in RV failure and hypoxaemia, VA-ECMO would be best, with the preferred use of the LA VA-ECMO modality.

In patients with CS due to AMI with papillary muscle rupture and acute MR, IABP may be considered, according to ESC Guidelines^{11,60}, to decrease afterload, to support adequate mean arterial pressure and to potentially decrease MR, despite minimal CO augmentation. ECMO can better support CO but is less commonly used alone, since it may increase the total peripheral vascular resistance, potentially worsening MR. More frequently, in MR physicians should consider the LA VA-ECMO modality to unload the LA or the Impella device, alone or with ECMO (i.e., ECPella), to directly unload the LV (caution is needed in papillary muscle rupture-related MR)^{19,46,61}.

Given AR pathophysiology, most (if not all) MCS are relatively contraindicated, especially in the presence of concomitant aortic dissection⁴⁷. In fact, elevated diastolic blood pressure during IABP inflation and increased afterload due to VA-ECMO may both increase AR and contribute to LV distention. Similarly, the use of continuous flow implantable LVAD, and Impella (precluding aortic valve coaptation) may worsen AR and recirculation, reducing the device's forward flow. If MCS is absolutely necessary in severe AR, TandemHeart or LA VA-ECMO could

be considered because of their capacity for concomitant LA unloading^{19,46,47}.

MCS including ECMO, IABP, Impella and TandemHeart have also been used in high-risk transcatheter valve procedures during CS⁶²⁻⁶⁴. This use varies widely depending on institutional practice and expertise, but it was demonstrated that a "standardised team-based approach" with predefined algorithms for early MCS implant and close monitoring of clinical signs, invasive haemodynamics and biochemical markers may translate into improved survival⁶⁵⁻⁶⁷.

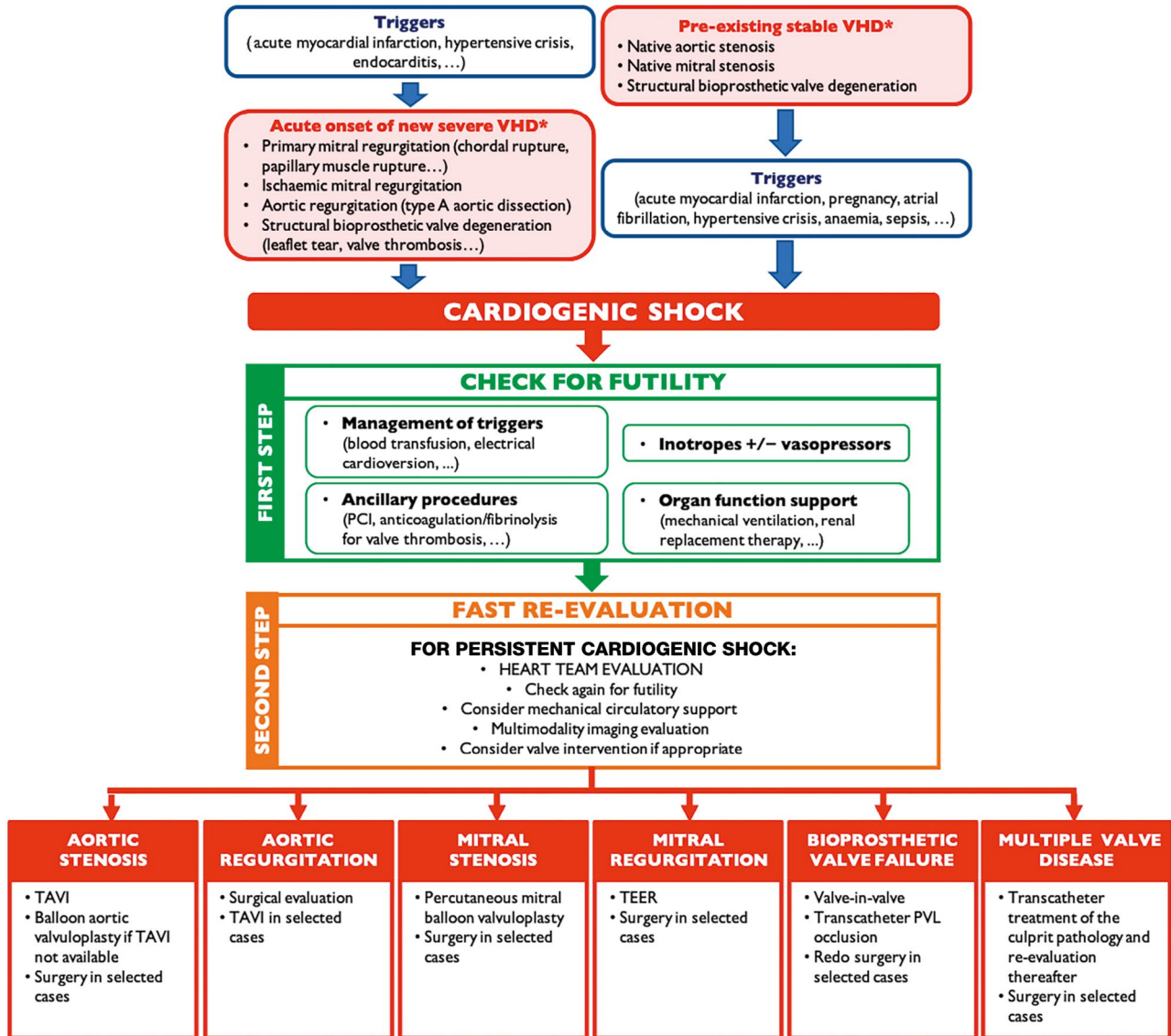
VALVULAR INTERVENTION

On top of pharmacological and organ-specific support, valvular intervention can be considered when VHD is the primary cause or an aggravating factor in CS (**Central illustration**). Significant VHD is associated with increased in-hospital mortality in CS patients⁶⁸, and early treatment is advocated because delay between CS onset and valvular intervention predicted poor outcomes in patients with AS and CS^{40,69}. Interestingly, in the IREMMI Registry, the time between shock onset and TEER for acute MR was around 30 days⁷⁰. Prior to TEER, 66% of patients were stabilised with IABP or Impella and 12% with VA-ECMO. However, the authors advocated for early MR correction irrespective of the LVEF and development of CS⁷⁰.

The Heart Team must decide the indication, timing and mode of intervention (surgical versus transcatheter) after taking into account the patient's clinical status and risk profile, anatomical considerations (i.e., type of VHD, presence of combined VHD, aortic disease or CAD), the role of VHD in the CS, as well as institutional expertise and the patient's values and preferences. Contraindications for intervention in patients with CS, include the following:

1. Severe frailty, limited life expectancy (<12 months), or refusal of life-saving treatment;
2. Non-severe VHD;
3. End-stage CS with severe end organ failure (the "point of no return" was crossed);
4. CS complicated by resuscitated cardiac arrest with unfortunate neurological outcome;
5. Possibility and indication for urgent heart transplantation with or without previous MCS as a bridge therapy (i.e., end-stage HF patients with functional MR).

Some of these contraindications are relative and dynamic; hence, patients should be closely monitored and the decision adjusted according to the patient's clinical status. Regarding the mode of intervention (surgical vs transcatheter), very few data are available to support either choice. Urgent/emergent cardiac surgery in VHD and CS is associated with high morbidity and mortality risks⁷¹⁻⁷³, and a less invasive approach with at least equal results might be preferable. This can be more intuitive with TAVI but is less evident with other transcatheter valve interventions. RCTs are needed to confirm this hypothesis, but they are hard to carry out in this setting. Regardless of the strategy, acute

CENTRAL ILLUSTRATION Diagnostic and therapeutic algorithm in cardiogenic shock and valvular heart disease.

Diagnostic and therapeutic algorithm leading to valve intervention when valvular heart disease is either the primary cause or an aggravating factor in cardiogenic shock. *The mentioned valve disorders are the most common examples. PCI: percutaneous coronary intervention; PVL: paravalvular leak; TAVI: transcatheter aortic valve implantation; TEER: transcatheter edge-to-edge repair; VHD: valvular heart disease

correction of VHD in CS patients can potentially reverse the fatal process, allowing for recovery and improving long-term patient outcomes. Emergent or urgent surgical treatment of VHD complicated by CS is advisable as a first-line therapy (particularly in young patients and those with low comorbidity) or as the only therapeutic option in certain settings (i.e., active endocarditis or acute AR associated to type A aortic dissection) if surgical risk allows it. A benefit of early surgery in infective endocarditis is uncertain because of a high recurrence rate, and its timing must be carefully selected. Therefore, surgery in the acute setting is

restricted to specific clinical situations (HF, uncontrolled infection and prevention of embolic events) and eligible patients⁷⁴. In other cases, and in the absence of haemodynamic refractory instability, surgery is postponed to allow 1 or 2 weeks of antibiotic treatment under careful clinical and echocardiographic observation^{74,75}.

Few surgical reports indicate that immediate surgical aortic valve replacement is feasible in critically ill and decompensated patients with AS, with an in-hospital mortality of 25-30%⁷⁶⁻⁷⁸. In MR patients with CS, primary and secondary MR should be distinguished. In MR caused by AMI, the standard of care is acute

surgical revascularisation with simultaneous mitral valve repair or replacement, despite the high risk in patients with CS (early mortality up to 20-30%)⁷⁹. Perioperative short-term MCS may be beneficial. In acute ischaemic MR, only papillary muscle and chordal ruptures usually need immediate intervention. Accordingly, of ~8% of patients with CS due to severe MR complicating AMI in the SHOCK Trial Registry, only 46% underwent mitral valve surgery⁸⁰. Surgery of papillary muscle rupture carries a higher mortality rate compared to regular mitral surgery owing to the acute setting⁸⁰. As rapid deterioration after papillary muscle rupture is unpredictable, early intervention is mandatory, even though intravenous diuretic and vasodilator/inotropic support may initially stabilise patients⁸¹.

Emergency transcatheter valve treatments across different structural VHD complicated by CS are described below, in dedicated sections.

In general, specific contraindications for transcatheter intervention include the following:

1. Unfavourable valve or vascular anatomy;
2. Percutaneous intervention not achievable (i.e., intrachamber thrombus, valvular thrombosis, mitral valve anatomy not suitable for TEER – same contraindications as in stable patients);
3. Active endocarditis (for transcatheter implantation of devices and valvular replacement);
4. Feasible and potentially more beneficial valvular surgery despite increased surgical risk according to Heart Team consensus.

Urgent/emergent transcatheter valve treatments across different VHD

NATIVE AS AND CS

TAVI has a class I indication in symptomatic severe AS patients at high or prohibitive surgical risk⁹. CS represents a high-risk surgical condition, but RCTs of TAVI in this setting are not available, as CS was an exclusion criterion in most RCTs evaluating therapies targeting both AS and HF. Therefore, current guidelines still recommend balloon aortic valvuloplasty (BAV) in AS with decompensated HF and/or CS for stabilisation as a bridge to TAVI or surgical aortic valve replacement (Class IIb, Level of Evidence C)⁹. However, despite the initial success of urgent BAV, early mortality of these patients remains high (up to 71%)⁸²⁻⁹¹. Recently, urgent/emergent TAVI has been suggested as an alternative when available^{40,49,69,88,92,93} (**Table 2**). Theoretical advantages of TAVI over BAV in this setting may be better and could offer sustained haemodynamic improvement with complete relief of afterload mismatch and low residual AR risk, potentially translating into better outcomes and lower rates of early readmission⁹⁴. Notwithstanding, TAVI may be more challenging because of larger vascular access, higher risk of vascular complications and the inconstant availability and feasibility of preprocedural MSCT⁸⁸. Moreover, urgent TAVI is not feasible in all hospitals, and a transfer might be needed. Finally, even in hospitals with TAVI availability, urgent TAVI may not be rapidly feasible for logistical reasons (**Table 3**).

Masha et al reported the largest TAVI series in CS (4.1% of the US TAVI population)⁴⁰, comparing 2,220 emergent TAVI for CS to 12,851 high-risk patients without CS (median Society of Thoracic Surgeons [STS] score 10.2) included in the STS/American College of Cardiology (ACC) Transcatheter Valve Therapy (TVT) registry between 2014 and 2017. Despite similar optimal gradient relief, the CS population had higher complication rates and 30-day mortality (19.1% in patients with CS vs 4.9% in those without CS), primarily driven by preprocedural shock severity rather than procedural complications. The impact of CS duration prior to treatment is well known, and available evidence suggests that AS should be promptly corrected (BAV or TAVI) – ideally within 48 hours from CS onset, as >48 hours delay was linked to worse prognosis^{85,88,89}. However, the ideal time window and accurate criteria for intervention remain unknown. Given the procedural risks, it should be undertaken after Heart Team discussions in experienced centres. Decision-making should consider feasibility, efficacy and utility of emergent TAVI over other treatments, including medical management, BAV, durable LVADs, and palliative care (**Figure 3**). There is no uniform definition of futility; however, in TAVI, it can be described as death and/or an absence of functional improvement 6 to 12 months post-procedure⁹⁵.

Considerable knowledge gaps also exist regarding specific technical considerations, such as 1) timing of the coronary revascularisation of concomitant CAD; 2) valve choice; and 3) usefulness of intraprocedural MCS (i.e., “protected TAVI”)^{96,97}. Regarding valve choice, there is no RCT to support this and interventionalists should rather use the device they are most familiar with. Furthermore, devices anticipating the best outcomes with least haemodynamic compromise during deployment should be preferred.

BICUSPID AORTIC VALVE DISEASE

In the specific and not uncommon setting of bicuspid severe AS, especially in youth, cardiac surgery should be considered. BAV can be undertaken in non-calcified valves with minimal AR (for example, during pregnancy), as a bridge to surgery. In older patients with calcified valves, TAVI remains an option, provided accurate valve evaluation, sizing and preprocedural planning by MSCT have been carried out.

NATIVE AR AND CS

Given the high surgical risk, TAVI may be an alternative for pure (non-calcified) AR⁹⁸⁻¹⁰⁴ also in CS, as reported in case reports or small series (**Table 4**)¹⁰⁵⁻¹⁰⁸. It is generally contraindicated in endocarditis and aortic dissection. The Endo-Bentall procedure for transcatheter treatment of acute aortic dissection complicated by acute AR is promising¹⁰⁹. Concerning AR in LVAD patients, casuistics and meta-analyses demonstrate the challenges and potentials of transcatheter treatment^{107,110}.

There is currently only one European conformity (CE)-marked device for pure AR⁹⁸. The procedural challenges with TAVI in pure AR include 1) lack of calcification for annulus visualisation and valve anchoring; and 2) large annular size exceeding

Table 2. Summary of registries on BAV and TAVI in CS.

Author	Setting	Population	Age, years	LVEF, %	30-day mortality, %
BAV in patients with CS					
NHLBI, 1991 ⁸²	Multicentre	39 BAV	-	-	51.0
Cribier et al, 1992 ⁸³	Single centre	10 BAV	64±9 (54-79)	25±6	20.0
Moreno et al, 1994 ⁸⁴	Single centre	21 BAV	74±3 (35-90)	29±3	43.0 (in-hospital)
Buchwald et al, 2001 ⁸⁵	Single centre	14 BAV	74±11 (50-91)	-	71.0
Saia et al, 2013 ⁸⁶	Single centre	23 BAV	70±13	40±15	56.5
Theiss et al, 2014 ⁸⁷	Single centre	13 BAV	79±2	33±3	38.5
Bongiovanni et al, 2017 ⁸⁸	Multicentre	118 BAV	81±8	-	33.0
Debry et al, 2018 ⁸⁹	Multicentre	44 BAV	77±8	30±14	47.0
Eugène et al, 2018 ⁹⁰	Single centre	17 BAV	79±9	27±11	48.0
Varela et al, 2019 ⁹¹	Single centre	14 BAV	76±7	-	21.4
TAVI in patients with CS					
D'Ancona et al, 2012 ⁹²	Single centre	21 TAVI TA	75±11	26±13	19.0
Frerker et al, 2016 ⁶⁹	Single centre	27 TAVI	78±9	40±15	33.3
Bongiovanni et al, 2017 ⁸⁸	Multicentre	23 TAVI	76±11	-	23.8
Fraccaro et al, 2019 ⁵¹	Multicentre	51 TAVI	76±13 (31-93)	43±15	11.8
Huang et al, 2019 ⁹³	Single centre	31 emergent TAVI (26/31 in CS)	73±14	32±15	19.4
Masha et al, 2020 ⁴⁰	Multicentre	2,220 TAVI	83 (median)	53 (median)	19.1
Steffen et al, 2022 ¹⁵⁰	Single centre	47 TAVI	-	-	42.6 (at 90 days)

Data are n, mean±standard deviation, mean±standard deviation (range) or %, unless indicated otherwise. BAV: balloon aortic valvuloplasty; CS: cardiogenic shock; LVEF: left ventricular ejection fraction; TA: transapical; TAVI: transcatheter aortic valve implantation

Table 3. Pros and cons of BAV and TAVI in CS.

	BAV	TAVI
Residual transvalvular gradient	↑↑	↓↓
Risk of significant postprocedural AR	↑↑	↓
Insertion profile	↓	↑
Availability	↑↑	↑↓*
Feasibility	↑↑	↑↓**
Costs	↓↓	↑↑

*potential need for transfer; **need for emergent CT scan AR: aortic regurgitation; BAV: balloon aortic valvuloplasty; CS: cardiogenic shock; CT: computed tomography; TAVI: transcatheter aortic valve implantation

the manufacturer's recommendations for available transcatheter heart valve sizes. Future device iterations may overcome these limitations.

NATIVE MS AND CS

Percutaneous mitral balloon valvuloplasty (PMBV) in rheumatic MS has revolutionised the treatment of rheumatic MS since its introduction in 1984^{111,112}. It is recommended for severe symptomatic MS without unfavourable anatomical characteristics for mitral commissurotomy, according to the 2021 ESC/EACTS Guidelines for the management of VHD⁹.

This is particularly appealing in CS, as the procedure is less invasive than surgery and can be performed quickly, on an

emergency basis, and under local anaesthesia. Several case reports have described its use in this setting¹¹³⁻¹¹⁶. In patients who are not good candidates for PMBV, transcatheter mitral valve implantation (TMVI) could offer a minimally invasive alternative, even though most techniques are much more challenging, require general anaesthesia and thorough preprocedural planning. Besides, widespread availability and longer-term follow-up is lacking.

In the specific case of pregnant women with severe HF, use of PMBV has been described with substantial improvement in clinical outcomes and acceptable safety¹¹⁷. Its yield in CS has been described in a case report¹¹⁸. Radiation exposure during PMBV carries a foetal risk, especially during organogenesis. Every effort should be made to postpone the procedure to the second trimester, after the fourth month, when organogenesis is complete and the thyroid is still inactive¹¹⁹. However, when CS occurs, postponing the procedure may not be possible. In this case, radiation doses should be kept as low as reasonably achievable, and dedicated protocols are warranted to minimise foetal radiation and iodine-based contrast medium because of the risk of neonatal hypothyroidism (**Supplementary Table 2**).

NATIVE MR AND CS

Postoperative outcome of emergency surgery (repair or replacement) for acute severe MR, regardless of aetiology, is poor with an overall 30-day mortality of 22.5%, even higher in AMI-related MR complicated by CS (up to 26.9%)¹²⁰. The role of

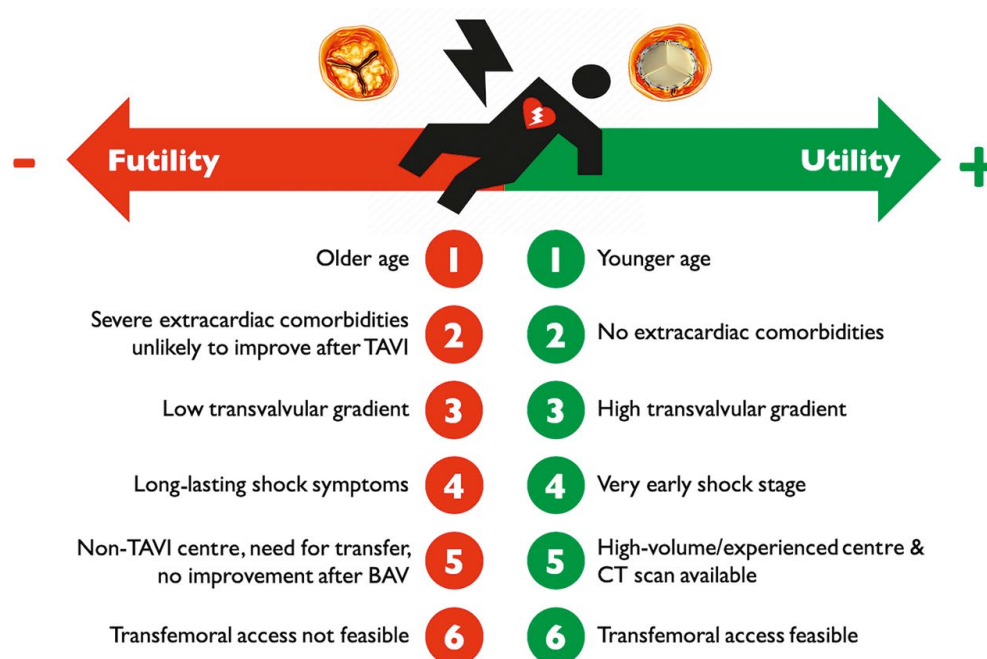


Figure 3. Factors influencing utility versus futility of emergent TAVI in case of patients with AS and CS. AS: aortic stenosis; BAV: balloon aortic valvuloplasty; CS: cardiogenic shock; CT: computed tomography; TAVI: transcatheter aortic valve implantation

Table 4. Summary of studies (single case reports) on emergent TAVI for the treatment of acute AR during CS.

Author	Setting	Treatment
Spina et al, 2019 ¹⁰⁵	Acute AR after iatrogenic surgical injury during complicated mitral valve surgery	Transfemoral TAVI (Medtronic Evolut R)
Herrmann et al, 2017 ¹⁰⁶	Acute AR after iatrogenic injury from Impella implantation	Transfemoral TAVI (Edwards Lifesciences SAPIEN 3)
Van der Werf et al, 2017 ¹⁰⁷	Acute AR in an LVAD patient	Transfemoral TAVI (Medtronic CoreValve)
Abdelaziz et al, 2018 ¹⁰⁸	Acute AR and aortic root dissection after previous supracoronary aortic replacement	Transapical TAVI (Edwards Lifesciences SAPIEN S3)

AR: aortic regurgitation; CS: cardiogenic shock; TAVI: transcatheter aortic valve implantation

transcatheter interventions in patients with MR and CS has not been fully demonstrated. There are no specific RCTs completed to date – the “Transcatheter Mitral Valve Repair for Inotrope Dependent Cardiogenic Shock (MINOS)” trial is ongoing (ClinicalTrials.gov: NCT05298124) – and patients in CS were excluded from landmark trials of transcatheter mitral valve repair¹²¹⁻¹²³. However, several case reports and recent observational studies described good results (**Table 5**)^{58,61,70,124-130}.

Available evidence concerns almost exclusively one TEER device; use of TMVI in this setting has not been reported. Of note, most data pertain to secondary, especially ischaemic, MR.

Comparison of studies is limited by differences in population, methods and outcome assessment. Still, available evidence suggests that the MitraClip (Abbott) is associated with high procedural success (72.7-100%), and acceptable short- and midterm outcomes (30-day or in-hospital mortality 0-27.3%, with a single-centre study reporting 30-day mortality of 60%; 6-month or follow-up mortality 16.7-63.0%)^{58,61,70,124-130}. In the largest study published to date, Jung et al pooled data from several observational studies and performed a patient-level analysis of 141 patients with CS and moderate to severe acute ischaemic MR; 78.7% of patients

required inotropes and about half were on MCS. Most had secondary MR (75.2%). Procedural success was high (88.7%), with a relatively low overall mortality (in-hospital mortality 15.6%, 90-day mortality 29.5%, and 1-year mortality 42.6%). Successful TEER was associated with a 74% relative reduction in both in-hospital and 90-day mortality¹²⁴. Tang et al compared the outcome of patients with CS and MR receiving the MitraClip during the index hospitalisation to those who did not, using propensity-matched data from the Centers for Medicare and Medicaid Services in the US. They showed increasing device use throughout the study and significantly lower in-hospital (24.8% vs 35.4%; odds ratio 0.6, 95% confidence interval [CI] 0.47-0.77; $p < 0.001$) and 1-year mortality (hazard ratio 0.76, 95% CI: 0.65-0.88; $p < 0.001$) in patients undergoing TEER. This benefit was consistent in all subgroups, except for patients requiring acute MCS or haemodialysis at the time of intervention¹³¹.

These preliminary results, even if encouraging, should be considered with caution. More robust data should be obtained, and the role of other techniques including TMVI must be assessed. In the meantime, TEER in patients with CS should be considered only in experienced hands and after careful feasibility evaluation.

Table 5. Observational studies of transcatheter mitral valve repair in patients with MR and CS*.

Author	Setting	n	Clinical scenario	Device	Mechanical circulatory support	Procedural success	Outcomes
Adamo, 2017 ¹²⁵	Single centre	4	Secondary MR: 100% (acute MR post-AMI 100%)	MitraClip	IABP: 100%	100%	30-day mortality: 0%
Seizer, 2017 ¹²⁶	Single centre	10	N/A	MitraClip	IABP: 30.0% ECMO: 70.0% Impella: 30.0%	90.0%	30-day mortality: 60.0%
Flint, 2019 ¹²⁷	Single centre	12	Primary MR: 33.3% Secondary MR: 16.7% Mixed MR: 50.0%	MitraClip	IABP: 33.3% ECMO: 8.3%	75.0%	30-day mortality: 16.7% Follow-up mortality (median 198 days): 41.7%
Chan, 2019 ¹²⁸	Single centre	27	Primary MR: 7.4% Secondary MR: 92.6% (ischaemic 92.0%)	MitraClip	IABP: 18.5%	92.6%	30-day mortality: 25.9% Follow-up mortality (mean 202 days): 63.0%
Cheng, 2019 ⁵⁸	Single centre	29	Secondary MR: 100% (non-ischaemic 65.5%, ischaemic 34.5%)	MitraClip	Impella: 17.2% IABP: 10.3%	96.6%	In-hospital mortality: 17.2% Survival to 6 months: 75.6±8.0%
Garcia, 2020 ¹²⁹	Single centre	11	Primary MR: 63.6% Secondary MR: 36.4%	MitraClip	IABP: 45.5%	72.7%	30-day mortality: 27.3% 1-year mortality: 66.7%
Jung, 2021 ¹²⁴	Multicentre	141	Primary MR: 23.4% Secondary MR: 75.2% Mixed MR: 1.4%	MitraClip	50.4%	88.7%	In-hospital mortality: 15.6% One-year mortality: 42.6%
Estévez-Loureiro, 2021 ⁷⁰	Multicentre	50	Secondary MR: 100% (acute MR post-AMI 100%)	MitraClip	IABP/Impella: 66.0% VA-ECMO: 12.0%	90.0%	30-day mortality: 10.0% Follow-up mortality (median 7 months): 28%
Vandenbriele, 2021 ⁶¹	2 centres	6	Primary MR: 50.0% Secondary MR: 50.0%	MitraClip	Impella: 100%	100%	In-hospital mortality: 16.7% 6-month mortality: 16.7%
Falascioni, 2021 ¹³⁰	Multicentre	31	Secondary MR: 100% (papillary muscle rupture 12.9%)	MitraClip	IABP: 58.1% Impella: 22.6% ECMO: 6.5%	87.1%	30-day mortality: 22.6% 6-month mortality: 38.7%

*Studies including exclusively patients with cardiogenic shock or studies also including patients without cardiogenic shock but in which data on patients with cardiogenic shock could be extracted from the manuscript. AMI: acute myocardial infarction; CS: cardiogenic shock; ECMO: extracorporeal membrane oxygenation; IABP: intra-aortic balloon pump; MR: mitral regurgitation; N/A: not available; VA: venoarterial

BVF AND CS

According to the EAPCI consensus¹³² and Valve Academic Research Consortium-3 definition²⁰, BVF is defined by 1) clinically expressive bioprosthetic valve dysfunction or irreversible severe HVD, 2) need for valve reintervention, and 3) valve-related death¹³²⁻¹³⁴.

Transcatheter treatment for Stage 3 HVD and CS depends on the underlying pathology and time from index procedure.

SHORT INTERVAL (<12 MONTHS)

Valve thrombosis is the most common cause of dysfunction^{52,53}. Its treatment was described earlier in this document. New valve regurgitation is related to valve migration, PVL, or endocarditis¹³⁵. Plug implantation is the gold standard for non-surgical patients with PVL¹³⁶⁻¹³⁸. A valve-in-valve procedure can restore valve function and haemodynamics in unstable patients with a migrated transcatheter or sutureless valves and in inoperable patients with subacute endocarditis^{139,140}.

LONG INTERVAL (>12 MONTHS)

The most common causes of BVF are degeneration and endocarditis, even if endocarditis decreases 1 year after valve implantation (approximately 1% per person-year vs 0.5% per person-year after 1 year)¹⁴¹. In case of valve-in-valve, characteristics of the bioprostheses should be taken into account (**Table 6**). In the context of

Table 6. Transcatheter treatment options in case of BVF.

	No/mild calcifications	Severe calcification
Stenosis	Valve-in-valve	Valve-in-valve (consider cerebral protection) ¹⁵¹
Regurgitation	Valve-in-valve Plug in case of severe PVL ¹³⁵⁻¹³⁷	Valve-in-valve (consider cerebral protection) ¹⁵¹

BVF: bioprosthetic valve failure; PVL: paravalvular leak

Table 7. Advanced techniques to overcome complex situations for valve-in-valve.

Complex situations for valve-in-valve	Advanced techniques
Small aortic bioprosthesis (label size ≤21 mm)	Bioprosthetic valve ring fracture
Risk of coronary obstruction	Coronary chimney stenting, endovascular electrosurgery leaflet splitting ¹⁴⁴
Risk of LV outflow tract obstruction in mitral valve-in-valve	Endovascular electrosurgery leaflet splitting ¹⁴⁵ , alcohol septal ablation

LV: left ventricle

CS, patients would require a fast and effective transcatheter procedure. However, some anatomical conditions, like a small internal diameter of a degenerated bioprosthesis and a high coronary obstruction risk, or outflow tract obstruction risks, will require sophisticated techniques to achieve an optimal procedural outcome^{142,143} (**Table 7**). Those situations will require general anaesthesia to allow TOE guidance and potentially MCS to stabilise haemodynamics during longer procedures.

Conclusions

CS is a clinical condition with extremely high morbidity and mortality, and concomitant severe VHD is associated with increased mortality⁶⁸. Acute onset of severe VHD may be the cause of CS, or triggering factors acting on pre-existing stable severe VHD can cause CS. In both situations, pharmacological support is the first-line therapy, including removal and treatment of triggering factors. However, if a patient's haemodynamic status is not quickly reverted, rapid escalation to other non-pharmacological treatment, particularly correction of concomitant VHD, may be required. The treatment decision should consider procedural utility and futility. Given the extremely high mortality risk, less invasive transcatheter valve interventions can be used as an alternative to surgery in several situations. Heart Teams must guide decision-making regarding indications, timing and mode of intervention, according to patients' clinical status and risk profile, anatomical considerations, VHD role, institutional expertise, and patients' values and preferences. As outlined above, to date, most evidence stems from case series and registries. The very high mortality risk warrants dedicated, well-designed and adequately powered RCTs to further elucidate the role of transcatheter valvular interventions and could, if positive, have significant public health implications. While CS RCTs are complicated by time pressures and patients' heterogeneity, clear inclusion criteria render such trials feasible and effective¹⁴⁴. We believe that in the meantime, all CS patients, if not eligible for ongoing RCTs, should be included in registries embedded in a network of networks or a hub-and-spoke registry, that will allow high-quality retrospective analyses in a large, worldwide dataset, and may assist in future registry-based RCTs¹⁴⁵.

Appendix. Authors' affiliations

1. Department of Cardiac, Thoracic, Vascular Sciences and Public Health, University of Padua, Padua, Italy; 2. Heart Valves Unit, Georges Pompidou European Hospital, Université Paris Cité, INSERM, Paris, France; 3. Department of Cardiology, St. Johannes Hospital, Dortmund, Germany; 4. Heart and Diabetes Center NRW, Bad Oeynhausen, Germany; 5. Cardiac Surgery, Medical University of Innsbruck, Innsbruck, Austria; 6. Hospital de Santa Cruz, Centro Hospitalar de Lisboa Ocidental (HSC), Carnaxide, Portugal and Comprehensive Health Research Center (CHRC), Nova Medical School, Lisbon, Portugal; 7. Cardiology Department, Santa Maria University Hospital, CHULN, CAML, CCUL, Faculty of Medicine, University of Lisbon, Lisbon, Portugal; 8. Interventional Cardiology Unit, San Raffaele Scientific Institute, Milan, Italy; 9. Department

of Cardiovascular Surgery, University Heart Centre, Freiburg University, Freiburg, Germany; 10. Faculty of Medicine, University of Freiburg, Freiburg, Germany; 11. Service de Cardiologie, CCP CHU de Rennes, University of Rennes, INSERM, LTSI-UMR 1099, Rennes, France; 12. Institute of Cardiology, Jagiellonian University Medical College, Krakow, Poland; 13. Clinique Pasteur, Toulouse, France; 14. Divisions of Cardiology and Cardiothoracic Surgery, Department of Advanced Biomedical Sciences, Federico II University, Naples, Italy; 15. Service of Cardiology, Lausanne University Hospital, Lausanne, Switzerland and University of Lausanne, Lausanne, Switzerland; 16. Department of Cardiology, Copenhagen University Hospital, Rigshospitalet, Denmark; 17. Duke Clinical Research Institute, Durham, NC, USA; 18. Department of Internal Medicine II, Division of Cardiology, Medical University of Vienna, Vienna, Austria; 19. Department of Cardiology, German Centre for Cardiovascular Research (DZHK), Ludwig Maximilian University of Munich, Partner Site Munich Heart Alliance, Munich, Germany; 20. Medizinische Klinik I, Landshut-Achdorf Hospital, Landshut, Germany; 21. Department of Interventional Cardiology and Angiology, National Institute of Cardiology, Warszawa, Poland; 22. Department of Biomedical Sciences Humanitas University, Pieve Emanuele, Italy; 23. Humanitas Research Hospital IRCCS Rozzano, Milan, Italy; 24. Institut Universitaire de Cardiologie et de Pneumologie de Québec, Québec, QC, Canada and Université Laval, Québec, QC, Canada; 25. Haut-Leveque Cardiology Hospital, Bordeaux University, Pessac, France; 26. Department of Internal Medicine/Cardiology, Heart Center Leipzig, Leipzig, Germany and University of Leipzig, Leipzig, Germany; 27. Department of Thoracic and Cardiovascular Surgery, West German Heart and Vascular Center, University Hospital Essen, Essen, Germany; 28. Service de Cardiologie, Centre Hospitalier Universitaire de Lille, Lille, France; 29. Heart Valve Center, Heart and Vascular Center, Universitätsmedizin Mainz, Mainz, Germany

Funding

This research received no specific grant from any funding agency in the public, commercial or not-for-profit sectors.

Conflict of interest statement

N. Bonaros reports grants from Edwards Lifesciences and Corcym; and lecture fees from Edwards Lifesciences and Medtronic. P. Carrilho-Ferreira reports lecture fees from AstraZeneca, A. Menarini Diagnostics, Bayer, Biotronik, Medinfar, and Medtronic; and serves on an advisory board for Medtronic. M. Czerny is a consultant for Terumo Aortic, Medtronic, Endospan, and NEOS; and is a shareholder of TEVAR Ltd and Ascense Medical. C. Fraccaro reports support for attending meetings from Medtronic. C. Hassager reports research grants from the Novo Nordisk Foundation and the Lundbeck Foundation; and lecture honorarium from Abiomed. N. Karam reports consulting and lecture fees from Medtronic, Edwards Lifesciences, and Abbott Vascular. W-K. Kim reports lecture fees and honoraria from Abbott, Boston Scientific, Meril Life Sciences, Edwards Lifesciences, Medtronic,

and Shockwave Medical K.A. Krychtiuk reports lecture and/or consulting fees from Amgen, Novartis, and Sanofi. H. Möllmann received speaker honoraria/proctor fees from Abbott, Boston Scientific, Edwards Lifesciences, and Medtronic. J. Pręgowski reports lecture fees from Abbott and Edwards Lifesciences; and contracts from Abbott. G. Tarantini reports lecture fees from Medtronic, Edwards Lifesciences, Abbott Vascular, Boston Scientific, GADA, and Abiomed. J. Ternacle reports consulting fees from Abbott, GE HealthCare, and Philips; and lecture fees from Edwards Lifesciences. The other authors have no conflicts of interest to declare.

References

1. Tabata N, Sinning JM, Kaikita K, Tsujita K, Nickenig G, Werner N. Current status and future perspective of structural heart disease intervention. *J Cardiol*. 2019; 74:1-12.
2. Nieminen MS, Brutsaert D, Dickstein K, Drexler H, Follath F, Harjola VP, Hochadel M, Komajda M, Lassus J, Lopez-Sendon JL, Ponikowski P, Tavazzi L; EuroHeart Survey Investigators; Heart Failure Association, European Society of Cardiology. EuroHeart Failure Survey II (EHFS II): a survey on hospitalized acute heart failure patients: description of population. *Eur Heart J*. 2006;27:2725-36.
3. Bohula EA, Katz JN, Diepen S van, Alviar CL, Baird-Zars VM, Park JG, Barnett CF, Bhattal G, Barsness GW, Burke JA, Cremer PC, Cruz J, Daniels LB, DeFilippis A, Granger CB, Hollenberg S, Horowitz JM, Keller N, Kontos MC, Lawler PR, Menon V, Metkus TS, Ng J, Orgel R, Overgaard CB, Phreaner N, Roswell RO, Schulman SP, Snell RJ, Solomon MA, Ternus B, Tymchak W, Vikram F, Morrow DA; Critical Care Cardiology Trials Network. Demographics, Care Patterns, and Outcomes of Patients Admitted to Cardiac Intensive Care Units: The Critical Care Cardiology Trials Network Prospective North American Multicenter Registry of Cardiac Critical Illness. *JAMA Cardiol*. 2019;4:928-35.
4. Tavazzi G, Rossello X, Grand J, Gierlotka M, Sionis A, Ahrens I, Hassager C, Price S. Epidemiology, monitoring, and treatment strategy in cardiogenic shock. A multinational cross-sectional survey of ESC-acute cardiovascular care association research section. *Eur Heart J Acute Cardiovasc Care*. 2022;11:706-11.
5. Bhatt AS, Berg DD, Bohula EA, Alviar CL, Baird-Zars VM, Barnett CF, Burke JA, Carnicelli AP, Chaudhry SP, Daniels LB, Fang JC, Fordyce CB, Gerber DA, Guo J, Jentzer JC, Katz JN, Keller N, Kontos MC, Lawler PR, Menon V, Metkus TS, Nativi-Nicolau J, Phreaner N, Roswell RO, Sinha SS, Jeffrey Snell R, Solomon MA, Van Diepen S, Morrow DA. De Novo vs Acute-on-Chronic Presentations of Heart Failure-Related Cardiogenic Shock: Insights from the Critical Care Cardiology Trials Network Registry. *J Card Fail*. 2021;27:1073-81.
6. Berg DD, Bohula EA, Morrow DA. Epidemiology and causes of cardiogenic shock. *Curr Opin Crit Care*. 2021;27:401-8.
7. Harjola VP, Lassus J, Sionis A, Køber L, Tarvasmäki T, Spinar J, Parissis J, Banaszewski M, Silva-Cardoso J, Carubelli V, Di Somma S, Tolppanen H, Zeymer U, Thiele H, Nieminen MS, Mebazaa A; CardShock Study Investigators; GREAT network. Clinical picture and risk prediction of short-term mortality in cardiogenic shock. *Eur J Heart Fail*. 2015;17:501-9.
8. Prendergast BD, Baumgartner H, Delgado V, Gérard O, Haude M, Himmelmann A, lung B, Leafstedt M, Lennartz J, Maisano F, Marinelli EA, Modine T, Mueller M, Redwood SR, Rörick O, Sahyoun C, Saillant E, Sondergaard L, Thoenes M, Thomtzeck K, Tschernich M, Vahanian A, Wendler O, Zemke EJ, Bax JJ. Transcatheter heart valve interventions: where are we? Where are we going? *Eur Heart J*. 2019;40: 422-40.
9. Vahanian A, Beyersdorf F, Praz F, Milojevic M, Baldus S, Bauersachs J, Capodanno D, Conradi L, De Bonis M, De Paulis R, Delgado V, Freemantle N, Gilard M, Haugaa KH, Jeppsson A, Jüni P, Pierard L, Prendergast BD, Sádaba JR, Tribouilloy C, Wojakowski W. 2021 ESC/EACTS Guidelines for the management of valvular heart disease. *EuroIntervention*. 2022;17:e1126-96.
10. Zeymer U, Bueno H, Granger CB, Hochman J, Huber K, Lettino M, Price S, Schiele F, Tubaro M, Vranckx P, Zaher D, Thiele H. Acute Cardiovascular Care Association position statement for the diagnosis and treatment of patients with acute myocardial infarction complicated by cardiogenic shock: A document of the Acute Cardiovascular Care Association of the European Society of Cardiology. *Eur Heart J Acute Cardiovasc Care*. 2020;9:183-97.
11. McDonagh TA, Metra M, Adamo M, Gardner RS, Baumbach A, Böhm M, Burri H, Butler J, Čelutkienė J, Chioncel O, Cleland JGF, Coats AJS, Crespo-Leiro MG, Farmakis D, Gilard M, Heymans S, Hoes AW, Jaarsma T, Jankowska EA, Lainscak M, Lam CSP, Lyon AR, McMurray JJV, Mebazaa A, Mindham R, Muneretto C, Francesco Piepoli M, Price S, Rosano GMC, Ruschitzka F, Kathrine Skibelund A; ESC Scientific Group. 2021 ESC Guidelines for the diagnosis and treatment of acute and chronic heart failure. *Eur Heart J*. 2021;42:3599-726.
12. Josiassen J, Frydland M, Hassager C, Møller JE, Perner A, Grand J. Randomized clinical trials of patients with acute myocardial infarction-related cardiogenic shock: a systematic review of used cardiogenic shock definitions and outcomes. *Kardiol Pol*. 2021;79:1003-15.
13. Califf RM, Bengtson JR. Cardiogenic shock. *N Engl J Med*. 1994;330:1724-30.
14. Menon V, Slater JN, White HD, Sleeper LA, Cocke T, Hochman JS. Acute myocardial infarction complicated by systemic hypoperfusion without hypotension: report of the SHOCK trial registry. *Am J Med*. 2000;108:374-80.
15. Shah M, Patnaik S, Patel B, Ram P, Garg L, Agrawal M, Agrawal S, Arora S, Patel N, Wald J, Jorde UP. Trends in mechanical circulatory support use and hospital mortality among patients with acute myocardial infarction and non-infarction related cardiogenic shock in the United States. *Clin Res Cardiol*. 2018;107:287-303.
16. Baran DA, Grines CL, Bailey S, Burkhardt D, Hall SA, Henry TD, Hollenberg SM, Kapur NK, O'Neill W, Ornato JP, Stelling K, Thiele H, van Diepen S, Naidu SS. SCAI clinical expert consensus statement on the classification of cardiogenic shock: This document was endorsed by the American College of Cardiology (ACC), the American Heart Association (AHA), the Society of Critical Care Medicine (SCCM), and the Society of Thoracic Surgeons (STS) in April 2019. *Catheter Cardiovasc Interv*. 2019; 94:29-37.
17. Naidu SS, Baran DA, Jentzer JC, Hollenberg SM, van Diepen S, Basir MB, Grines CL, Diercks DB, Hall S, Kapur NK, Kent W, Rao SV, Samsky MD, Thiele H, Truesdell AG, Henry TD. SCAI SHOCK Stage Classification Expert Consensus Update: A Review and Incorporation of Validation Studies: This statement was endorsed by the American College of Cardiology (ACC), American College of Emergency Physicians (ACEP), American Heart Association (AHA), European Society of Cardiology (ESC) Association for Acute Cardiovascular Care (ACVC), International Society for Heart and Lung Transplantation (ISHLT), Society of Critical Care Medicine (SCCM), and Society of Thoracic Surgeons (STS) in December 2021. *J Am Coll Cardiol*. 2022;79:933-46.
18. Libby P. Braunwald's Heart Disease, 2 Vol Set. A textbook of Cardiovascular Medicine. Bonow RO, Mann DL, Tomaselli GH, Bhatt DL, Solomon SD, Braunwald E, editors. 12th Edition. Elsevier/Saunders. 2021.
19. Bernard S, Deferm S, Bertrand PB. Acute valvular emergencies. *Eur Heart J Acute Cardiovasc Care*. 2022;11:653-65.
20. VARC-3 WRITING COMMITTEE, Généreux P, Piazza N, Alu MC, Nazif T, Hahn RT, Pibarot P, Bax JJ, Leipsic JA, Blanke P, Blackstone EH, Finn MT, Kapadia S, Linke A, Mack MJ, Makkar R, Mehran R, Popma JJ, Reardon M, Rodes-Cabau J, Van Mieghem NM, Webb JG, Cohen DJ, Leon MB. Valve Academic Research Consortium 3: updated endpoint definitions for aortic valve clinical research. *Eur Heart J*. 2021;42: 1825-57.
21. Bang CN, Greve AM, Boman K, Egstrup K, Gohlke-Baerwolf C, Køber L, Nienaber CA, Ray S, Rossebø AB, Wachtell K. Effect of lipid lowering on new-onset atrial fibrillation in patients with asymptomatic aortic stenosis: the Simvastatin and Ezetimibe in Aortic Stenosis (SEAS) study. *Am Heart J*. 2012;163:690-6.
22. Singh GK, van der Bijl P, Goedemans L, Vollema EM, Abou R, Ajmone Marsan N, Bax JJ, Delgado V. Prevalence of Aortic Valve Stenosis in Patients With ST-Segment Elevation Myocardial Infarction and Effect on Long-Term Outcome. *Am J Cardiol*. 2021;153:30-5.
23. Bayer MF. Acute pulmonary edema due to stress cardiomyopathy in a patient with aortic stenosis: a case report. *Cases J*. 2009;2:9128.
24. Conradi PM, van Loon RB, Handoko ML. Dynamic left ventricular outflow tract obstruction in Takotsubo cardiomyopathy resulting in cardiogenic shock. *BMJ Case Rep*. 2021;14:e240010.
25. Migliore F, Bilato C, Isabella G, Iliceto S, Tarantini G. Haemodynamic effects of acute intravenous metoprolol in apical ballooning syndrome with dynamic left ventricular outflow tract obstruction. *Eur J Heart Fail*. 2010;12:305-8.
26. Elkayam U, Goland S, Pieper PG, Silverside CK. High-Risk Cardiac Disease in Pregnancy: Part I. *J Am Coll Cardiol*. 2016;68:396-410.
27. Silversides CK, Colman JM, Sermer M, Siu SC. Cardiac risk in pregnant women with rheumatic mitral stenosis. *Am J Cardiol*. 2003;91:1382-5.
28. Hameed A, Karaalp IS, Tummala PP, Wani OR, Canetti M, Akhter MW, Goodwin I, Zapadinsky N, Elkayam U. The effect of valvular heart disease on maternal and fetal outcome of pregnancy. *J Am Coll Cardiol*. 2001;37:893-9.
29. Samiei N, Amirardari M, Rezaei Y, Parsaee M, Kashfi F, Hantoosh Zadeh S, Beikmohamadi S, Fouladi M, Hosseini S, Peighambari MM, Mohebbi A. Echocardiographic Evaluation of Hemodynamic Changes in Left-Sided Heart Valves in Pregnant Women With Valvular Heart Disease. *Am J Cardiol*. 2016;118:1046-52.
30. van Hagen IM, Thorne SA, Taha N, Youssef G, Elnagar A, Gabriel H, ElRakshy Y, lung B, Johnson MR, Hall R, Roos-Hesslink JW; ROPAC Investigators and EORP

- Team. Pregnancy Outcomes in Women With Rheumatic Mitral Valve Disease: Results From the Registry of Pregnancy and Cardiac Disease. *Circulation*. 2018;137:806-16.
31. Fraccaro C, Tence N, Masiero G, Karam N. Management of Valvular Disease During Pregnancy: Evolving Role of Percutaneous Treatment. *Interv Cardiol*. 2020;15:e10.
32. Cecconi M, Evans L, Levy M, Rhodes A. Sepsis and septic shock. *Lancet*. 2018;392:75-87.
33. Minamino-Muta E, Kato T, Morimoto T, Taniguchi T, Shiomi H, Nakatsuma K, Shirai S, Ando K, Kanamori N, Murata K, Kitai T, Kawase Y, Miyake M, Izumi C, Mitsuoka H, Kato M, Hirano Y, Matsuda S, Nagao K, Inada T, Murakami T, Takeuchi Y, Yamane K, Toyofuku M, Ishii M, Inoko M, Ikeda T, Komasa A, Tada E, Ishii K, Hotta K, Higashitani N, Jinnai T, Kato Y, Inuzuka Y, Maeda C, Morikami Y, Saito N, Sakata R, Minatoya K, Kimura T. Causes of Death in Patients with Severe Aortic Stenosis: An Observational study. *Sci Rep*. 2017;7:14723.
34. Banovic M, Putnik S, Penicka M, Doros G, Deja MA, Kockova R, Kotrc M, Glaveckaite S, Gasparovic H, Pavlovic N, Velicki L, Salizzoni S, Wojakowski W, Van Camp G, Nikolic SD, lung B, Bartunek J; AVATAR-Trial Investigators*. Aortic Valve Replacement versus Conservative Treatment in Asymptomatic Severe Aortic Stenosis: The AVATAR Trial. *Circulation*. 2022;145:648-58.
35. Kang DH, Park SJ, Lee SA, Lee S, Kim DH, Kim HK, Yun SC, Hong GR, Song JM, Chung CH, Song JK, Lee JW, Park SW. Early Surgery or Conservative Care for Asymptomatic Aortic Stenosis. *N Engl J Med*. 2020;382:111-9.
36. Litmanovitch M, Joynt GM, Skoularigis J, Lipman J. Emergency percutaneous balloon mitral valvotomy in a patient with septic shock. *Chest*. 1995;108:570-2.
37. Okutucu S, Fatihoglu SG, Lacoste MO, Oto A. Echocardiographic assessment in cardiogenic shock. *Herz*. 2021;46:467-75.
38. Sannino A, Gargiulo G, Schiattarella GG, Brevetti L, Perrino C, Stabile E, Losi MA, Toscano E, Giugliano G, Scudiero F, Chiacchio E, Trimarco B, Esposito G. Increased mortality after transcatheter aortic valve implantation (TAVI) in patients with severe aortic stenosis and low ejection fraction: a meta-analysis of 6898 patients. *Int J Cardiol*. 2014;176:32-9.
39. Faroux L, Guimaraes L, Wintzer-Wehekind J, Junquera L, Ferreira-Neto AN, Del Val D, Muntané-Carol G, Mohammadi S, Paradis JM, Rodés-Cabau J. Coronary Artery Disease and Transcatheter Aortic Valve Replacement: JACC State-of-the-Art Review. *J Am Coll Cardiol*. 2019;74:362-72.
40. Masha L, Vemulapalli S, Manandhar P, Balan P, Shah P, Kosinski AS, Stewart G. Demographics, Procedural Characteristics, and Clinical Outcomes When Cardiogenic Shock Precedes TAVR in the United States. *JACC Cardiovasc Interv*. 2020;13:1314-25.
41. Shamekhi J, Weber M, Sugiura A, Öztürk C, Treede H, Grube E, Werner N, Nickenig G, Sinning JM. Impact of Coronary Artery Disease on Outcomes in Patients Undergoing Percutaneous Edge-to-Edge Repair. *JACC Cardiovasc Interv*. 2020;13:2137-45.
42. Ranka S, Mastoris I, Kapur NK, Tedford RJ, Rali A, Acharya P, Weidling R, Goyal A, Sauer AJ, Gupta B, Haglund N, Gupta K, Fang JC, Lindenfeld J, Shah Z. Right Heart Catheterization in Cardiogenic Shock Is Associated With Improved Outcomes: Insights From the Nationwide Readmissions Database. *J Am Heart Assoc*. 2021;10:e019843.
43. Garan AR, Kanwar M, Thayer KL, Whitehead E, Zweck E, Hernandez-Montfort J, Mahr C, Haywood JL, Harwani NM, Wencker D, Sinha SS, Vorovich E, Abraham J, O'Neill W, Burkhoff D, Kapur NK. Complete Hemodynamic Profiling With Pulmonary Artery Catheters in Cardiogenic Shock Is Associated With Lower In-Hospital Mortality. *JACC Heart Fail*. 2020;8:903-13.
44. Chen Y, Shlofmitz E, Khalid N, Bernardo NL, Ben-Dor I, Weintraub WS, Waksman R. Right Heart Catheterization-Related Complications: A Review of the Literature and Best Practices. *Cardiol Rev*. 2020;28:36-41.
45. Binanay C, Califf RM, Hasselblad V, O'Connor CM, Shah MR, Sopko G, Stevenson LW, Francis GS, Leier CV, Miller LW; ESCAPE Investigators and ESCAPE Study Coordinators. Evaluation study of congestive heart failure and pulmonary artery catheterization effectiveness: the ESCAPE trial. *JAMA*. 2005;294:1625-33.
46. Villablanca P, Nona P, Lemor A, Qintar M, O'Neill B, Lee J, Frisoli T, Wang DD, Eng MH, O'Neill WW. Mechanical Circulatory Support in Cardiogenic Shock due to Structural Heart Disease. *Interv Cardiol Clin*. 2021;10:221-34.
47. Santana JM, Dalia AA, Newton M, Pisano DV, Eapen S, Kawabori M, Ortoleva J. Mechanical Circulatory Support Options in Patients With Aortic Valve Pathology. *J Cardiothorac Vasc Anesth*. 2022;36:3318-26.
48. Maack C, Eschenhagen T, Hamdani N, Heinzl FR, Lyon AR, Manstein DJ, Metzger J, Papp Z, Tocchetti CG, Yilmaz MB, Anker SD, Balligand JL, Bauersachs J, Brutsaert D, Carrier L, Chopicki S, Cleland JG, de Boer RA, Dietl A, Fischmeister R, Harjola VP, Heymans S, Hilffiker-Kleiner D, Holzmeister J, de Keulenaer G, Limongelli G, Linke WA, Lund LH, Masip J, Metra M, Mueller C, Pieske B, Ponikowski P, Ristić A, Ruschitzka F, Seferović PM, Skouri H, Zimmermann WH, Mebazaa A. Treatments targeting inotropy. *Eur Heart J*. 2019;40:3626-44.
49. Ahmad T, Miller PE, McCullough M, Desai NR, Riello R, Psotka M, Böhm M, Allen LA, Teerlink JR, Rosano GMC, Lindenfeld J. Why has positive inotropy failed in chronic heart failure? Lessons from prior inotrope trials. *Eur J Heart Fail*. 2019;21:1064-78.
50. Nishino S, Watanabe N, Kimura T, Enriquez-Sarano M, Nakama T, Furugen M, Koiwaya H, Ashikaga K, Kuriyama N, Shibata Y. The Course of Ischemic Mitral Regurgitation in Acute Myocardial Infarction After Primary Percutaneous Coronary Intervention: From Emergency Room to Long-Term Follow-Up. *Circ Cardiovasc Imaging*. 2016;9:e004841.
51. Fraccaro C, Campante Teles R, Tchêché D, Saia F, Bedogni F, Montorfano M, Fiorina C, Meucci F, De Benedictis M, Leonzi O, Barbierato M, Dumonteil N, Stolicova M, Maffeo D, Compagnone M, Brito J, Chieffo A, Tarantini G. Transcatheter aortic valve implantation (TAVI) in cardiogenic shock: TAVI-shock registry results. *Catheter Cardiovasc Interv*. 2020;96:1128-35.
52. Egbe AC, Pislaru SV, Pellikka PA, Poterucha JT, Schaff HV, Maleszewski JJ, Connolly HM. Bioprosthetic Valve Thrombosis Versus Structural Failure: Clinical and Echocardiographic Predictors. *J Am Coll Cardiol*. 2015;66:2285-94.
53. Dangas GD, Weitz JI, Giustino G, Makkar R, Mehran R. Prosthetic Heart Valve Thrombosis. *J Am Coll Cardiol*. 2016;68:2670-89.
54. Karthikeyan G, Senguttuvan NB, Joseph J, Devasenapathy N, Bahl VK, Airan B. Urgent surgery compared with fibrinolytic therapy for the treatment of left-sided prosthetic heart valve thrombosis: a systematic review and meta-analysis of observational studies. *Eur Heart J*. 2013;34:1557-66.
55. Higuchi R, Tobaru T, Hagiya K, Saji M, Takamisawa I, Shimizu J, Iguchi N, Takanashi S, Takayama M, Isobe M. Outcomes of patients requiring extracorporeal membrane oxygenation in transcatheter aortic valve implantation: a clinical case series. *Heart Vessels*. 2018;33:1343-9.
56. Seco M, Forrest P, Jackson SA, Martinez G, Andvik S, Bannon PG, Ng M, Fraser JF, Wilson MK, Valley MP. Extracorporeal membrane oxygenation for very high-risk transcatheter aortic valve implantation. *Heart Lung Circ*. 2014;23:957-62.
57. Singh V, Patel SV, Savani C, Patel NJ, Patel N, Arora S, Panaich SS, Deshmukh A, Cleman M, Mangi A, Forrest JK, Badheka AO. Mechanical circulatory support devices and transcatheter aortic valve implantation (from the National Inpatient Sample). *Am J Cardiol*. 2015;116:1574-80.
58. Cheng R, Dawkins S, Hamilton MA, Makar M, Hussaini A, Azarbal B, Patel JK, Kobashigawa JA, Trento A, Makkar RR, Kar S. Percutaneous Mitral Repair for Patients in Cardiogenic Shock Requiring Inotropes and Temporary Mechanical Circulatory Support. *JACC Cardiovasc Interv*. 2019;12:2440-1.
59. Alkhalil A, Hajjar R, Ibrahim H, Ruiz CE. Mechanical Circulatory Support in Transcatheter Aortic Valve Implantation in the United States (from the National Inpatient Sample). *Am J Cardiol*. 2019;124:1615-20.
60. Folland ED, Kemper AJ, Khuri SF, Josa M, Parisi AF. Intraaortic balloon counterpulsation as a temporary support measure in decompensated critical aortic stenosis. *J Am Coll Cardiol*. 1985;5:711-6.
61. Vandembriele C, Balthazar T, Wilson J, Adriaenssens T, Davies S, Droogne W, Dubois C, Caetano AF, Goetschalckx K, Jacobs S, Janssens S, Ledot S, Meyns B, Soliman-Aboumarie H, Verbrugge P, Price S. Left Impella®-device as bridge from cardiogenic shock with acute, severe mitral regurgitation to MitraClip®-procedure: a new option for critically ill patients. *Eur Heart J Acute Cardiovasc Care*. 2021;10:415-21.
62. Johnson DW, Erwin III JP. Use of Impella 5.0 Prior to Transcatheter Aortic Valve Replacement in a Patient with Severe Aortic Stenosis and Cardiogenic Shock. *J Heart Valve Dis*. 2017;26:485-7.
63. Muraca I, Pennesi M, Carrabba N, Scudiero F, Migliorini A, Marchionni N, Stefano P, Valenti R. Percutaneous left ventricular advanced support for 'protected' complex high-risk transcatheter mitral valve repair: a case series. *Eur Heart J Case Rep*. 2020;4:1-7.
64. Abraham J, Wang L, Kumar V, Kirker EB, Spinelli KJ. Axillary transvalvular microaxial pump as extended bridge to transcatheter aortic valve replacement in cardiogenic shock with severe aortic stenosis. *J Heart Lung Transplant*. 2022;41:434-7.
65. Tehrani BN, Truesdell AG, Sherwood MW, Desai S, Tran HA, Epps KC, Singh R, Psotka M, Shah P, Cooper LB, Rosner C, Raja A, Barnett SD, Saulino P, deFilippi CR, Gurbel PA, Murphy CE, O'Connor CM. Standardized Team-Based Care for Cardiogenic Shock. *J Am Coll Cardiol*. 2019;73:1659-69.
66. Basir MB, Kapur NK, Patel K, Salam MA, Schreiber T, Kaki A, Hanson I, Almany S, Timmis S, Dixon S, Kolski B, Todd J, Senter S, Marso S, Lasorda D, Wilkins C, Lalonde T, Attallah A, Larkin T, Dupont A, Marshall J, Patel N, Overly T, Green M, Tehrani B, Truesdell AG, Sharma R, Akhtar Y, McRae T 3rd, O'Neill B, Finley J, Rahman A, Foster M, Askari R, Goldsweig A, Martin S, Bharadwaj A, Khuddus M, Caputo C, Korpas D, Cawich I, McAllister D, Blank N, Alraies MC,

- Fisher R, Khandelwal A, Alaswad K, Lemor A, Johnson T, Hacala M, O'Neill W; National Cardiogenic Shock Initiative Investigators. Improved Outcomes Associated with the use of Shock Protocols: Updates from the National Cardiogenic Shock Initiative. *Catheter Cardiovasc Interv.* 2019;93:1173-83.
67. Tehrani BN, Truesdell AG, Psotka MA, Rosner C, Singh R, Sinha SS, Damluji AA, Batchelor WB. A Standardized and Comprehensive Approach to the Management of Cardiogenic Shock. *JACC Heart Fail.* 2020;8:879-91.
68. Parlow S, Weng W, Di Santo P, Jung RG, Lepage-Ratte MF, Motazedian P, Prosperi-Porta G, Abdel-Razek O, Simard T, Chan V, Labinaz M, Froeschl M, Mathew R, Hibbert B; CAPITAL DOREMI Investigators. Significant Valvular Dysfunction and Outcomes in Cardiogenic Shock: Insights From the Randomized DOREMI Trial. *Can J Cardiol.* 2022;38:1211-9.
69. Frerker C, Schewel J, Schlüter M, Schewel D, Ramadan H, Schmidt T, Thielsen T, Kreidel F, Schlingloff F, Bader R, Wöhlmuth P, Schäfer U, Kuck KH. Emergency transcatheter aortic valve replacement in patients with cardiogenic shock due to acutely decompensated aortic stenosis. *EuroIntervention.* 2016;11:1530-6.
70. Estévez-Loureiro R, Shuvy M, Taramasso M, Benito-Gonzalez T, Denti P, Arzamendi D, Adamo M, Freixa X, Villablanca P, Krivoshei L, Fam N, Spargias K, Czarnecki A, Haberman D, Agmon Y, Sudarsky D, Pascual I, Ninios V, Scianna S, Moaraf I, Schiavi D, Chrissoheris M, Beeri R, Kerner A, Fernández-Peregrina E, Di Pasquale M, Regueiro A, Poles L, Iñiguez-Romo A, Fernández-Vázquez F, Maisano F. Use of MitraClip for mitral valve repair in patients with acute mitral regurgitation following acute myocardial infarction: Effect of cardiogenic shock on outcomes (IREMMI Registry). *Catheter Cardiovasc Interv.* 2021;97:1259-67.
71. Maheshwari V, Barr B, Srivastava M. Acute Valvular Heart Disease. *Cardiol Clin.* 2018;36:115-27.
72. Jentzer JC, Ternus B, Eleid M, Rihal C. Structural Heart Disease Emergencies. *J Intensive Care Med.* 2021;36:975-88.
73. Akodad M, Schurtz G, Adda J, Leclercq F, Roubille F. Management of valvulopathies with acute severe heart failure and cardiogenic shock. *Archives of Cardiovasc Dis.* 2019;112:773-80.
74. Habib G, Lancellotti P, Antunes MJ, Bongiorni MG, Casalta JP, Del Zotti F, Dulgheru R, El Khoury G, Erba PA, Jung B, Miro JM, Mulder BJ, Plonska-Gosciniak E, Price S, Roos-Hesselink J, Snygg-Martín U, Thuny F, Tornos Mas P, Vilacosta I, Zamorano JL; ESC Scientific Document Group. 2015 ESC Guidelines for the management of infective endocarditis: The Task Force for the Management of Infective Endocarditis of the European Society of Cardiology (ESC). Endorsed by: European Association for Cardio-Thoracic Surgery (EACTS), the European Association of Nuclear Medicine (EANM). *Eur Heart J.* 2015;36:3075-128.
75. Habib G, Avierinos JF, Thuny F. Aortic valve endocarditis: is there an optimal surgical timing? *Curr Opin Cardiol.* 2007;22:77-83.
76. Hutter AM, De Sanctis RW, Nathan MJ, Buckley MJ, Mundth ED, Daggett WM, Austen WG. Aortic valve surgery as an emergency procedure. *Circulation.* 1970;41:623-7.
77. Carabello BA, Green LH, Grossman W, Cohn LH, Koster JK, Collins JJ Jr. Hemodynamic determinants of prognosis of aortic valve replacement in critical aortic stenosis and advanced congestive heart failure. *Circulation.* 1980;62:42-8.
78. Oettinger V, Kaier K, Mühlen C von zur, Zehender M, Bode C, Beyersdorf F, Stachon P, Bothe W. Impact of Procedure Volume on the Outcomes of Surgical Aortic Valve Replacement. *Thorac Cardiovasc Surg.* 2022 Aug 2. [Epub ahead of print].
79. Gelsomino S, Maessen JG, van der Veen F, Livi U, Renzulli A, Luca F, Carella R, Crudeli E, Rubino A, Rostagno C, Russo C, Borghetti V, Beghi C, De Bonis M, Gensini GF, Lorusso R. Emergency surgery for native mitral valve endocarditis: the impact of septic and cardiogenic shock. *Ann Thorac Surg.* 2012;93:1469-76.
80. Thompson CR, Buller CE, Sleeper LA, Antonelli TA, Webb JG, Jaber WA, Abel JG, Hochman JS. Cardiogenic shock due to acute severe mitral regurgitation complicating acute myocardial infarction: a report from the SHOCK Trial Registry. Should we use emergently revascularize Occluded Coronaries in cardiogenic shock? *J Am Coll Cardiol.* 2000;36:1104-9.
81. Ibanez B, James S, Agewall S, Antunes MJ, Bucciarelli-Ducci C, Bueno H, Caforio ALP, Crea F, Goudevanos JA, Halvorsen S, Hindricks G, Kasrati A, Lenzen M, Prescott E, Roffi M, Valgimigli M, Varenhorst C, Vranckx P, Widimský P; ESC Scientific Document Group. 2017 ESC Guidelines for the management of acute myocardial infarction in patients presenting with ST-segment elevation: The Task Force for the management of acute myocardial infarction in patients presenting with ST-segment elevation of the European Society of Cardiology (ESC). *Eur Heart J.* 2018;39:119-77.
82. Percutaneous balloon aortic valvuloplasty. Acute and 30-day follow-up results in 674 patients from the NHLBI Balloon Valvuloplasty Registry. *Circulation.* 1991;84:2383-97.
83. Cribier A, Remadi F, Koning R, Rath P, Stix G, Letac B. Emergency balloon valvuloplasty as initial treatment of patients with aortic stenosis and cardiogenic shock. *N Engl J Med.* 1992;326:646.
84. Moreno PR, Jang IK, Newell JB, Block PC, Palacios IF. The role of percutaneous aortic balloon valvuloplasty in patients with cardiogenic shock and critical aortic stenosis. *J Am Coll Cardiol.* 1994;23:1071-5.
85. Buchwald AB, Meyer T, Scholz K, Schorn B, Unterberg C. Efficacy of balloon valvuloplasty in patients with critical aortic stenosis and cardiogenic shock-the role of shock duration. *Clin Cardiol.* 2001;24:214-8.
86. Saia F, Marrozzini C, Ciuca C, Guastaroba P, Taglieri N, Palmerini T, Bordoni B, Moretti C, Dall'Ara G, Branzi A, Marzocchi A. Emerging indications, in-hospital and long-term outcome of balloon aortic valvuloplasty in the transcatheter aortic valve implantation era. *EuroIntervention.* 2013;8:1388-97.
87. Theiss HD, Greif M, Steinbeck G, Kupatt C, Franz WM. Balloon valvuloplasty for treatment of cardiogenic shock in the era of surgical valve replacement and TAVI. *Intern Emerg Med.* 2014;9:345-7.
88. Bongiovanni D, Kühl C, Bleiziffer S, Stecher L, Poch F, Greif M, Mehili J, Massberg S, Frey N, Lange R, Laugwitz KL, Schymik G, Frank D, Kupatt C. Emergency treatment of decompensated aortic stenosis. *Heart.* 2018;104:23-9.
89. Debyr N, Kone P, Vincent F, Lemesle G, Delhaye C, Schurtz G, Spillemaeker H, Porouchani S, Coisne A, Auffray JL, Sudre A, Lamblin N, Bonello L, Van Belle E. Urgent balloon aortic valvuloplasty in patients with cardiogenic shock related to severe aortic stenosis: time matters. *EuroIntervention.* 2018;14:e519-25.
90. Eugène M, Urena M, Abtan J, Carrasco JL, Ghodbane W, Nataf P, Vahanian A, Himbert D. Effectiveness of Rescue Percutaneous Balloon Aortic Valvuloplasty in Patients With Severe Aortic Stenosis and Acute Heart Failure. *Am J Cardiol.* 2018;121:746-50.
91. Varela ML, Teixeira P, Ponte M, Caeiro D, Dias A, Rodrigues A, Braga P. Balloon Aortic Valvuloplasty in Patients Admitted for Cardiogenic Shock with Severe Aortic Stenosis: A Retrospective Analysis of 14 Cases. *Cureus.* 2019;11:e5407.
92. D'Ancona G, Pasic M, Buz S, Drews T, Dreyse S, Kukucka M, Hetzer R, Unbehaun A. Transapical transcatheter aortic valve replacement in patients with cardiogenic shock. *Interact Cardiovasc Thorac Surg.* 2012;14:426-30.
93. Huang H, Kovach CP, Bell S, Reisman M, Aldea G, McCabe JM, Dvir D, Don C. Outcomes of Emergency Transcatheter Aortic Valve Replacement. *J Interv Cardiol.* 2019;2019:7598581.
94. Chakraborty S, Patel N, Bandyopadhyay D, Hajra A, Amgai B, Zaid S, Sharedalal P, Ahmad H, Cohen MB, Abbott JD, Naidu SS. Readmission following urgent transcatheter aortic valve implantation versus urgent balloon aortic valvuloplasty in patients with decompensated heart failure or cardiogenic shock. *Catheter Cardiovasc Interv.* 2021;98:607-12.
95. Puri R, Jung B, Cohen DJ, Rodés-Cabau J. TAVI or No TAVI: identifying patients unlikely to benefit from transcatheter aortic valve implantation. *Eur Heart J.* 2016;37:2217-25.
96. Vallabhajosyula S, Patlolla SH, Sandhyavenu H, Vallabhajosyula S, Barsness GW, Dunlay SM, Greason KL, Holmes DR Jr, Eleid MF. Periprocedural Cardiopulmonary Bypass or Venous Arterial Extracorporeal Membrane Oxygenation During Transcatheter Aortic Valve Replacement: A Systematic Review. *J Am Heart Assoc.* 2018;7:e009608.
97. Burzotta F, Nerla R, Trani C. Bail-Out Use of Impella CP as a Bridge to TAVI in a Cardiogenic Shock Patient: The 'Pump-Rewiring' Technique. *J Invasive Cardiol.* 2016;28:E1-5.
98. Hamid N, Ranard LS, Khaliq OK, Hahn RT, Nazif TM, George I, Ng V, Leon MB, Kodali SK, Vahl TP. Commissural Alignment After Transfemoral Transcatheter Aortic Valve Replacement With the JenaValve Trilog System. *JACC Cardiovasc Interv.* 2021;14:2079-81.
99. Arora S, Lahewala S, Zuzek Z, Thakkar S, Jani C, Jaswaney R, Singh A, Bhyan P, Arora N, Main A, Osman MN, Hoit BD, Attizzani GF, Panaich SS. Transcatheter aortic valve replacement in aortic regurgitation: The U.S. experience. *Catheter Cardiovasc Interv.* 2021;98:E153-162.
100. Purita PAM, Tahoces LS, Fraccaro C, Nai Fovino L, Kim WK, Espada-Guerreiro C, De Backer O, Seiffert M, Nombela-Franco L, Gomez RM, Mangieri A, Franzona A, Bedogni F, Castriota F, Attisano T, Søndergaard L, Antolin RH, Tarantini G. Transcatheter treatment of native aortic valve regurgitation: Results from an international registry using the transfemoral ACURATE neo valve. *Int J Cardiol Heart Vasc.* 2020;27:100480.
101. Jiang J, Liu X, He Y, Xu Q, Zhu Q, Jaiswal S, Wang L, Hu P, Gao F, Sun Y, Liu C, Lin X, Liang J, Ren K, Wang JAA. Transcatheter Aortic Valve Replacement for Pure Native Aortic Valve Regurgitation: A Systematic Review. *Cardiology.* 2018;141:132-40.
102. Pesarini G, Lunardi M, Piccoli A, Gottin L, Prati D, Ferrero V, Scarsini R, Milano A, Forni A, Faggiani G, Ribichini F. Effectiveness and Safety of Transcatheter Aortic Valve Implantation in Patients With Pure Aortic Regurgitation and Advanced Heart Failure. *Am J Cardiol.* 2018;121:642-8.
103. Roy DA, Schaefer U, Guetta V, Hildick-Smith D, Möllmann H, Dumonteil N, Modine T, Bosmans J, Petronio AS, Moat N, Linke A, Moris C, Champagnac D,

- Parma R, Ochala A, Medvedofsky D, Patterson T, Woitek F, Jahangiri M, Laborde JC, Brecker SJ. Transcatheter aortic valve implantation for pure severe native aortic valve regurgitation. *J Am Coll Cardiol*. 2013;61:1577-84.
104. Yin WH, Lee YT, Tsao TP, Lee KC, Hsiung MC, Wei J. Outcomes of transcatheter aortic valve replacement for pure native aortic regurgitation with the use of newer- vs. early-generation devices. *Ann Transl Med*. 2022;10:24.
105. Spina R, Khalique O, Kodali S, Bapat VN. Urgent transcatheter aortic valve replacement for severe acute aortic regurgitation following open mitral valve surgery. *Catheter Cardiovasc Interv*. 2019;93:996-1001.
106. M Herrmann FE, Wellmann P, von Dossow V, Massberg S, Hagl C, Schramm R, Pichlmaier M. Rescue TAVI for Aortic Regurgitation after Left Ventricular Assist Device Implantation Following Preoperative Impella® Support. *J Heart Valve Dis*. 2017;26:603-5.
107. van der Werf HW, Schurer RA, Vonck TE, Poelman JE, Klungel AA, Cernak V, van den Heuvel AF, van der Harst P. Emergency transcatheter aortic valve implantation in patients with severe aortic regurgitation and a left ventricle assist device: A case report and systematic review. *Eur Heart J Acute Cardiovasc Care*. 2017;6:719-27.
108. Abdelaziz HK, Wiper A, More RS, Bittar MN, Roberts DH. Successful Transcatheter Aortic Valve Replacement Using Balloon-Expandable Valve for Pure Native Aortic Valve Regurgitation in the Presence of Ascending Aortic Dissection. *J Invasive Cardiol*. 2018;30:E62-3.
109. Kreibich M, Rylski B, Beyersdorf F, Siepe M, Czerny M. Endo-Bentall for proximal aortic dissection: from conception to application. *Asian Cardiovasc Thorac Ann*. 2021;29:697-700.
110. Phan K, Haswell JM, Xu J, Assem Y, Mick SL, Kapadia SR, Cheung A, Ling FS, Yan TD, Tehanchaleishvili V. Percutaneous Transcatheter Interventions for Aortic Insufficiency in Continuous-Flow Left Ventricular Assist Device Patients: A Systematic Review and Meta-Analysis. *ASAIO J*. 2017;63:117-22.
111. Inoue K, Owaki T, Nakamura T, Kitamura F, Miyamoto N. Clinical application of transvenous mitral commissurotomy by a new balloon catheter. *J Thorac Cardiovasc Surg*. 1984;87:394-402.
112. Lock JE, Khalilullah M, Shrivastava S, Bahl V, Keane JF. Percutaneous catheter commissurotomy in rheumatic mitral stenosis. *N Engl J Med*. 1985;313:1515-8.
113. Dugal JS, Jetley V, Sabharwal JS, Sofat S, Singh C. Life-saving PTMC for critical calcific mitral stenosis in cardiogenic shock with balloon impasse. *Int J Cardiovasc Intervent*. 2003;5:172-4.
114. Endrys J, Habashy AG, Hayat N. Life-saving balloon mitral valvuloplasty in patient with cardiogenic shock after cardiac arrest. *J Invasive Cardiol*. 2001;13:752-4.
115. Kapoor MC, Dugal JS, Sharma S, Singh S. Percutaneous transvenous mitral commissurotomy—a life saving option in severe mitral stenosis with cardiogenic shock. *Ann Card Anaesth*. 2004;7:158-61.
116. Lokhandwala YY, Banker D, Vora AM, Kerker PG, Deshpande JR, Kulkarni HL, Dalvi BV. Emergent balloon mitral valvotomy in patients presenting with cardiac arrest, cardiogenic shock or refractory pulmonary edema. *J Am Coll Cardiol*. 1998;32:154-8.
117. Ananthakrishna Pillai A, Ramasamy C, V SG, Kottyath H. Outcomes following balloon mitral valvuloplasty in pregnant females with mitral stenosis and significant sub valve disease with severe decompensated heart failure. *J Interv Cardiol*. 2018;31:525-31.
118. Notrica M, Wisner J, Villagra L, Rossini A, Gonzalia D, Adaro M, Zillo A, Izcovich E, Albertal M. Life-saving percutaneous mitral valvuloplasty on a pregnant woman with refractory cardiogenic shock. *Heart Lung Circ*. 2009;18:301-4.
119. Regitz-Zagrosek V, Roos-Hesselink JW, Bauersachs J, Blomström-Lundqvist C, Cifková R, De Bonis M, Iung B, Johnson MR, Kintscher U, Kranke P, Lang IM, Morais J, Pieper PG, Presbitero P, Price S, Rosano GMC, Seeland U, Simoncini T, Swan L, Warnes CA; ESC Scientific Document Group. 2018 ESC Guidelines for the management of cardiovascular diseases during pregnancy. *Eur Heart J*. 2018;39:3165-241.
120. Lorusso R, Gelsomino S, De Cicco G, Beghi C, Russo C, De Bonis M, Colli A, Sala A. Mitral valve surgery in emergency for severe acute regurgitation: analysis of postoperative results from a multicentre study. *Eur J Cardiothorac Surg*. 2008;33:573-82.
121. Feldman T, Foster E, Glower DD, Glower DG, Kar S, Rinaldi MJ, Fail PS, Smalling RW, Siegel R, Rose GA, Engeron E, Lohin C, Trento A, Skipper ER, Fudge T, Letsou GV, Massaro JM, Mauri L; EVEREST II Investigators. Percutaneous repair or surgery for mitral regurgitation. *N Engl J Med*. 2011;364:1395-406.
122. Obadia JF, Messika-Zeitoun D, Leurent G, Iung B, Bonnet G, Piriou N, Lefèvre T, Piot C, Rouleau F, Carrié D, Nejari M, Ohlmann P, Leclercq F, Saint Etienne C, Teiger E, Leroux L, Karam N, Michel N, Gilard M, Donal E, Trochu J-N, Cormier B, Armoiry X, Boutitie F, Maucort-Boulch D, Barnel C, Samson G, Guerin P, Vahanian A, Mewton N; MITRA-FR Investigators. Percutaneous Repair or Medical Treatment for Secondary Mitral Regurgitation. *N Engl J Med*. 2018;379:2297-306.
123. Stone GW, Lindenfeld J, Abraham WT, Kar S, Lim DS, Mishell JM, Whisenant B, Grayburn PA, Rinaldi M, Kapadia SR, Rajagopal V, Sarembock IJ, Brieke A, Marx SO, Cohen DJ, Weissman NJ, Mack MJ; COAPT Investigators. Transcatheter Mitral-Valve Repair in Patients with Heart Failure. *N Engl J Med*. 2018;379:2307-18.
124. Jung RG, Simard T, Kovach C, Flint K, Don C, Di Santo P, Adamo M, Branca L, Valentini F, Benito-González T, Fernández-Vázquez F, Estévez-Loureiro R, Berardini A, Conti N, Rapezzi C, Biagini E, Parlow S, Shorr R, Levi A, Manovel A, Cardenal-Piris R, Diaz Fernandez J, Shuyv V, Haberman D, Sala A, Alkhouli MA, Marini C, Bargagna M, Schiavi D, Denti P, Markovic S, Buzzatti N, Chan V, Hynes M, Mesana T, Labinaz M, Pappalardo F, Taramasso M, Hibbert B. Transcatheter Mitral Valve Repair in Cardiogenic Shock and Mitral Regurgitation: A Patient-Level, Multicenter Analysis. *JACC Cardiovasc Interv*. 2021;14:1-11.
125. Adamo M, Curello S, Chiari E, Fiorina C, Chizzola G, Magatelli M, Locantore E, Cuminetti G, Lombardi C, Manzato A, Metra M, Ertori F. Percutaneous edge-to-edge mitral valve repair for the treatment of acute mitral regurgitation complicating myocardial infarction: A single centre experience. *Int J Cardiol*. 2017;234:53-7.
126. Seizer P, Schibilsky D, Sauter R, Schreieck J, Lausberg H, Walker T, Gawaz M, Langer HF, Schlensak C. Percutaneous Mitral Valve Edge-to-Edge Repair Assisted by Hemodynamic Support Devices: A Case Series of Bailout Procedures. *Circ Heart Fail*. 2017;10:e004051.
127. Flint K, Brieke A, Wiktor D, Carroll J. Percutaneous edge-to-edge mitral valve repair may rescue select patients in cardiogenic shock: Findings from a single center case series. *Catheter Cardiovasc Interv*. 2019;94:E82-7.
128. Chan V, Messika-Zeitoun D, Labinaz M, Hynes M, Nicholson D, Dryden A, Mesana T, Hibbert B. Percutaneous Mitral Repair as Salvage Therapy in Patients With Mitral Regurgitation and Refractory Cardiogenic Shock. *Circ Cardiovasc Interv*. 2019;12:e008435.
129. Garcia S, Alsidawi S, Bae R, Cavalcante J, Eckman P, Gössl M, Steffen R, Sun B, Schmidt CW, Sorajja P. Percutaneous Mitral Valve Repair With MitraClip in Inoperable Patients With Severe Mitral Regurgitation Complicated by Cardiogenic Shock. *J Invasive Cardiol*. 2020;32:228-31.
130. Falasconi G, Melillo F, Pannone L, Adamo M, Ronco F, Latib A, Rahgozar K, Carrabba N, Valenti R, Citro R, Stella S, Ingallina G, Capogrosso C, Scandroglio M, Ancona F, Godino C, Denti P, Castiglioni A, De Bonis M, Colombo A, Lupi L, Branca L, Montorfano M, Agricola E. Use of edge-to-edge percutaneous mitral valve repair for severe mitral regurgitation in cardiogenic shock: A multicenter observational experience (MITRA-SHOCK study). *Catheter Cardiovasc Interv*. 2021;98:E163-70.
131. Tang GHL, Estevez-Loureiro R, Yu Y, Prillinger JB, Zaid S, Psotka MA. Survival Following Edge-to-Edge Transcatheter Mitral Valve Repair in Patients With Cardiogenic Shock: A Nationwide Analysis. *J Am Heart Assoc*. 2021;10:e019882.
132. Capodanno D, Petronio AS, Prendergast B, Eltchaninoff H, Vahanian A, Modine T, Lancellotti P, Sondergaard L, Ludman PF, Tamburino C, Piazza N, Hancock J, Mehilli J, Byrne RA, Baumbach A, Kappetein AP, Windecker S, Bax J, Haude M. Standardized definitions of structural deterioration and valve failure in assessing long-term durability of transcatheter and surgical aortic bioprosthetic valves: a consensus statement from the European Association of Percutaneous Cardiovascular Interventions (EAPCI) endorsed by the European Society of Cardiology (ESC) and the European Association for Cardio-Thoracic Surgery (EACTS). *Eur J Cardiothorac Surg*. 2017;52:408-17.
133. Makkar RR, Thourani VH, Mack MJ, Kodali SK, Kapadia S, Webb JG, Yoon SH, Trento A, Svenson LG, Herrmann HC, Szeto WY, Miller DC, Satler L, Cohen DJ, Dewey TM, Babaliaros V, Williams MR, Kereiakes DJ, Zajarias A, Greason KL, Whisenant BK, Hodson RW, Brown DL, Fearon WF, Russo MJ, Pibarot P, Hahn RT, Jaber WA, Rogers E, Xu K, Wheeler J, Alu MC, Smith CR, Leon MB; PARTNER 2 Investigators. Five-Year Outcomes of Transcatheter or Surgical Aortic-Valve Replacement. *N Engl J Med*. 2020;382:799-809.
134. Gallo M, Fovino LN, Blitzer D, Doulamis IP, Guariento A, Salvador L, Tagliari AP, Ferrari E. Transcatheter aortic valve replacement for structural degeneration of previously implanted transcatheter valves (TAVR-in-TAVR): a systematic review. *Eur J Cardiothorac Surg*. 2022;61:967-76.
135. Cahill TJ, Khalique OK, George I, Kodali S. Valve thrombosis after transcatheter and surgical aortic valve replacement: Incidence and outcomes. *J Thorac Cardiovasc Surg*. 2022;163:1309-15.
136. Sorajja P, Bae R, Lesser JA, Pedersen WA. Percutaneous repair of paravalvular prosthetic regurgitation: patient selection, techniques and outcomes. *Heart*. 2015;101:665-73.
137. Ruiz CE, Hahn RT, Berrebi A, Borer JS, Cutlip DE, Fontana G, Gerosa G, Ibrahim R, Jelnin V, Jiliahawi H, Jolicoeur EM, Kliger C, Kronzon I, Leipsic J, Maisano F, Millan X, Nataf P, O'Gara PT, Pibarot P, Ramee SR, Rihal CS, Rodes-Cabau J, Sorajja P, Suri R, Swain JA, Turi ZG, Tuzcu EM, Weissman NJ, Zamorano JL,

Serruys PW, Leon MB; Paravalvular Leak Academic Research Consortium. Clinical Trial Principles and Endpoint Definitions for Paravalvular Leaks in Surgical Prosthesis. *Eur Heart J*. 2018;39:1224-45.

138. Saia F, Martinez C, Gafoor S, Singh V, Ciuca C, Hofmann I, Marrozzini C, Tan J, Webb J, Sievert H, Marzocchi A, O'Neill WW. Long-term outcomes of percutaneous paravalvular regurgitation closure after transcatheter aortic valve replacement: a multicenter experience. *JACC Cardiovasc Interv*. 2015;8:681-8.

139. Kamde SP, Anjankar A. Pathogenesis, Diagnosis, Antimicrobial Therapy, and Management of Infective Endocarditis, and Its Complications. *Cureus*. 2022;14:e29182.

140. Brankovic M, Hashemi A, Ansari J, Sharma A. Transcatheter Aortic Valve Replacement for Aortic Valve Infective Endocarditis: A Systematic Review and Call for Action. *Cardiol Ther*. 2023;12:297-306.

141. Glaser N, Jackson V, Holzmann MJ, Franco-Cereceda A, Sartipy U. Prosthetic Valve Endocarditis After Surgical Aortic Valve Replacement. *Circulation*. 2017;136:329-31.

142. Dvir D, Khan J, Kornowski R, Komatsu I, Chatriwalla A, Mackenson GB, Simonato M, Ribeiro H, Wood D, Leipsic J, Webb J, Mylotte D. Novel strategies in aortic valve-in-valve therapy including bioprosthetic valve fracture and BASILICA. *EuroIntervention*. 2018;14:AB74-82.

143. Babaliaros VC, Greenbaum AB, Khan JM, Rogers T, Wang DD, Eng MH, O'Neill WW, Paone G, Thourani VH, Lerakis S, Kim DW, Chen MY, Lederman RJ. Intentional Percutaneous Laceration of the Anterior Mitral Leaflet to Prevent Outflow Obstruction During Transcatheter Mitral Valve Replacement: First-in-Human Experience. *JACC Cardiovasc Interv*. 2017;10:798-809.

144. Arrigo M, Price S, Baran DA, Pöss J, Aissaoui N, Bayes-Genis A, Bonello L, François B, Gayat E, Gilard M, Kapur NK, Karakas M, Kostrubiec M, Leprince P, Levy B, Rosenberg Y, Thiele H, Zeymer U, Harhay MO, Mebazaa A. Optimising clinical trials in acute myocardial infarction complicated by cardiogenic shock: a statement from the 2020 Critical Care Clinical Trialists Workshop. *Lancet Respir Med*. 2021;9:1192-202.

145. van Diepen S, Morrow DA. Potential growth in cardiogenic shock research through an international registry collaboration: the merits and challenges of a Hub-of-Spokes model. *Eur Heart J Acute Cardiovasc Care*. 2021;10:3-5.

146. Johri AM, Durbin J, Newbigging J, Tanzola R, Chow R, De S, Tam J. Cardiac Point-of-Care Ultrasound: State-of-the-Art in Medical School Education. *J Am Soc Echocardiogr*. 2018;31:749-60.

147. Prastaro M, Pirozzi E, Gaibazzi N, Paolillo S, Santoro C, Savarese G, Losi MA, Esposito G, Perrone Filardi P, Trimarco B, Galderisi M. Expert Review on the Prognostic Role of Echocardiography after Acute Myocardial Infarction. *J Am Soc Echocardiogr*. 2017;30:431-43.e2.

148. Galderisi M, Nistri S, Mondillo S, Losi M-A, Innelli P, Mele D, Muraru D, D'Andrea A, Ballo P, Sgalambro A, Esposito R, Marti G, Santoro A, Agricola E, Badano LP, Marchioli R, Filardi PP, Mercurio G, Marino PN; Working Group of Echocardiography, Italian Society of Cardiology. Methodological approach for the assessment of ultrasound reproducibility of cardiac structure and function: a proposal of the study group of Echocardiography of the Italian Society of Cardiology (Ultra Cardia SIC) part I. *Cardiovasc Ultrasound*. 2011;9:26.

149. Miyazaki R, Watanabe K, Kaneko M, Nagamine S, Hara N, Nakamura T, Nagata Y, Nozato T, Ashikaga T. Acute Ischemic Mitral Regurgitation Treated by Percutaneous Coronary Intervention after an Accurate Diagnosis on Transesophageal Echocardiography. *Intern Med*. 2021;60:1417-21.

150. Steffen J, Stocker A, Scherer C, Haum M, Fischer J, Doldi PM, Theiss H, Braun D, Rizas K, Peterß S, Hausleiter J, Massberg S, Orban M, Deseive S. Emergency transcatheter aortic valve implantation for acute heart failure due to severe aortic stenosis in critically ill patients with or without cardiogenic shock. *Eur Heart J Acute Cardiovasc Care*. 2022;11:877-86.

151. Butala NM, Makkar R, Secemsky EA, Gallup D, Marquis-Gravel G, Kosinski AS, Vemulapalli S, Valle JA, Bradley SM, Chakravarty T, Yeh RW, Cohen DJ. Cerebral Embolic Protection and Outcomes of Transcatheter Aortic Valve Replacement: Results From the Transcatheter Valve Therapy Registry. *Circulation*. 2021;143:2229-40.

Supplementary data

Supplementary Table 1. CS definitions in various clinical trials.

Supplementary Table 2. Main methods for minimising radiation exposure to the foetus during interventional cardiology procedures.

The supplementary data are published online at:

<https://eurointervention.pronline.com/>

doi/10.4244/EIJ-D-23-00473



Supplementary Data

Supplementary Table 1. CS definitions in various clinical trials.

Trial/Guideline	2021 ESC Guidelines ¹¹	2020 ACVC position statement ¹⁰	SHOCK trial ¹⁸	IABP-SHOCK II ¹⁹ / CULPRIT-SHOCK ²⁰	DanGer shock ²¹	EURO-SHOCK ²²	ECLS-SHOCK ²³
Aetiology	All CS	All CS	AMI-CS	AMI-CS	AMI-CS	AMI-CS	AMI-CS
Blood pressure	No criterion	SBP<90mmHg for >30 min OR catecholamines needed to maintain SBP>90mmHg	SBP<90mmHg for >30 min OR catecholamines needed to maintain SBP>90mmHg	SBP<90mmHg for >30 min OR catecholamines needed to maintain SBP>90mmHg	SBP<100 mmHg for >30 min and/or need for vasoactive therapy	SBP<90 mmHg for >30 min OR catecholamines needed to maintain SBP>90 mmHg	SBP<90mmHg for >30 min OR catecholamines needed to maintain SBP>90 mmHg
		AND	AND	AND	AND	AND	
Haemodynamic or clinical signs of pump failure or elevated filling pressures	Inadequate cardiac output	Cardiogenic cause: - LVEF <40% - mechanical causes - RV failure - severe arrhythmia AND Elevated LV filling pressures: - pulmonary congestion - elevated PCWP - mitral E wave deceleration time ≤ 130ms - LVEDP >20 mmHg	CI<2.2L/min/m ² and PCWP>15mmHg OR pulmonary congestion on radiography in anterior MI	Clinical signs of pulmonary congestion	LVEF<45% on echocardiography	Clinical signs of pulmonary congestion	
			AND	AND	AND	AND	AND
Signs of hypoperfusion	Clinical signs of hypoperfusion: cold, sweated extremities, oliguria, mental confusion, dizziness, narrow pulse pressure Biochemical signs of hypoperfusion: elevated serum creatinine, metabolic acidosis, elevated serum lactate	Tissue hypoperfusion with at least one criterion: Altered mental status; cold, clammy skin and extremities; oliguria with a urine output < 30ml/h; arterial lactate > 2mmol/L	Impaired end-organ perfusion defined as: cold extremities or a urine output <30ml/h and a heart rate >60/min	Impaired end-organ perfusion with at least one of the following: altered mental status; cold, clammy skin and extremities; oliguria with a urine output <30ml/h; or serum lactate >2mmol/L	Signs of tissue hypoperfusion with arterial blood lactate >2.5mmol/L	Signs of impaired end-organ perfusion with at least one of the following: cold and clammy skin and limbs; altered mental status; oliguria with a urine output <30ml/h; serum lactate >2mmol/L	Signs of impaired end-organ perfusion with at least one of the following: cold, clammy skin and extremities; altered mental status; oliguria with a urine output <30ml/h AND Arterial lactate >3mmol/L

Note: All mentioned trials have included solely AMI-CS patients. Large-scale clinical trials in patients with CS due to other aetiologies are scarce.

AMI-CS acute myocardial infarction complicated by cardiogenic shock; SBP systolic blood pressure; CI cardiac index; PCWP pulmonary capillary wedge pressure; LVEF left ventricular ejection fraction.

Supplementary Table 2. Main methods for minimising radiation exposure to the foetus during interventional cardiology procedures.

▪ Collimate the X-ray beam size as tightly as possible for the clinical purpose.
▪ Keep the intensifier as close as possible to the patient (and place the source as distant as possible).
▪ Choose the direction of the primary beam so that it is as far as possible from the foetus (avoid angulated projections; anteroposterior projections are preferred).
▪ Select appropriate exposure factors.
▪ Ensure that the overall exposure time is as small as possible.
▪ Avoid the use of cineangiography whenever possible – fluoroscopy images are preferred
▪ Reduce fluoroscopy frame rate; use the lowest possible frame rates for cineangiography
▪ Experienced operators are preferred – radiation dose decreases with operator experience.
▪ Use long exchange guidewires during femoral approach to avoid direct radiation of the abdomen during manoeuvres.
▪ Use echo guidance when possible.
▪ Dose calculation by a knowledgeable medical physicist is advisable in all cases.
▪ Putting a lead apron on the table to cut down any primary beam from the X-ray tube reaching the foetus has very little effect, and it is no longer advisable. It may be used only to reassure the patient, provided the use of the apron does not compromise the performance of the procedure.