

Transcatheter aortic valve implantation with the ACURATE *neo* valve: indications, procedural aspects and clinical outcomes



Won-Keun Kim^{1,2,3*}, MD; Christian Hengstenberg⁴, MD, PhD; Michael Hilker⁵, MD, PhD; Ulrich Schäfer⁶, MD, PhD; Tanja K. Rudolph⁷, MD, PhD; Stefan Toggweiler⁸, MD, PhD; Andreas Rück⁹, MD, PhD; Lars Søndergaard¹⁰, MD, PhD; Lenard Conradi¹¹, MD, PhD; Christian Hamm^{1,3}, MD, PhD; Thomas Walther¹², MD, PhD; Helge Möllmann¹³, MD, PhD

1. Department of Cardiology, Kerckhoff Heart Center, Bad Nauheim, Germany; 2. Department of Cardiac Surgery, Kerckhoff Heart Center, Bad Nauheim, Germany; 3. Department of Cardiology, Justus-Liebig University of Giessen, Giessen, Germany; 4. Department of Medicine II, University Departments of the MedUni, Vienna, Austria; 5. Department of Cardiothoracic Surgery, University Medical Center, Regensburg, Germany; 6. Department of Cardiology, Angiology, and Intensive Care Medicine, Marienkrankenhaus, Hamburg, Germany; 7. Department of Cardiology, Herz- und Diabeteszentrum NRW, Ruhr-University Bochum, Bad Oeynhausen, Germany; 8. Heart Center Lucerne, Luzerner Kantonsspital, Lucerne, Switzerland; 9. Karolinska University Hospital, Stockholm, Sweden; 10. The Heart Center, Rigshospitalet, Copenhagen, Denmark; 11. Department of Cardiovascular Surgery, University Heart Center, University Hospital Hamburg-Eppendorf (UKE), Hamburg, Germany; 12. Department of Cardiovascular Surgery, University Heart Center, Johann-Wolfgang-Goethe University, Frankfurt, Germany; 13. Department of Cardiology, St. Johannes Hospital, Dortmund, Germany

A list of the study collaborators can be found in the Appendix paragraph.

GUEST EDITOR: Alec Vahanian, MD, PhD; Department of Cardiology, Hôpital Bichat-Claude Bernard, and University Paris VII, Paris, France

This paper also includes supplementary data published online at: <https://eurointervention.pronline.com/doi/10.4244/EIJ-D-19-00908>

KEYWORDS

- aortic stenosis
- TAVI
- training and education

Abstract

The ACURATE *neo* aortic valve system is a self-expanding transcatheter device that was granted CE mark in 2014 and has since been widely adopted in the treatment of patients with severe aortic stenosis. The ACURATE *neo* can be used in a wide clinical spectrum, but there are some specific indications and anatomies where this device is particularly suitable. Recently, it was shown that, with appropriate patient screening, size selection, and optimised positioning, results can be improved substantially. This review provides an overview of existing data and compiles a standardised manual of best practice for the implantation of this device based on both evidence and individual experience.

*Corresponding author: Department of Cardiology, Kerckhoff Heart Center, Benekestr. 2-8, 61231 Bad Nauheim, Germany.
E-mail: w.kim@kerckhoff-klinik.de

Introduction

The ACURATE *neo*TM (Boston Scientific, Marlborough, MA, USA) is a self-expanding transcatheter heart valve with a supra-annular design and porcine pericardial leaflets that has been commercially available in Europe since 2014. It is characterised by a top-down deployment, which allows precise positioning and minimises flow obstruction during deployment¹. Three stabilisation arches provide a better coaxial alignment, and the upper crown supports anchoring (**Figure 1**). The transfemoral delivery system incorporates two knobs in the handle that can be turned to deploy the device in two steps. The smallest diameter of the delivery system is 15 Fr, increasing to 18 Fr at the site of the valve attachment. The ACURATE *neo* valve can be implanted via either transvascular or transapical access routes and has a dedicated transapical delivery system. Since CE-mark approval in 2014, it has been widely adopted in Europe, Canada, South America, and the Asia-Pacific region. A recent study illustrated that results are considerably subject to appropriate patient screening, size selection, and optimised positioning².

The purpose of this manuscript is to review the growing amount of clinical data on the ACURATE *neo* and to present a sophisticated approach for sizing and patient selection by highlighting suitable anatomies and indications. Moreover, we aim to provide a best practice manual going through each procedural step of transfemoral implantation based on insights from experienced operators.

Clinical data

CE-MARK STUDY

This prospective series included the first 89 patients who were implanted with the ACURATE *neo* prosthesis (age 83.7±4.4 years; logistic EuroSCORE 26.5±7.7%)³. Procedural success was 94.4%. At 30 days, all-cause mortality was 3.4%, the rate of moderate para-valvular leakage (PVL) was 4.5%, major stroke occurred in 2.2%, and the frequency of permanent pacemaker implantation (PPI) was 10.3%.

SAVI TF REGISTRY

The purpose of this prospective, international registry was to demonstrate the efficacy and safety of the ACURATE *neo* in a real-world setting⁴. A total of 1,000 patients from 25 centres (age 81.1±5.2 years; STS score 6.0±5.6%) were included. Procedural success was obtained in 98.7%, mean gradient was 8.4±4.0 mmHg, and more-than-mild PVL 4.1%. At 30 days, all-cause mortality was 1.4%, PPI occurred in 8.3%, and there was no case of coronary obstruction requiring intervention.

MORENA

Data from three high-volume centres in Germany were merged for a comparison of the ACURATE *neo* and the balloon-expandable SAPIEN 3 (Edwards Lifesciences, Irvine, CA, USA)⁵. From a total of 1,121 patients, a matched cohort of patients (SAPIEN 3, n=622; ACURATE *neo*, n=311) was identified. Rates of in-hospital complications were similar between the groups, including major stroke, major vascular complications, and life-threatening bleeding. Thirty-day mortality (2.3% vs 1.9%; p=0.74) and overall device failure were similar (10.9% vs 9.6%; odds ratio: 1.09; p=0.71) between the groups, with increased rates of more-than-mild PVL (4.8% vs 1.8%; p=0.01), but less elevated gradients (3.2% vs 6.9%; p=0.02) and less frequent PPI (9.9% vs 15.5%; p=0.02) in the ACURATE *neo* group.

SCOPE I

In this randomised trial, the ACURATE *neo* was compared with the balloon-expandable SAPIEN 3 system for transfemoral TAVI in patients with severe aortic stenosis⁶. A total of 739 patients from 20 European centres (age 82.8±4.1 years; STS score 3.5%) were enrolled. At 30 days, the primary composite endpoint (all-cause death, any stroke, life-threatening or disabling bleeding, major vascular complications, coronary artery obstruction requiring intervention, acute kidney injury [stage 2 or 3], rehospitalisation for valve-related symptoms or congestive heart failure,

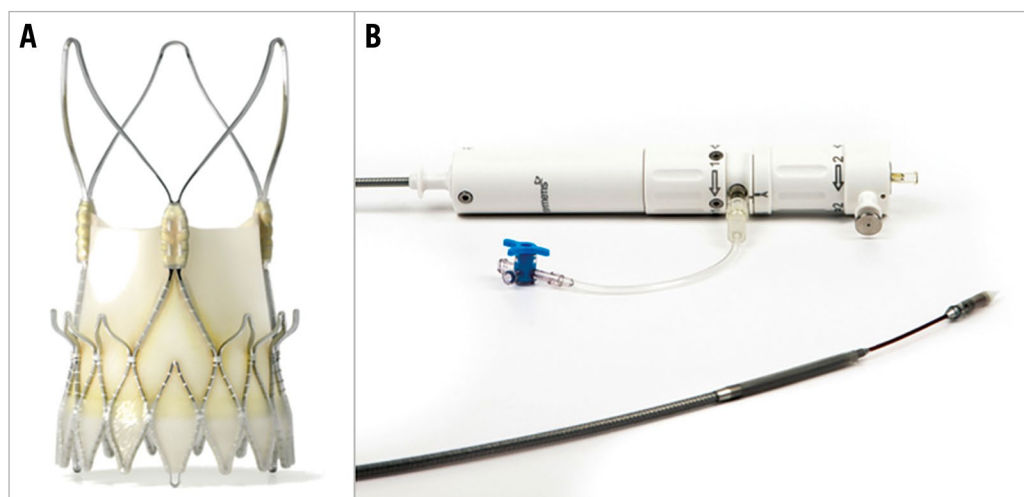


Figure 1. ACURATE *neo* transcatheter heart valve system. The ACURATE *neo* prosthesis (A) and delivery system (B).

valve-related dysfunction requiring repeat procedure, moderate or severe prosthetic valve regurgitation, or prosthetic valve stenosis) occurred in 24% in the ACURATE *neo* group and in 16% in the SAPIEN 3 group; thus, non-inferiority of the ACURATE *neo* was not met (absolute risk difference 7.1% [upper 95% confidence limit 12.0%], $p=0.42$), and the secondary analysis suggested superiority of the SAPIEN 3 THV over the ACURATE *neo* device (95% CI for risk difference -1.3 to -12.9 , $p=0.0156$). While all-cause mortality and stroke rates were similar, more-than-mild PVL was more frequent in the ACURATE *neo* group (9% vs 3%).

NEOPRO REGISTRY

In this multicentre observational registry, 1,551 patients (mean age 82 years, STS score 5.1%) who underwent transfemoral TAVI with either the ACURATE *neo* ($n=1,263$) or the Evolut™ PRO ($n=288$) valve (Medtronic, Minneapolis, MN, USA) were included. After propensity score matching, device success (86.9% vs 89.0%, $p=0.48$), more-than-mild PVL (10.9% vs 8.5%, $p=0.37$), 30-day mortality (3.2% vs 1.2%, $p=0.13$), 30-day stroke (2.4% vs 2.8%, $p=0.79$), 30-day VARC-2 early safety endpoint (10.6% vs 10.4%, $p=0.96$), and new PPI (12.8% vs 11.9%, $p=0.55$) were similar between the groups⁷.

COMPARISON OF NEW-GENERATION DEVICES

A total of 346 patients (age 81.4 ± 5.2 years; STS PROM $4.0\pm 2.5\%$) from a single centre treated with a new-generation THV (SAPIEN 3 $n=134$; Evolut™ R [Medtronic] $n=111$, ACURATE *neo* $n=101$) were compared against each other. At 30 days, all-cause mortality was similar between groups, whereas rates of PVL and PPI and mean gradients differed significantly (SAPIEN 3 vs Evolut R vs ACURATE *neo*: more-than-trace PVL 18.8% vs 47.9% vs 45.8%, $p<0.05$; PPI 8.3% vs 16.7% vs 2.1%, $p<0.05$; p_{mean} 9.7 ± 7.5 mmHg vs 6.1 ± 2.4 mmHg vs 8.4 ± 3.5 mmHg, $p<0.01$). At one year, MACCE rates were similar among all groups⁸.

SMALL AORTIC ANNULI

In this multicentre study, a total of 92 matched pairs of patients with an aortic annulus area below 400 mm² undergoing TAVI with either the supra-annular ACURATE *neo* or the intra-annular SAPIEN 3 prosthesis were studied⁹. The ACURATE *neo* provided a larger indexed effective orifice area (EOA) (0.96 cm²/m² vs 0.80 cm²/m²; $p<0.001$) and lower rates of severe patient-prosthesis mismatch (PPM) (3% vs 22%; $p<0.001$) as well as lower mean transvalvular gradients (9.3 mmHg vs 14.5 mmHg; $p<0.001$). These haemodynamic findings were sustained at one-year follow-up. Mortality at 30 days and one year, and in-hospital rates of stroke, PPI rate, as well as more-than-mild PVL were similar for the two THV systems.

PERMANENT PACEMAKER IMPLANTATION

In a small study that included 175 patients (83±6 years, STS score $4.1\pm 2.4\%$) from three centres, the PPI rate using the ACURATE *neo* was as low as 2.5% in pacemaker-naïve patients¹⁰. The authors

concluded that a less aggressive predilatation to minimise mechanical trauma to the conduction system, periprocedural avoidance of negative dromotropic drugs, and conservative indication for a new PPI may be strategies that help to achieve a low PPI rate.

SELECT RBBB

This recent multicentre study included 296 patients without previous pacemaker and pre-existing right bundle branch block from seven centres undergoing TAVI using either the ACURATE *neo* ($n=98$) or the SAPIEN 3 device ($n=198$). The 30-day PPI rate was lower when using the ACURATE *neo* (29.6% vs 43.9%; $p=0.025$; OR 0.54, 95% CI: 0.32-0.89; $p=0.018$). There was no difference in device failure (8.2% vs 6.6%; $p=0.792$)¹¹.

PREDICTORS OF PVL

In a comprehensive analysis of anatomical and procedure-related factors of PVL in 500 patients (82.1 years; STS score 4.4%) undergoing transfemoral TAVI with the ACURATE *neo* in a single centre, more-than-mild PVL was more frequent with increasing device landing zone calcification (mild 0.8% vs moderate 5.0% vs severe 13.0%; $p<0.001$). The degree of peri-annular calcification, oversizing, presence of annular plaque protrusions, inappropriate positioning, and the sinotubular junction height were identified as independent predictors of more-than-mild PVL. When comparing the first 100 with the last 100 ACURATE *neo* cases performed in this centre, more-than-mild PVL decreased from 11% to 3% ($p=0.03$), an observation that was attributed to increased oversizing, selection of patients with less calcified aortic valve calcification, and improved positioning².

BALLOON PREDILATATION

Given the comparably moderate radial force of the ACURATE *neo*, an effective balloon predilatation is mandatory. However, the feasibility and safety of direct implantation without predilatation were demonstrated in a single-centre series of selected patients with mild aortic valve calcification. From a total of 294 patients, 72 (24%) cases were performed without predilatation (82.7 years, STS score 4.6%). Device success (VARC-2) was achieved in 94.4%, post-dilatation was necessary in 26.4%, and one (1.4%) patient had moderate PVL. A propensity-matched comparison of patients with versus without predilatation showed that there were no differences regarding device success, more-than-mild PVL, post-dilatation, and post-procedural mean gradients, but procedure and fluoroscopy times were significantly decreased in the group without predilatation¹².

PURE AORTIC REGURGITATION

The frame of the ACURATE *neo* has an X-shaped design with the upper crown being 5 mm larger than the nominal THV diameter at the waist. This may help to anchor the prosthesis and prevent embolisation into the left ventricle even in the absence of calcification. The current evidence is scarce, but a small series of 20 patients with pure aortic regurgitation showed favourable haemodynamic outcomes¹³. This study demonstrated that,

due to the absence of calcification, more oversizing may be required compared to patients with aortic stenosis. The maximum mean diameter that was treated with the largest available size (ACURATE *neo* L, 27 mm) in the published series was 25 mm. Furthermore, to minimise the risk of ventricular embolisation, the initial positioning may be slightly higher than for the implantation in aortic stenosis, and rapid pacing may be used to enhance stability during deployment.

BICUSPID AORTIC VALVE

In a multicentre registry, among 712 patients who were treated with the ACURATE *neo* THV, a bicuspid aortic valve (BAV) was identified in 54 (7.5%) cases¹⁴. In comparison to patients with tricuspid anatomy (n=658; 92.4%), the presence of BAV was associated with more frequent post-dilatation (57.4% vs 38.7%, p=0.007), more-than-mild PVL (7.4% vs 3.2%, p<0.001), and major stroke (7.4% vs 1.8%, p=0.001). After propensity score matching, the rate of post-dilatation remained higher in the BAV group, whereas more-than-mild PVL and major stroke were similar between groups.

In summary, a growing body of evidence demonstrates the feasibility and safety of using the ACURATE *neo* for approved indications, but also in off-label situations. The X-shaped design allows an optimal distribution of the relatively moderate radial force (**Figure 2**), which translates into a balanced profile of this valve with a low risk of annular rupture, coronary obstruction, and conduction disturbances whilst having an acceptable rate of more-than-mild PVL in most series. However, the unusually high frequency of more-than-mild PVL of 9% in the recent SCOPE I trial is inconsistent with previous data and requires further clarification,

before a final recommendation regarding differential device selection can be made. These inconsistencies may be ascribed to the absent core laboratory adjudication in the vast majority of studies and different populations that were examined, but may also reflect the versatility of results that are markedly subject to appropriate patient selection, sizing, and positioning².

There are several ongoing clinical studies that may corroborate existing data and fill knowledge gaps. Among these, the SCOPE II randomised trials for head-to-head comparisons of the ACURATE *neo* with the Evolut R/PRO platform, respectively, and the PROGRESS PVL registry for intra-individual, longitudinal assessment of the degree of PVL, should be mentioned. Enrolment has been completed recently for these studies and initial results will be available soon.

Patient selection

The ACURATE *neo* can be used in a wide clinical spectrum of patients, but there are some potential indications and anatomies where this device may be particularly suitable. **Supplementary Table 1** provides an overview of the differential selection among commonly used TAVI prostheses.

SHORT CORONARY DISTANCE

The risk of coronary obstruction is relatively low since the upper crown keeps the native cusps away from the coronary ostia (**Moving image 1**). Accordingly, in the SAVI TF registry among 1,000 patients no case of coronary obstruction requiring intervention occurred⁴. Moreover, coronary re-access may be less challenging due to the short stent body and the open-cell design of the upper crown (**Supplementary Figure 1**).

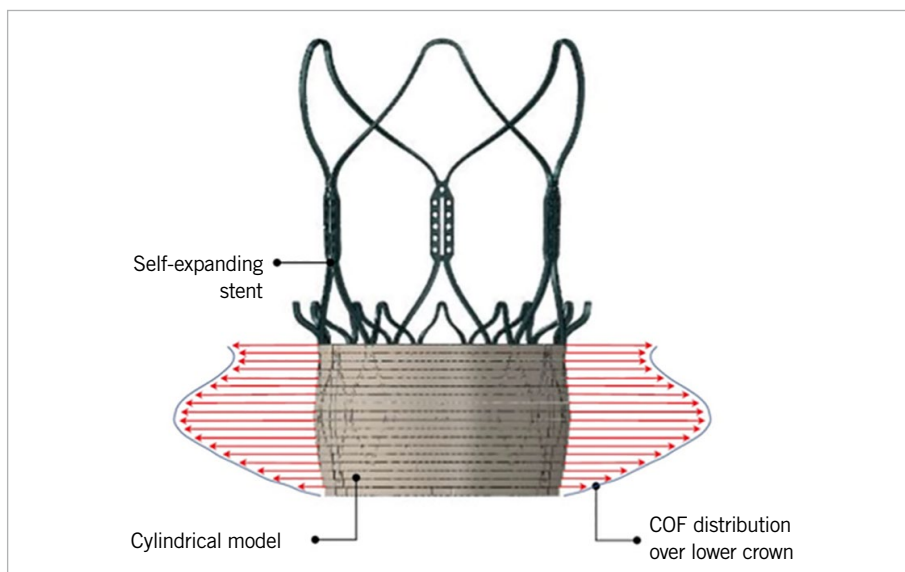


Figure 2. Radial force of the ACURATE *neo*. Distribution of the radial force (chronic outward force [COF]) over the height of the lower crown in contact with a cylindrical and compliant annulus model as estimated with the finite element method. The maximum force is located at approximately the mid height of the stent body.

SMALL AORTIC ANNULUS

The supra-annular design of the ACURATE *neo* translates into low mean transvalvular gradients, which may be of particular benefit for patients with small annuli to reduce the risk of PPM⁹.

HORIZONTAL AORTA AND TORTUOUS ANATOMIES

In horizontal aortic configurations, the short stent frame and the stabilisation arches provide a better coaxial alignment and thereby facilitate the deployment of the ACURATE *neo*. The flexible delivery system allows a smooth tracking of tortuous anatomies (**Moving image 2, Moving image 3**).

LOW PACEMAKER RATE

The rate of PPI is among the lowest for the ACURATE *neo*^{8,10,11}, which may be attributed to the specific distribution of the moderate radial force (**Figure 2**) and less protrusion into the left ventricular outflow tract. However, recent data are not consistent and require further investigation⁶.

GENTLE PROCEDURE

The top-down release of the ACURATE *neo* without any need for rapid ventricular pacing allows haemodynamic stability throughout the entire implantation, as no outflow obstruction occurs during valve deployment. This may be beneficial in cases with impaired ventricular function or severe heart failure, particularly in cases where no predilatation and no post-dilatation are required¹².

SEVERE AORTIC VALVE CALCIFICATION

As a caveat, due to its lower radial force, the ACURATE *neo* may be less appropriate in severe aortic valve calcification, where its use can result in higher rates of more-than-mild PVL and more frequent need for balloon post-dilatation². However, **Supplementary Figure 2** illustrates that the degree of PVL in severe aortic valve calcification depends not only on the total amount of aortic valve calcium, but also on its distribution.

BICUSPID AORTIC VALVE

The use of the ACURATE *neo* in bicuspid anatomies is feasible¹⁴. However, in the setting of very severe aortic valve calcification or asymmetric distribution, the use in bicuspid aortic valves may have an increased risk of device failure.

Sizing

The original sizing recommendation was adopted from the experience with the ACURATE TA bioprosthesis, which in fact differs from the ACURATE *neo* in many respects. Particularly in cases with borderline annulus dimensions, strict adherence to the official sizing chart may lead to relative undersizing. **Supplementary Table 2** shows a modified sizing recommendation that was derived from a large, single-centre cohort to discriminate the risk of more-than-mild PVL². In contrast to the official recommendation, annulus sizes below 21 mm can be treated without concern to a minimum of 19 mm, whereas the maximum size of 27 mm should not be exceeded, bearing in mind that the risk of residual PVL increases above an annulus size of 26.5 mm.

Procedural steps

A comprehensive overview of all relevant procedural steps for the implantation of the ACURATE *neo* is provided in **Table 1, Moving image 4-Moving image 8, Figure 3-Figure 5** and **Supplementary Figure 3-Supplementary Figure 5**. Throughout the procedure, proper device positioning is key to achieving good results; once correctly positioned, upon full release the prosthesis will commonly stay within the intended landing zone due to predominant lateral extension and only minimal vertical motion.

Perspectives

1. The next-generation ACURATE *neo2*TM aortic valve system (Boston Scientific) has a dedicated sealing skirt that is designed to reduce PVL further, especially in the setting of heavily calcified annuli; the new system underwent initial clinical testing in 2018.

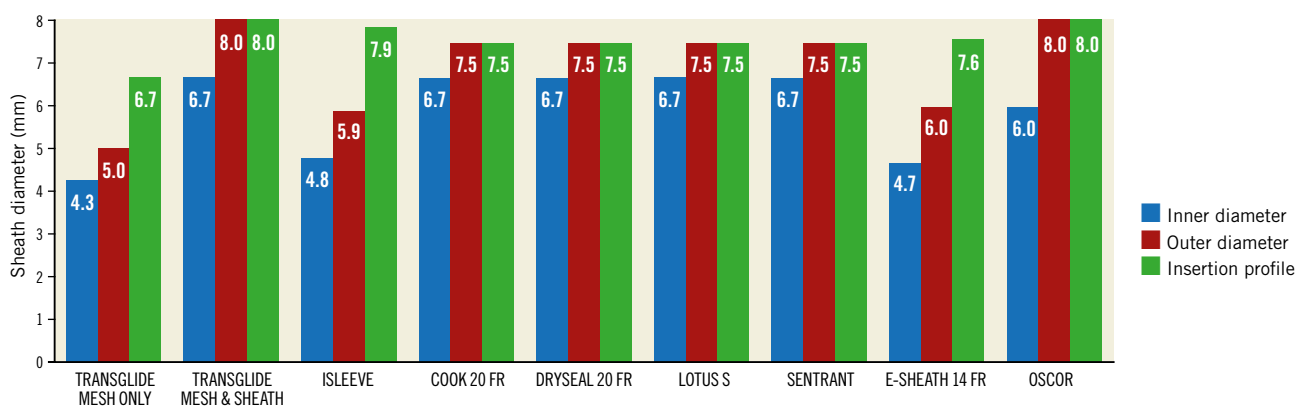


Figure 3. Introducer sheaths. The ACURATE *neo* system is compatible with various introducer sheaths that have different inner diameters, outer diameters, and insertion profiles.

Table 1. Procedural steps.

Introducer sheath	Various different sheaths are compatible for femoral access using the ACURATE <i>neo</i> system (Figure 3). Recently, the expandable iSLEEVE™ (Boston Scientific) introducer sheath with a 14 Fr inner diameter at the tip has become available (Supplementary Figure 3). The lowest possible insertion profile can be achieved when using only the mesh of the Transglide® expandable introducer system (TransAortic Medical, Morgan Hill, CA, USA), which comes close to a sheathless approach ¹⁵ , but is currently for off-label use only.
Co-planar view	In contrast to other self-expanding devices that follow the alignment of the prosthesis, the implantation of the ACURATE <i>neo</i> requires a co-planar view on the native annular plane.
Predilatation	Due to the moderate opening force of the ACURATE <i>neo</i> , effective balloon predilatation is mandatory to facilitate device expansion. While according to the manufacturer a relatively aggressive predilatation is recommended, a less aggressive approach (balloon size approximately 2 mm smaller than the perimeter-derived annulus diameter) may decrease the risk of conduction disturbances ¹⁰ .
Positioning and deployment	A proper position is indicated by the radiopaque intersection line (referred to as “marker band”) located in the mid portion of the stent body, being in the annular plane. In addition, the upper crown should be located right above the tips of the native leaflets (Figure 4). It is of utmost importance that the final movement for positioning is in a forward motion. When the final motion of the delivery system is in the aortic direction, upon full release the stent holder will move in an aortic direction and may not disengage from the prosthesis. When a good initial position has been achieved, the first step can be initiated by turning knob 1 counter-clockwise, which will release the upper crown and the stabilisation arches (Figure 5A). This should be done rather slowly in order to recognise any inappropriate movement of the device promptly. Depending on the wire position, vascular tortuosity, aortic valve calcification, and the amount of push exerted during this step, there will usually be an upward movement. In this situation, the first operator should try to maintain the position by slightly increasing the pressure on the delivery system. Moving image 4 shows an example of maintaining an appropriate forward tension during step 2. However, excessive push on the delivery system should be avoided (Moving image 5). Particularly in mildly calcified aortic valves, the device tends to dive into the left ventricle. If this occurs, the deployment should be stopped immediately to adjust the position. After release of the upper crown, the prosthesis cannot be re-sheathed. However, even after completing step 1, it is still possible to adjust the position. When a proper device position has been verified, knob 2 can be turned counter-clockwise (Figure 5B), which will release the lower crown for full deployment of the valve (Figure 5C).
Retrieval of the delivery system	After completing step 2, a complete disengagement of the prosthesis from the stent holder should be ascertained. Ideally, the latter shows a slight movement into the left ventricle, leaving space between the stent body and the radiopaque stent holder (Figure 5D). If the stent holder moves in the aortic direction, the delivery system should be carefully advanced into the left ventricle to disengage the prosthesis from the stent holder. Retrieval of the delivery system out of the left ventricle should be done with minimal interaction with the prosthesis by adjusting the guidewire position (Figure 5E). In the descending aorta, the delivery system must be closed by first turning knob 2 clockwise until the hard stop, and then turning knob 1 clockwise until there is a slight contact between the shuttle and the stent holder. It is important not to turn knob 1 until the hard stop, otherwise there is a risk of over-closing, with the capsule “riding” on the nose cone, and retrieval out of the sheath may become difficult.
Evaluation of the result	For aortography, the pigtail catheter should be placed just above the stent posts using a sufficient amount and speed of contrast agent (20-25 ml, 20 ml/s), otherwise paravalvular leakage might be underestimated. Importantly, unless the operator is not satisfied with the result and post-dilatation might become necessary, it is recommended to retain access to the left ventricle, as the re-crossing of the prosthesis can be challenging and bears the risk of re-crossing through one of the stabilisation arches, which may result in valve migration during retrieval of the balloon catheter (Moving image 6). In the event of re-crossing, the correct transprosthetic wire position should be verified carefully (Moving image 7, Moving image 8). In case of a suboptimal result despite favourable anatomy and proper device position, it is justified to wait for a few minutes, as the nitinol can expand further (Supplementary Figure 4).
Post-dilatation	For post-dilatation, the balloon should be placed in the mid part of the stent body (Supplementary Figure 5). The balloon size should not exceed that of the prosthesis minus 1 mm (ACURATE <i>neo</i> S: max. 22 mm balloon, M: max. 24 mm balloon, L: max 26 mm balloon) to minimise the risk of leaflet damage.

- Implantation of the current version of the ACURATE *neo* is generally perceived as easy and intuitive. Less experienced operators would nonetheless be even more confident if valve repositioning or retrieval were possible.
- The current version officially covers an annular size range from 21 to 27 mm. The smallest size is most probably also suitable for smaller annuli in an off-label fashion, whereas annuli >27 mm cannot be treated. Therefore, additional valve sizes, particularly for annulus dimensions above 27 mm,

would further expand the spectrum of patients who can be treated with this device.

- Further clinical data, especially from randomised trials, are awaited, as outlined above. This holds true especially for the evolving field of intermediate- to low-risk patients, since this subgroup was not enrolled in the initial ACURATE *neo* trials. Moreover, additional data will be important to clarify inconsistencies that were introduced by the most recent SCOPE I trial.

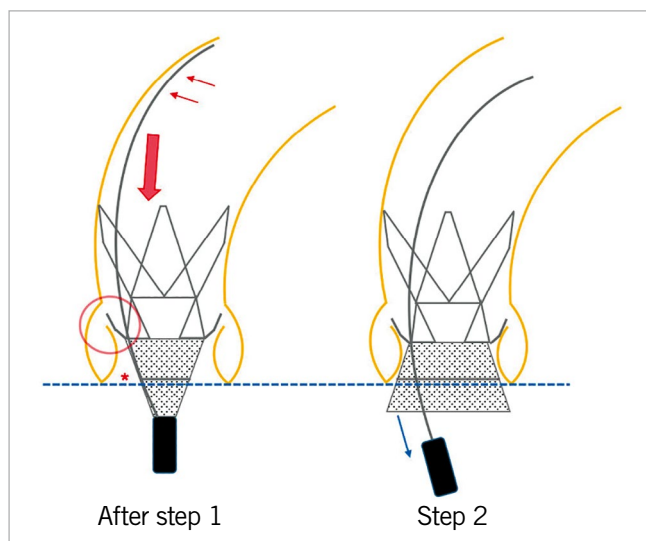


Figure 4. Positioning. The delivery system should be kept in the outer curvature (small red arrows) for enhanced stability during positioning. A proper device position is accomplished when the radiopaque intersection line (asterisk) is at the level of the annulus (dotted blue line), and the upper crown is in close proximity to the native leaflets (red circle). During step 2, an appropriate amount of forward tension should be maintained (large red arrow), trying to avoid too much (active) push on the device that might lead to ventricular embolisation.

Conclusions

The worldwide increasing use of the ACURATE *neo* system is endorsed by a growing body of evidence. The optimal distribution of the relatively moderate radial force and its unique principle of deployment account for its notably balanced profile. Importantly, careful patient selection, proper sizing, and appropriate positioning are premises for optimised outcomes.

Appendix. Study collaborators

Mirko Doss, MD, PhD; Department of Cardiac Surgery, Kerckhoff Heart Center, Bad Nauheim, Germany. Andreas Holzamer, MD; Department of Cardiothoracic Surgery, University Medical Center, Regensburg, Germany. Oliver Husser, MD, PhD; Department of Cardiology, St. Johannes Hospital, Dortmund, Germany. Cindy Belon; Boston Scientific, Ecublens, Switzerland. Stefane Delaloye, PhD; Boston Scientific, Ecublens, Switzerland.

Guest Editor

This paper was guest edited by Alec Vahanian, MD, PhD; Department of Cardiology, Hôpital Bichat-Claude Bernard, and University Paris VII, Paris, France.

Acknowledgements

We are grateful for the help of Elizabeth Martinson, PhD, of the KHFI Editorial Office, in preparing the manuscript.

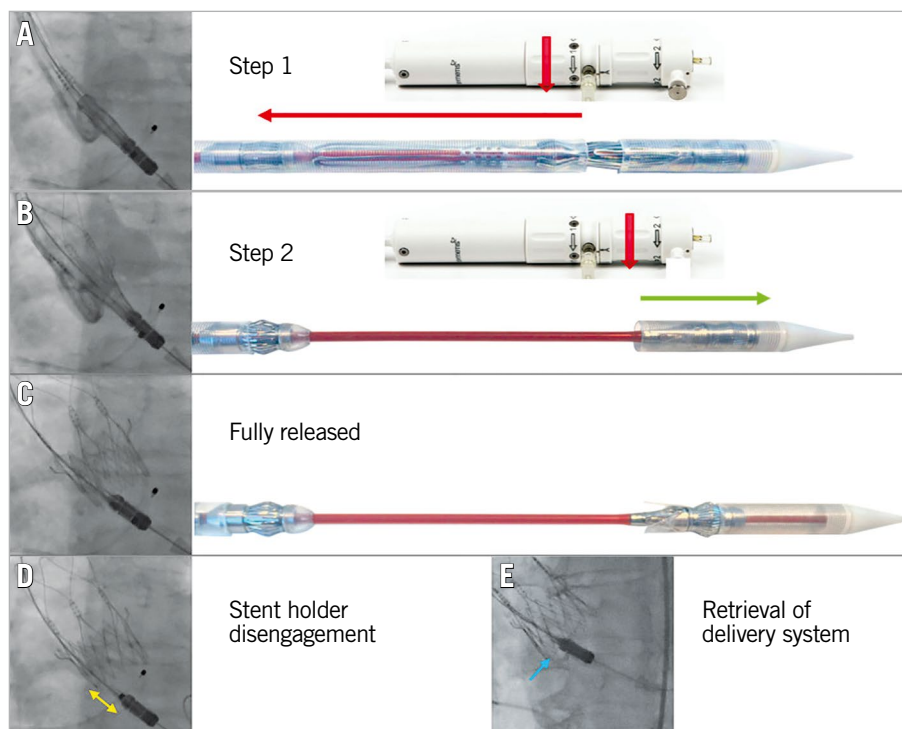


Figure 5. Deployment. After initial positioning of the prosthesis (A), turning the first rotation knob counter-clockwise releases the upper crown and the stabilisation arches (step 1). Thereafter, turning the second rotation knob counter-clockwise for step 2 (B) fully releases the prosthesis (C). D) Complete disengagement of the stent holder from the prosthesis (yellow double arrow). For retrieval of the delivery system out of the left ventricle, the guidewire should be pulled until the nose cone centralises (E).

Conflict of interest statement

W. Kim declares proctor fees from Boston Scientific and Abbott, and speaker fees from Boston Scientific, Abbott, Medtronic, and Edwards Lifesciences. C. Hengstenberg declares proctor and speaker fees from Boston Scientific. M. Hilker declares proctor and speaker fees from Boston Scientific. U. Schäfer is a consultant and proctor for, and is on the speaker's bureau for Abbott Vascular, Boston Scientific, Edwards Lifesciences, Medtronic, Gore, JenaValve, and New Valve Technology, and has received research grants from Abbott Vascular, Boston Scientific, JenaValve, Edwards Lifesciences, and New Valve Technology. T. Rudolph is a proctor and/or has received speaker honoraria from Boston Scientific, JenaValve, Edwards, Medtronic, and Abbott. S. Toggweiler is a proctor and consultant for and/or has received speaker honoraria from Boston Scientific, New Valve Technology, Edwards Lifesciences and Medtronic, and has received a research grant from Boston Scientific. A. Rück declares being a proctor for Boston Scientific. O. Husser has received proctor fees from Boston Scientific. A. Holzamer has received proctor fees from Boston Scientific. L. Conradi declares being a proctor for Boston Scientific. M. Doss has received proctor fees and/or speaker honoraria from Boston Scientific, and Abbott. H. Möllmann has received proctor fees and/or speaker honoraria from Boston Scientific, Abbott, Biotronik, and Edwards Lifesciences. L. Søndergaard has received consultant fees and institutional research grants from Boston Scientific. C. Hamm reports being on the advisory board of Medtronic. C. Belon is an employee of Boston Scientific. S. Delaloye is an employee of Boston Scientific. The other author has no conflicts of interest to declare. The Guest Editor is a consultant for Edwards Lifesciences.

References

- Möllmann H, Diemert P, Grube E, Baldus S, Kempfert J, Abizaid A. Symetis ACURATE TF™ aortic bioprosthesis. *EuroIntervention*. 2013;9 Suppl:S107-10.
- Kim WK, Möllmann H, Liebetau C, Renker M, Rolf A, Simon P, Van Linden A, Arsalan M, Doss M, Hamm CW, Walther T. The ACURATE neo Transcatheter Heart Valve: A Comprehensive Analysis of Predictors of Procedural Outcome. *JACC Cardiovasc Interv*. 2018;11:1721-9.
- Möllmann H, Walther T, Siqueira D, Diemert P, Treede H, Grube E, Nickenig G, Baldus S, Rudolph T, Kuratani T, Sawa Y, Kempfert J, Kim WK, Abizaid A. Transfemoral TAVI using the self-expanding ACURATE neo prosthesis: one-year outcomes of the multicentre "CE-approval cohort". *EuroIntervention*. 2017;13:e1040-6.
- Möllmann H, Hengstenberg C, Hilker M, Kerber S, Schäfer U, Rudolph T, Linke A, Franz N, Kuntze T, Nef H, Kappert U, Walther T, Zembala MO, Toggweiler S, Kim WK. Real-world experience using the ACURATE neo prosthesis: 30-day outcomes of 1,000 patients enrolled in the SAVI TF registry. *EuroIntervention*. 2018;13:e1764-70.
- Husser O, Kim WK, Pellegrini C, Holzamer A, Walther T, Mayr PN, Joner M, Kasel AM, Trenkwalder T, Michel J, Rheude T, Kastrati A, Schunkert H, Burgdorf C, Hilker M, Möllmann H, Hengstenberg C. Multicenter Comparison of Novel Self-Expanding Versus Balloon-Expandable Transcatheter Heart Valves. *JACC Cardiovasc Interv*. 2017;10:2078-87.
- Lanz J, Kim WK, Walther T, Burgdorf C, Möllmann H, Linke A, Redwood S, Thilo C, Hilker M, Joner M, Thiele H, Conzelmann L, Conradi L, Kerber S, Schymik G, Prendergast B, Husser O, Stortecky S, Heg D, Jüni P, Windecker S, Pilgrim T, SCOPE I investigators. Safety and efficacy of a self-expanding versus a balloon-expandable bioprosthesis for transcatheter aortic valve replacement in patients with symptomatic severe aortic stenosis: a randomised non-inferiority trial. *Lancet*. 2019;394:1619-28.
- Pagnesi M, Kim WK, Conradi L, Barbanti M, Stefanini GG, Zeus T, Pilgrim T, Schofer J, Zweiker D, Testa L, Taramasso M, Hildick-Smith D, Abizaid A, Wolf A, Van Mieghem NM, Sedaghat A, Wöhrle J, Khogali S, Van der Heyden JAS, Webb JG, Estévez-Loureiro R, Mylotte D, MacCarthy P, Brugaletta S, Hamm CW, Bhadra OD, Schafer U, Costa G, Tamburino C, Cannata F, Reimers B, Veulemans V, Asami M, Windecker S, Eitan A, Schmidt A, Bianchi G, Bedogni F, Saccocci M, Maisano F, Alsanjari O, Siqueira D, Jensen CJ, Naber CK, Ziviello F, Sinning JM, Seeger J, Rottbauer W, Brouwer J, Alenezi A, Wood DA, Tzalamouras V, Regueiro A, Colombo A, Latib A. Transcatheter Aortic Valve Replacement With Next-Generation Self-Expanding Devices: A Multicenter, Retrospective, Propensity-Matched Comparison of Evolut PRO Versus Acurate neo Transcatheter Heart Valves. *JACC Cardiovasc Interv*. 2019;12:433-43.
- Costa G, Buccheri S, Barbanti M, Picci A, Todaro D, Di Simone E, La Spina K, D'Arrigo P, Criscione E, Nastasi M, Sgroi C, Tamburino C. Outcomes of three different new generation transcatheter aortic valve prostheses. *Catheter Cardiovasc Interv*. 2020;95:398-407.
- Mauri V, Kim WK, Abumayyaleh M, Walther T, Moellmann H, Schaefer U, Conradi L, Hengstenberg C, Hilker M, Wahlers T, Baldus S, Rudolph V, Madershahian N, Rudolph TK. Short-Term Outcome and Hemodynamic Performance of Next-Generation Self-Expanding Versus Balloon-Expandable Transcatheter Aortic Valves in Patients With Small Aortic Annulus: A Multicenter Propensity-Matched Comparison. *Circ Cardiovasc Interv*. 2017 Oct;10(10).
- Toggweiler S, Nissen H, Mogensen B, Cuculi F, Fallesen C, Veien KT, Brinkert M, Kobza R, Rück A. Very low pacemaker rate following ACURATE neo transcatheter heart valve implantation. *EuroIntervention*. 2017;13:1273-80.
- Husser O, Pellegrini C, Kim WK, Holzamer A, Pilgrim T, Toggweiler S, Schäfer U, Blumenstein J, Deuschl F, Rheude T, Joner M, Hilker M, Hengstenberg C, Mollmann H. Transcatheter Valve SELECTION in Patients With Right Bundle Branch Block and Impact on Pacemaker Implantations. *JACC Cardiovasc Interv*. 2019;12:1781-93.
- Kim WK, Liebetau C, Renker M, Rolf A, Van Linden A, Arsalan M, Husser O, Möllmann H, Hamm C, Walther T. Transfemoral aortic valve implantation using a self-expanding transcatheter heart valve without pre-dilatation. *Int J Cardiol*. 2017;243:156-60.
- Toggweiler S, Cerillo AG, Kim WK, Biaggi P, Lloyd C, Hilker M, Almagor Y, Cuculi F, Brinkert M, Kobza R, Muller O, Rück A, Corti R. Transfemoral Implantation of the Acurate neo for the Treatment of Aortic Regurgitation. *J Invasive Cardiol*. 2018;30:329-33.
- Mangieri A, Chieffo A, Kim WK, Stefanini GG, Rescigno G, Barbanti M, Tamburino C, Rück A, Pagnesi M, Linder R, Toggweiler S, Montorfano M, Colombo A. Transcatheter aortic valve implantation using the ACURATE neo in bicuspid and tricuspid aortic valve stenosis: a propensity-matched analysis of a European experience. *EuroIntervention*. 2018;14:e1269-75.
- Kim WK, Brinkert M, Mangner N, Gatto F, Husser O, Renker M, Liebetau C, Gasior T, Doss M, Walther T, Hamm C, Linke A, Toggweiler S, Mollmann H. Transfemoral implantation of the ACURATE neo prosthesis using a low-profile expandable introducer system: A multicenter registry. *Int J Cardiol*. 2019;281:76-81.

Supplementary data

Supplementary Figure 1. Coronary re-access.

Supplementary Figure 2. Severe aortic valve calcification.

Supplementary Figure 3. iSLEEVE expandable introducer set.

Supplementary Figure 4. *In vivo* expansion of the ACURATE *neo*.

Supplementary Figure 5. Post-dilatation.

Supplementary Table 1. Differential selection of transcatheter heart valves.

Supplementary Table 2. Sizing recommendation (modified according to Kim et al² with permission).

Moving image 1. The upper crown keeps the native calcified cusp away from the left main ostium.

Moving image 2. Severe aortic tortuosity and horizontal aorta.

Moving image 3. Smooth advancement of the ACURATE delivery system through the tortuous aorta and across the aortic arch.

Moving image 4. Appropriate forward pressure on the delivery system during step 2.

Moving image 5. Inappropriate push on the delivery system leading to ventricular embolisation.

Moving image 6. Aortic migration of the prosthesis during balloon retrieval after re-crossing through one of the stabilisation arches.

Moving image 7. After re-crossing of the prosthesis, wire manipulation reveals a slight inward bending of the adjacent stabilisation arch.

Moving image 8. Correct re-crossing of the prosthesis.

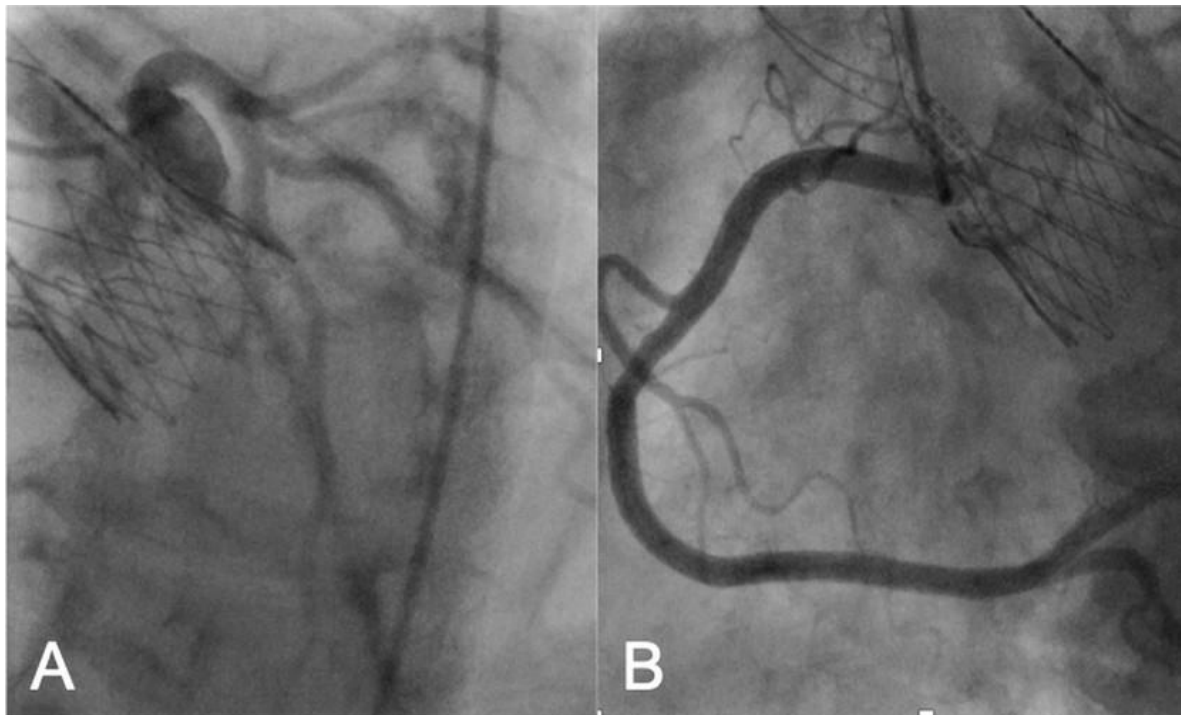
The supplementary data are published online at:

<https://eurointervention.pconline.com/>

[doi/10.4244/EIJ-D-19-00908](https://doi.org/10.4244/EIJ-D-19-00908)

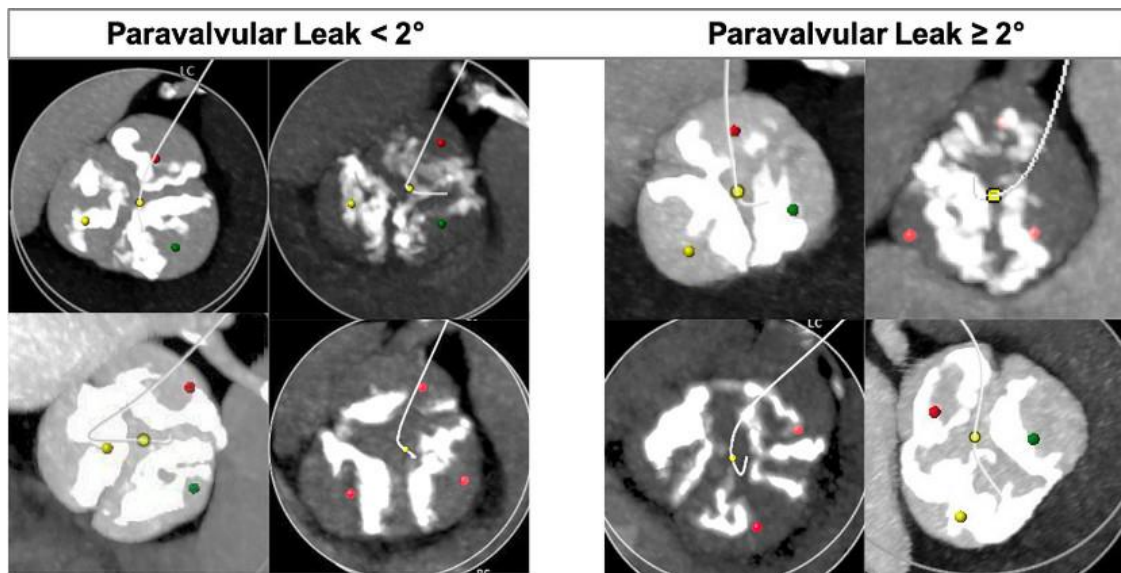


Supplementary data



Supplementary Figure 1. Coronary re-access.

Engagement of the left main (A) and the right coronary artery (B) for coronary angiography.



Supplementary Figure 2. Severe aortic valve calcification.

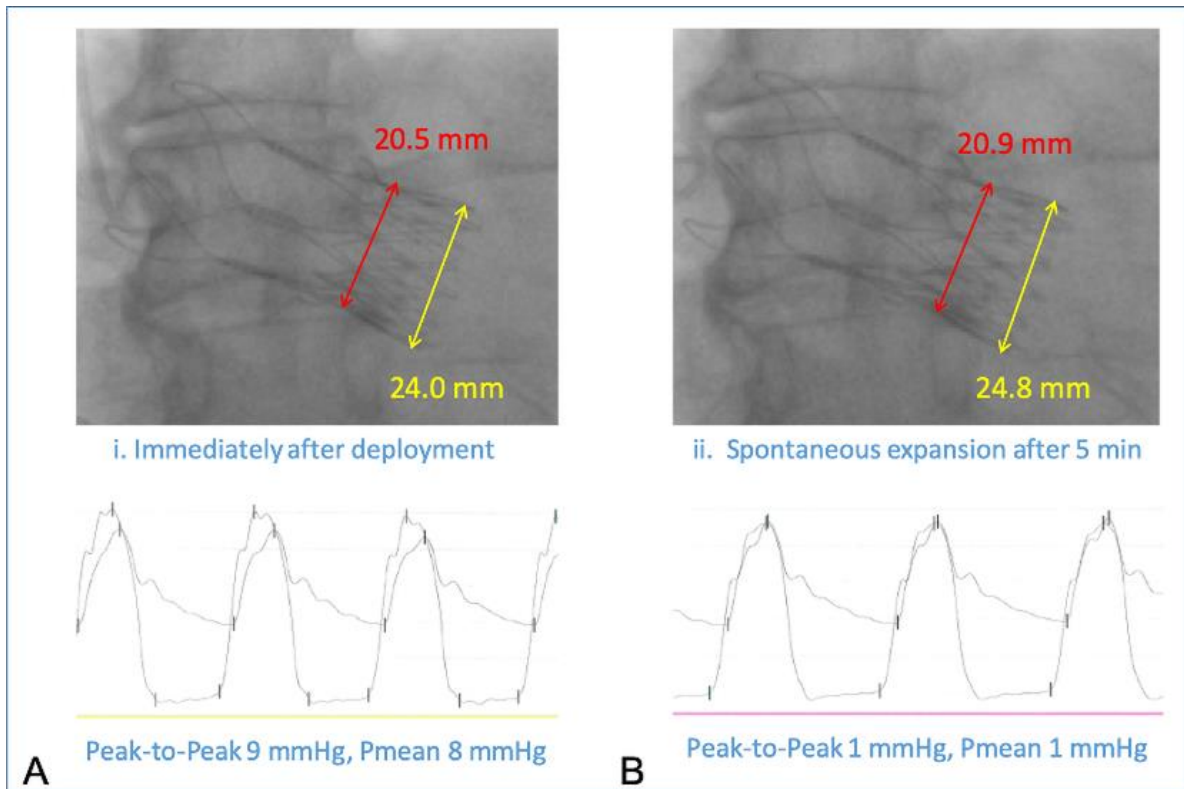
Despite the same total amount of aortic valve calcification (Agatston score $>4,500$ AU), patients in the left panels had no relevant post-procedural paravalvular leakage after implantation of the ACURATE *neo* device, whereas those in the right panels had moderate/severe paravalvular leakage, most likely related to the unfavourable distribution of the calcium.



Supplementary Figure 3. iSLEEVE expandable introducer set.

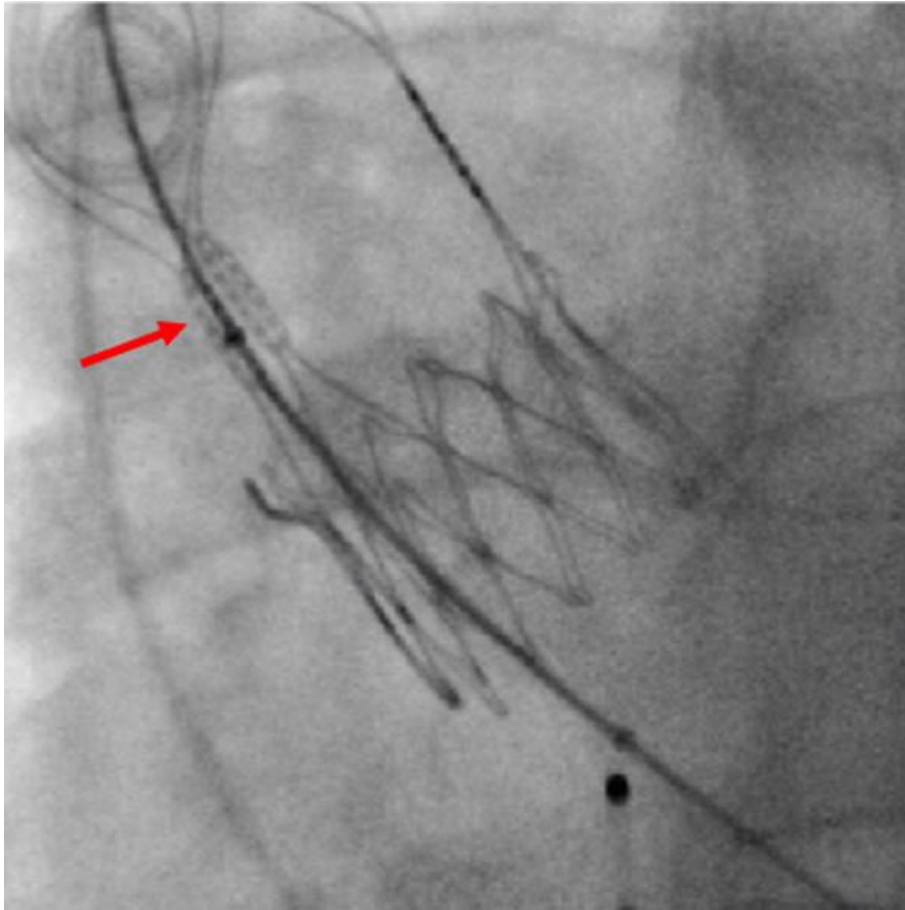
The iSLEEVE introducer sheath has a low profile with an inner diameter (ID) of 4.8 mm and outer diameter (OD) of 5.9 mm at the tip (ID 7.0 mm and OD 7.9 mm at the proximal end of the sheath).

The trifold design enables controlled expansion and accommodation to the vessel anatomy during insertion of the delivery system.



Supplementary Figure 4. In vivo expansion of the ACURATE *neo*.

Immediately after deployment, gradients are slightly increased (A). After a few minutes, there is a visible expansion of the stent body along with a reduction in the transaortic gradient (B).



Supplementary Figure 5. Post-dilatation.

The balloon should be placed in the mid part of the stent body just below the stent posts (red arrow).

Supplementary Table 1. Differential selection of transcatheter heart valves.

THV	Access	Predilatation	Rapid pacing	Ease of use	PVL	PPI	Gradient	Annulus range (mm)	DLZ calcification	Coronary access
ACURATE	+	yes	no	++	o	++	++	20–27	-	+
<i>neo</i>										
Evolut R	++	no	no	+	+	-	++	18–31	+	o
Lotus	o	no	no	-	++	-	-	20–27	++	-
Portico	+	yes	no	o	+	o	+	19–27	o	o
SAPIEN 3	+	no	yes	++	++	o	-	20–32*	++	+

DLZ: device landing zone; PPI: permanent pacemaker implantation; PVL: paravalvular leakage; THV: transcatheter heart valve

++ very good

+ good

o indifferent

- suboptimal

Supplementary Table 2. Sizing recommendation (modified according to Kim et al [2] with permission).

ACURATE <i>neo</i> size	Official sizing recommendation Annulus diameter	Modified sizing recommendation* Perimeter-derived annulus diameter (cover index)
S	21–23 mm	20.0–22.4 mm [13.0-2.6%]
M	23–25 mm	22.5–24.3 mm [10.0-2.8%]
L	25–27 mm	24.4–26.3 mm [9.6-2.6%]

* For discrimination of PVL $\geq 2^\circ$, the threshold of the cover index based on the perimeter-derived annulus in systole was 2.5% with an area under the curve of 0.645 (95% CI: 0.535-0.755); p=0.01; sensitivity 79.9%, specificity 46.4%.