

Self-expandable valve implantation within a failed balloon-expandable valve

Ran Kornowski*, MD, FESC, FACC; Pablo Codner, MD; Hana Vaknin-Assa, MD; Abid Assali, MD

Rabin Medical Center and The Sackler School of Medicine - Tel Aviv University, Petah Tikva, Israel

This paper also includes accompanying supplementary data published online at: http://www.pconline.com/eurointervention/79th_issue/170

Percutaneous implantation of an aortic valve is an alternative for the treatment of bioprosthetic surgical valve deterioration. Less is known about the treatment options for failed catheter

Editorial, see page 900

implanted valves. We report herein a case of an early degeneration of the Edwards SAPIEN XT balloon-expandable valve (Edwards Lifesciences, Irvine, CA, USA) which we treated using the successful implantation of a self-expandable CoreValve® (Medtronic, Minneapolis, MN, USA) in a patient sustaining haemodialysis. The patient was referred to our service due to signs and symptoms of severe aortic stenosis 20 months after transcatheter aortic valve implantation (TAVI) using the balloon-expandable Edwards SAPIEN XT 23 mm device. Echo findings showed thickened and poorly mobile aortic valve leaflets, and pressure gradients were 90/60 mmHg. Following consideration of the treatment options, we performed a second valve-in-valve TAVI procedure using a self-expandable CoreValve Evolut 23 mm device (Medtronic). The procedure was carried out smoothly and without complications (**Figure 1, Online Figure 1, Moving image 1-Moving image 6**).

The valve residual gradient was 28/18 mmHg and without residual paravalvular leak. This case indicates a possible relationship between the earlier catheter-based valve degeneration and the renal insufficiency/dialysis treatment characterising our patient. Importantly, it may also point towards an expansion of the future treatment options following late failure of catheter-based valve devices.

Conflict of interest statement

The authors have no conflicts of interest to declare.

Online data supplement

Online Figure 1. Haemodynamic tracing pre- and post-deployment.

Moving image 1. Pre valve-in-valve echo.

Moving image 2. Pre valve-in-valve angio 1.

Moving image 3. Pre valve-in-valve angio 2.

Moving image 4. Deployment landing angio.

Moving image 5. Deployment completion angio.

Moving image 6. Post valve-in-valve angio.

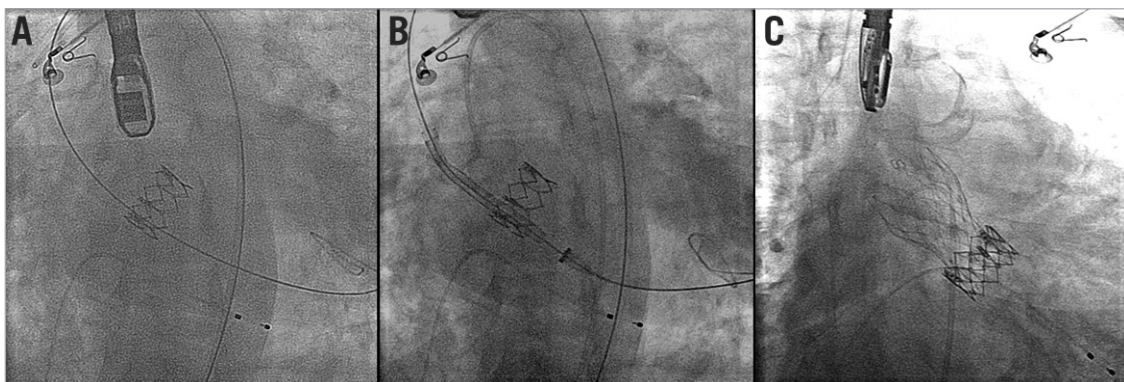
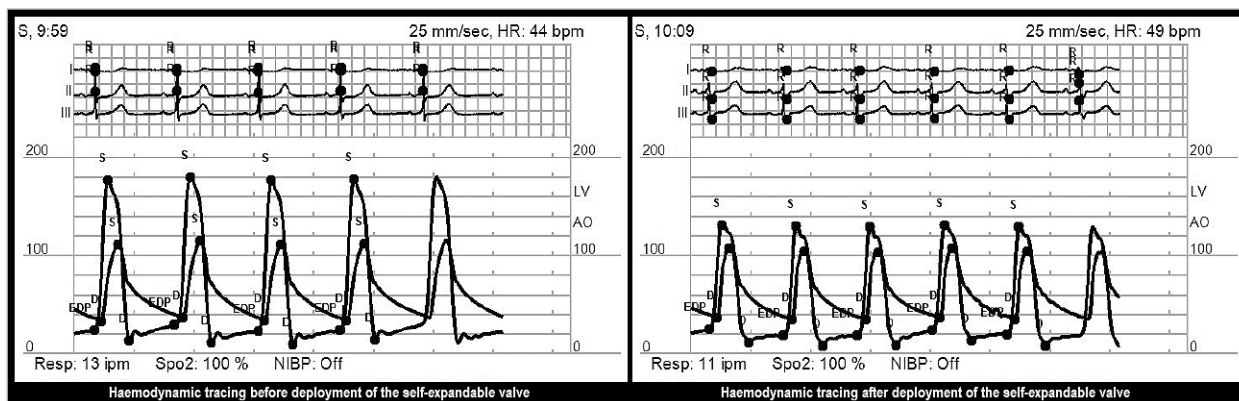


Figure 1. CoreValve Evolut 23 mm within Edwards SAPIEN XT 23 mm. A) A stiff guidewire has been crossed to the left ventricle through the Edwards SAPIEN XT valve. B) The self-expandable CoreValve within the Edwards SAPIEN XT in the pre-deployment phase. C) Final position of the self-expandable device within the balloon-expandable valve.

* Corresponding author: Rabin Medical Center and The Sackler School of Medicine - Tel Aviv University, Petah Tikva, Tel Aviv, Israel. E-mail: ran.kornowski@gmail.com

Online data supplement



Online Figure 1. Haemodynamic tracing pre- and post-deployment.