

# Percutaneous recanalisation of chronic total occlusions: 2019 consensus document from the EuroCTO Club



**Alfredo R. Galassi<sup>1\*</sup>**, MD; Gerald S. Werner<sup>2</sup>, MD, PhD; Marouane Boukhris<sup>3</sup>, MD; Lorenzo Azzalini<sup>4</sup>, MD, PhD, MSc; Kambis Mashayekhi<sup>5</sup>, MD; Mauro Carlino<sup>4</sup>, MD; Alexandre Avran<sup>6</sup>, MD; Nikolaos V. Konstantinidis<sup>7</sup>, MD, MSc; Luca Grancini<sup>8</sup>, MD; Leszek Bryniarski<sup>9</sup>, MD, PhD; Roberto Garbo<sup>10</sup>, MD; Nenad Bozinovic<sup>11</sup>, MD; Antony H. Gershlick<sup>12</sup>, MD; Sudhir Rathore<sup>13</sup>, MD; Carlo Di Mario<sup>14</sup>, MD, PhD; Yves Louvard<sup>15</sup>, MD; Nicolaus Reifart<sup>16</sup>, MD, PhD; Georgios Sianos<sup>7</sup>, MD, PhD; on behalf of the EuroCTO Club

1. Department of Experimental and Clinical Medicine, University of Catania, Catania, Italy; 2. Medizinische Klinik I (Cardiology & Intensive Care), Klinikum Darmstadt GmbH, Darmstadt, Germany; 3. Department of Cardiology, Abderrahmen Mami Hospital, Ariana - Faculty of Medicine of Tunis, University of Tunis El Manar, Tunis, Tunisia; 4. Interventional Cardiology Division, Cardio-Thoraco-Vascular Department, San Raffaele Scientific Institute, Milan, Italy; 5. Division of Cardiology and Angiology II, University Heart Center Freiburg - Bad Krozingen, Bad Krozingen, Germany; 6. Arnault Tzanck Institute, St Laurent du Var, Nice, France; 7. AHEPA University General Hospital of Thessaloniki, 1<sup>st</sup> Cardiology Department, Thessaloniki, Greece; 8. Centro Cardiologico Monzino, IRCCS, Milan, Italy; 9. II Department of Cardiology and Cardiovascular Interventions, University Hospital, Jagiellonian University Medical College, Krakow, Poland; 10. Policlinico San Giovanni Bosco, Turin, Italy; 11. Department of Invasive Cardiology and Electrostimulation, Clinic for Cardiovascular Diseases, Clinical Center Nis, Nis, Serbia; 12. Biomedical Research Centre, University of Leicester and University Hospitals of Leicester, Leicester, United Kingdom; 13. Frimley Park Hospital NHS Foundation Trust, Frimley, United Kingdom; 14. Structural Interventional Cardiology, Careggi University Hospital, Florence, Italy; 15. Ramsay Générale de Santé - Institut Cardiovasculaire Paris Sud, Hôpital Privé Jacques Cartier, Massy, France; 16. Department of Cardiology, Petrus-Krankenhaus, Wuppertal, Germany

This paper also includes supplementary data published online at: <https://eurointervention.pconline.com/doi/10.4244/EIJ-D-18-00826>

## KEYWORDS

- chronic total occlusion
- drug-eluting stent
- stable angina

## Abstract

Since its inception in December 2006, the EuroCTO Club has strived to provide the framework for state-of-the-art chronic total occlusion (CTO) percutaneous coronary intervention (PCI) in Europe and nearby regions. Among its initiatives, the EuroCTO Club has published a set of recommendations regarding the technical aspects of CTO PCI, whose last edition dates to 2012. The EuroCTO Club consensus document discusses CTO PCI clinical indications, techniques and equipment use, as well as the qualifications of operators/centres. Given the considerable amount of progress made by this subspecialty in recent years, there is a need for an updated document that includes data from recent clinical trials and registries, information on novel devices and techniques, and an up-to-date revision on the training requirements to approach CTO PCI. The current updated consensus document of the EuroCTO Club reflects the expertise of European operators to promote the widespread application of state-of-the-art CTO PCI, not only in Europe but also across neighbouring communities.

\*Corresponding author: Department of Experimental and Clinical Medicine, University of Catania, Via Antonello da Messina 75, 95021 Aci Castello (CT), Italy. E-mail: [argalassi@gmail.com](mailto:argalassi@gmail.com)

## Abbreviations

<b>ADR</b>	antegrade dissection re-entry
<b>AWE</b>	antegrade wire escalation
<b>CABG</b>	coronary artery bypass grafting
<b>CART</b>	controlled antegrade retrograde tracking
<b>CTO</b>	chronic total occlusion
<b>DAPT</b>	dual antiplatelet therapy
<b>DES</b>	drug-eluting stent(s)
<b>EES</b>	everolimus-eluting stent(s)
<b>IVUS</b>	intravascular ultrasound
<b>MDCT</b>	multidetector computed tomography
<b>OMT</b>	optimal medical therapy
<b>OTW</b>	over-the-wire
<b>PCI</b>	percutaneous coronary intervention
<b>SES</b>	sirolimus-eluting stent(s)
<b>STEMI</b>	ST-elevation myocardial infarction
<b>TIMI</b>	Thrombolysis In Myocardial Infarction

## Introduction

The EuroCTO Club was established in December 2006. The first two consensus documents on the recanalisation of chronic total occlusions (CTOs) were published in 2007 and 2012<sup>1,2</sup>, respectively, to provide an overview of CTO-dedicated material and to try to set standards on clinical indications, techniques and equipment use, and the qualifications of operators/centres. Since 2012, there have been considerable changes in practice, in parallel with the publication of a plethora of novel data, dramatically changing the landscape of CTO percutaneous coronary intervention (PCI).

For this reason, the EuroCTO Club has written this updated consensus document, reflecting the expertise of European operators to promote the widespread application of state-of-the-art CTO PCI in Europe and neighbouring communities.

Editorial, see page 137

## DEFINITION AND EPIDEMIOLOGY

Coronary CTO is defined as a 100% stenosis with Thrombolysis In Myocardial Infarction (TIMI) grade 0 flow for more than three months<sup>1,2</sup>. Non-intralesional ipsilateral bridging collaterals may provide antegrade flow to the vessel beyond the occlusion and give a false impression of a functional incomplete occlusion. This should be distinguished from flow within the occluded segment by a careful frame-by-frame assessment in different angiographic projections.

Coronary CTOs are relatively common, observed in approximately 15-25% of patients with coronary artery disease undergoing coronary angiography<sup>3-7</sup>. The right coronary artery is the most common CTO vessel, representing about half of the CTO cases<sup>5</sup>. The CTO prevalence is much higher (~90%) among patients with prior coronary artery bypass grafting (CABG)<sup>5</sup>, while a CTO is found in only one tenth of patients referred for ST-elevation myocardial infarction (STEMI)<sup>8</sup>.

## COLLATERAL CIRCULATION IN CTOs

The typical feature of a CTO is the presence of collaterals, found in ~90% of cases<sup>5</sup>. They have the capacity to preserve myocardial

function but will not prevent ischaemia during exercise due to a limited capacity to increase blood flow<sup>9</sup>. The collateral supply provides a perfusion pressure in the range of 30-40 mmHg at the occluded territory, a pressure that leads to the functional reduction of distal vessel size, which then leads to the underestimation of the vessel dimensions during a recanalisation procedure<sup>10</sup>. The presence of collaterals does not predict viability, as they also develop in patients with prior myocardial infarction and large akinetic territories, i.e., viability still needs to be tested in well collateralised CTOs<sup>11</sup>. Moreover, the presence of a well-developed network of collaterals is not protective towards ischaemic insults, as even in such a patient population revascularisation might provide a survival benefit compared with medical therapy<sup>12</sup>.

The angiographic assessment has been refined beyond the classic Rentrop classification by introduction of the grading of the collateral connection size<sup>13</sup>, which is also helpful to select the appropriate guidewires and techniques for collateral crossing. A more detailed analysis of collateral supply led to the introduction of a collateral scoring system for the suitability for retrograde transcatheter interventions<sup>14</sup>.

## RATIONALE OF CTO REVASULARISATION

Viable myocardium subtended by a CTO is generally ischaemic, regardless of the degree of collateralisation, as has been shown in fractional flow reserve (FFR) studies<sup>15,16</sup>. CTO recanalisation aims to improve myocardial perfusion of the corresponding ischaemic territory<sup>17</sup>. This in turn has beneficial effects at multiple levels (attendant on CTO success). First, successful CTO PCI relieves ischaemia<sup>18,19</sup>, which has been shown to be associated with a decrease in severity and frequency of angina, as well as improved functional status and better quality of life<sup>19,20</sup>. Second, an untreated CTO is associated with incomplete revascularisation<sup>21,22</sup>, which in turn has been associated with persistent left ventricular dysfunction at follow-up<sup>23</sup>. As such, CTO recanalisation allows complete revascularisation which might lead to improvement in left ventricular function<sup>23</sup>. Third, CTOs have an arrhythmic potential, as up to 3% of CTO patients present with malignant ventricular arrhythmias<sup>5</sup>. In a cohort of patients with implantable cardioverter-defibrillator, CTO subjects experienced a higher incidence of appropriate shocks for malignant ventricular arrhythmias, as compared to patients without CTO<sup>24</sup>. Moreover, ventricular arrhythmias can be observed even in the absence of myocardial scar, thus possibly being related to an ischaemic phenomenon<sup>25</sup>.

Since there are only observational data<sup>12</sup> suggesting a mortality benefit for CTO recanalisation, consideration for intervention should be in order to improve symptoms and quality of life. Appropriate indication is thus important in CTO intervention, not least since this procedure is associated with increased costs, cath lab resource utilisation, and procedural risks, as compared with non-CTO PCI. CTO recanalisation is indicated in cases where a significant benefit is likely in terms of symptom relief, ischaemia reduction, and/or improvement in left ventricular function<sup>17</sup>. A baseline echocardiogram should be performed in

all CTO patients. In patients with normal wall motion or hypokinesia of the CTO territory, myocardial viability is assumed to be present, and CTO recanalisation should be undertaken in patients who remain symptomatic (with angina or dyspnoea on exertion) despite optimal medical therapy (OMT) (e.g., two anti-anginal medications), with the aim of achieving complete revascularisation. In asymptomatic patients, ischaemic burden evaluation is recommended, and CTO recanalisation is indicated if ischaemia is present in  $\geq 10\%$  of the left ventricular mass<sup>18,26</sup>. In case of akinesia/dyskinesia of the CTO territory, proof of viability with non-invasive imaging should be pursued, and CTO recanalisation is indicated only in patients with viable myocardium in the CTO territory, associated with symptoms or ischaemia<sup>26</sup>. While these are general consensus recommendations, patients should be judged for intervention on a case-by-case basis (e.g., in case of anti-anginal drug intolerance).

### **GUIDELINES, CTO PCI REGISTRIES, AND RANDOMISED TRIALS**

Current guidelines recommend (class IIa B) that percutaneous revascularisation of CTOs should be considered in patients with angina resistant to medical therapy or with a large area of documented ischaemia in the territory of the occluded vessel<sup>27</sup>.

One obstacle to a wider adoption of CTO recanalisation is the absence of robust evidence on the benefits of this treatment. Non-randomised comparative studies showed a beneficial effect of CTO recanalisation on symptoms, quality of life, and left ventricular function<sup>12,28,29</sup>, while its impact on survival remains controversial<sup>28-30</sup>. However, this evidence is derived mostly from studies comparing patients with successful vs. unsuccessful CTO PCI and is therefore prone to important confounders.

Four randomised trials (RCTs) have now been published or presented. Each of these trials was modest in size and open-label in design. Definitive trials remain a scientific gap. The EXPLORE (Evaluating XIENCE and Left Ventricular Function in Percutaneous Coronary Intervention on Occlusions After ST-Elevation Myocardial Infarction) trial is based on the well-established observation of the disadvantage of a patient with a CTO when experiencing a STEMI (“double jeopardy”)<sup>31</sup>. The trial randomised survivors of a STEMI within seven days to receive PCI or conservative management for a concomitant CTO in order to observe differences in left ventricular function at four months<sup>31</sup>. The trial did not show a difference, but it was hampered by a low success rate for CTO PCI (73%), a high crossover rate (23%), and the fact that those most likely to profit from CTO PCI were those who died early from shock.

The DECISION-CTO trial was presented at ACC 2017, and has not yet been published as an article. It randomised patients with a CTO to OMT vs. CTO PCI. Critical flaws in trial design include the fact that revascularisation of non-CTO lesions was allowed in both groups and observed in more than 70% of patients (thus diluting the real impact of CTO recanalisation on patient outcomes), extremely low enrolment even from high-volume centres (which

suggests a strong selection bias), an 18% crossover rate, and the inclusion of all-cause death and stroke in the primary endpoint (while PCI in all-comers in an elective setting has never shown benefits with regard to such endpoints). Not surprisingly, the trial did not find any difference in the primary endpoint.

In contrast, the EUROCTO trial<sup>32</sup>, which also randomised CTO patients to OMT vs. CTO PCI, had all non-CTO lesions treated before randomisation, so the sole effect of a remaining CTO on symptoms could be evaluated (primary endpoint). The trial showed a superior effect of PCI on angina frequency and quality of life as compared with OMT, 12 months after randomisation<sup>32</sup>. Furthermore, physical limitation and functional angina class were improved. Of note, the success rate in that trial was 86.6%, thus in line with state-of-the-art CTO PCI worldwide<sup>32</sup>.

Recently, the IMPACTOR-CTO (Impact on Inducible Myocardial Ischemia of Percutaneous Coronary Intervention versus Optimal Medical Therapy in Patients with Right Coronary Artery Chronic Total Occlusion) trial randomly assigned patients with isolated CTO of the right coronary artery (RCA) to either PCI (n=32) or OMT (n=33)<sup>33</sup>. In the PCI group, Obodinskiy et al<sup>33</sup> demonstrated that the decrease in myocardial ischaemia burden at 12 months (primary endpoint) was significantly higher in comparison with the OMT group (13.9 $\pm$ 6.1% vs. 0.3 $\pm$ 4.2%; p<0.01). Similarly, functional status and quality of life only improved in the PCI group<sup>33</sup>, confirming the findings of the EUROCTO trial in the setting of single-vessel disease CTO patients.




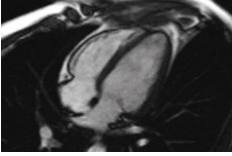

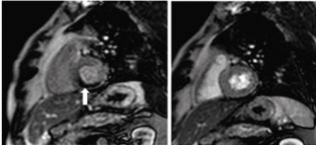
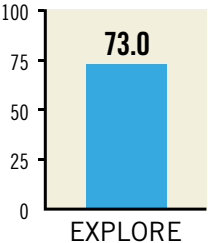
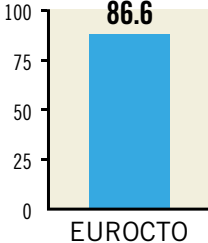
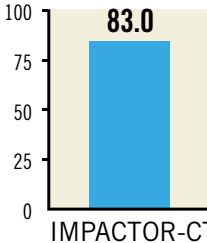



**Figure 1** summarises the major results of the published randomised CTO trials.

Next to randomised trials, which always include a selected patient group, registries including all-comers are important for the assessment of trends in treatment. Currently, the longest-running and largest registry is the ERCTO registry, with more than 17,000 procedures recorded. Since its inception in 2008, this registry has witnessed an increase in lesion complexity, with a parallel increase in the use of the retrograde approach and in success rates<sup>34</sup>.

## **Planning the CTO procedures**

### **PREDICTIVE CTO SCORES**

A key contributor to achieving success in CTO PCI is meticulous preparation. While the indication for CTO recanalisation should be clinical and not based on any score predicting the probability of technical success of the procedure, scoring models provide a quantitative measure of procedural difficulty and the probability of recanalisation success, which can help with clinical decision making. Furthermore, by providing more objective evaluation of anatomic and clinical complexity, CTO scores enable better case selection according to operators’ experience<sup>35</sup>. Finally, within the Heart Team, the decision to revascularise and the optimal strategy can be tailored to each CTO patient, taking into account the objective probability of achieving angiographic/clinical success with PCI.

	<b>EXPLORE</b>	<b>EUROCTO</b>	<b>IMPACTOR-CTO</b>																																													
<b>Location &amp; design</b>	Europe & Canada  Multicentre RCT (14 centres)	Europe  Multicentre RCT (28 centres)	Russia  Single-centre RCT																																													
<b>N patients</b>	304	407	72																																													
<b>Study population</b>	Patients with STEMI treated with PCI with a non-infarct-related CTO	SCAD CTO patients with symptoms and/or ischaemia and viability	Patients with isolated dominant RCA CTO and stable angina																																													
<b>Primary endpoint</b>	 LVEF and LVEDV by CMR	 QoL (SAQ, EQ-5D)	Stress      Rest  ΔMIB by adenosine stress CMR																																													
<b>Follow-up period</b>	4 months	1 year	1 year																																													
<b>Mean J-CTO score</b>	2±1	1.82±1.07	1.92±0.86																																													
<b>Success rate</b>	 73.0	 86.6	 83.0																																													
<b>Positive/negative RCT</b>																																																
<b>Major findings</b>	<table border="1"> <thead> <tr> <th></th> <th>PCI</th> <th>OMT</th> </tr> </thead> <tbody> <tr> <td>MACE</td> <td colspan="2">No difference</td> </tr> <tr> <td>QoL</td> <td colspan="2">N/A</td> </tr> <tr> <td>Ischaemia reduction</td> <td colspan="2">N/A</td> </tr> <tr> <td>LVEF and LVEDV</td> <td colspan="2">No difference</td> </tr> </tbody> </table> <p>PCI of a CTO located in the LAD may improve LVEF and clinical outcome</p>		PCI	OMT	MACE	No difference		QoL	N/A		Ischaemia reduction	N/A		LVEF and LVEDV	No difference		<table border="1"> <thead> <tr> <th></th> <th>PCI</th> <th>OMT</th> </tr> </thead> <tbody> <tr> <td>MACE</td> <td colspan="2">No difference</td> </tr> <tr> <td>QoL</td> <td colspan="2">Better</td> </tr> <tr> <td>Ischaemia reduction</td> <td colspan="2">N/A</td> </tr> <tr> <td>LVEF and LVEDV</td> <td colspan="2">N/A</td> </tr> </tbody> </table>		PCI	OMT	MACE	No difference		QoL	Better		Ischaemia reduction	N/A		LVEF and LVEDV	N/A		<table border="1"> <thead> <tr> <th></th> <th>PCI</th> <th>OMT</th> </tr> </thead> <tbody> <tr> <td>MACE</td> <td colspan="2">No difference</td> </tr> <tr> <td>QoL</td> <td colspan="2">Better</td> </tr> <tr> <td>Ischaemia reduction</td> <td colspan="2">Better</td> </tr> <tr> <td>LVEF and LVEDV</td> <td colspan="2">N/A</td> </tr> </tbody> </table>		PCI	OMT	MACE	No difference		QoL	Better		Ischaemia reduction	Better		LVEF and LVEDV	N/A	
	PCI	OMT																																														
MACE	No difference																																															
QoL	N/A																																															
Ischaemia reduction	N/A																																															
LVEF and LVEDV	No difference																																															
	PCI	OMT																																														
MACE	No difference																																															
QoL	Better																																															
Ischaemia reduction	N/A																																															
LVEF and LVEDV	N/A																																															
	PCI	OMT																																														
MACE	No difference																																															
QoL	Better																																															
Ischaemia reduction	Better																																															
LVEF and LVEDV	N/A																																															

**Figure 1.** Major findings of the published RCTs comparing PCI vs. OMT in CTO patients. ΔMIB: decrease in myocardial ischaemia burden; CMR: cardiac magnetic resonance; CTO: chronic total occlusion; EQ-5D: EuroQol 5 dimensions questionnaire; J-CTO: Japanese chronic total occlusion; LAD: left anterior descending; LVEDV: left ventricular end-diastolic volume; LVEF: left ventricular ejection fraction; MACCE: major adverse cardiac and cerebrovascular events; MACE: major adverse cardiovascular events; MI: myocardial infarction; OMT: optimal medical therapy; PCI: percutaneous coronary intervention; QoL: quality of life; RCA: right coronary artery; RCT: randomised clinical trial; SAQ: Seattle Angina Questionnaire; STEMI: ST-segment elevation myocardial infarction

The J-CTO (multicentre CTO registry in Japan) score is currently the most widely used score<sup>36</sup>. Independent predictors of failure (each given one point) that make up the J-CTO score include prior failed attempt, angiographic evidence of heavy calcification, bending  $\geq 45^\circ$  within the occluded segment, blunt proximal stump, and occlusion length  $>20$  mm. CTO lesions are then graded as easy, intermediate, difficult, and very difficult (J-CTO scores of 0, 1, 2, and  $\geq 3$ , respectively)<sup>36</sup>. While experienced operators can attempt even the toughest of cases with high success rates, operators early in their learning curve can select “simpler” cases (J-CTO score 0 or 1), referring those judged to be more difficult (J-CTO  $\geq 2$ ) to CTO-dedicated centres, or performing them with the guidance of a proctor<sup>35</sup>.

Newer CTO scores highlight the variety of approaches to CTO PCI. The clinical and lesion-related (CL) score created based on primarily antegrade procedures may perform better for antegrade-only operators<sup>37</sup>, whereas the ORA (ostial location, Rentrop grade  $<2$ , age  $\geq 75$  years) score and the PROGRESS CTO (Prospective Global Registry for the Study of Chronic Total Occlusion Intervention) score may be more suitable for predicting recanalisation success in retrograde or hybrid procedures<sup>38,39</sup>.

#### MULTIDETECTOR COMPUTED TOMOGRAPHY (MDCT)

The importance of preprocedural multidetector computed tomography (MDCT) remains debatable. MDCT is more accurate than angiography for the definition of the CTO length, the presence of calcium, and the determination of vessel size and remodelling<sup>40</sup>. Recently, two MDCT-based scores (CT-RECTOR and KKCT) have been introduced<sup>41,42</sup>. Compared with the angiography-based J-CTO score, these MDCT scoring systems provide a more accurate non-invasive tool for predicting time-efficient guidewire crossing and final procedural success. MDCT is also indicated in case of long ambiguous CTOs, with poor path visualisation via collaterals and previously failed procedures<sup>40</sup>. In the cath lab, MDCT can also be of benefit for visualisation of the guidewire advancement and optimisation of viewing angles, taking advantage of co-registration. However, its availability is limited. Further studies are required to determine the added value of preprocedural MDCT in CTO PCI better.

#### FAILING CTO PCI – WHEN TO STOP

Although failure can be highly frustrating and demoralising, being able to accept it and learn and apply the lessons that failure provides is a critical step for the CTO operator. Indeed, the art of “knowing when to stop” is a key issue in CTO PCI to avoid major complications. Operators should consider stopping a CTO PCI attempt if the procedure time is  $>3$  hours, if more than 4x the estimated glomerular filtration rate of contrast has been used or if the radiation dose is  $>5$  Gy air kerma, unless recanalisation is already about to be completed (e.g., antegrade wire in the distal true lumen, or having crossed the retrograde collateral channel). In case of subintimal tracking with failure to re-enter the true lumen, planning a new attempt could be associated with better procedural

outcome. Subintimal plaque modification by balloon angioplasty may alter the occlusion anatomy, favouring true-to-true wiring on a subsequent attempt<sup>43</sup>. In certain cases, the vessel can heal quite favourably and occlusion recanalisation can be observed. It is therefore not surprising that subintimal plaque modification can promote an improvement in quality of life and angina<sup>44</sup>. In case of no symptomatic improvement, the patient can be brought back and recanalisation re-attempted after six to eight weeks from the first attempt.

Although CTOs re-attempted after initial failure are associated with higher angiographic complexity, longer procedural duration and fluoroscopy time in comparison with first attempt CTO lesions, in experienced hands the success and complication rates were reported to be similar<sup>45</sup>. The number of times a procedure may be re-attempted is an individual question to be assessed carefully by the treating physician and the patient, and must take into consideration the severity of symptoms, likelihood of success, risk of complications, and the patient’s wishes.

### CTO materials and dedicated devices GUIDEWIRES

Guidewire technology has largely evolved during the last decade and contributed to technique evolution and procedural efficiency. No single wire serves all lesions and all circumstances. Understanding the interaction of different kinds of guidewire (soft  $<1$  gr, intermediate stiff 2-6 gr, stiff  $>9$  gr) with different types of tissue (soft, hard and calcified) is of paramount importance. Soft ( $<1$  gr) tapered polymeric composite core guidewires are suitable for soft tissue tracking (passive wire control). Intermediate stiffness (2-6 gr) tapered composite core guidewires are used for hard tissue tracking (active wire control), while very stiff ( $>9$  gr) tapered guidewires are suitable for calcified tissue penetration<sup>46</sup>.

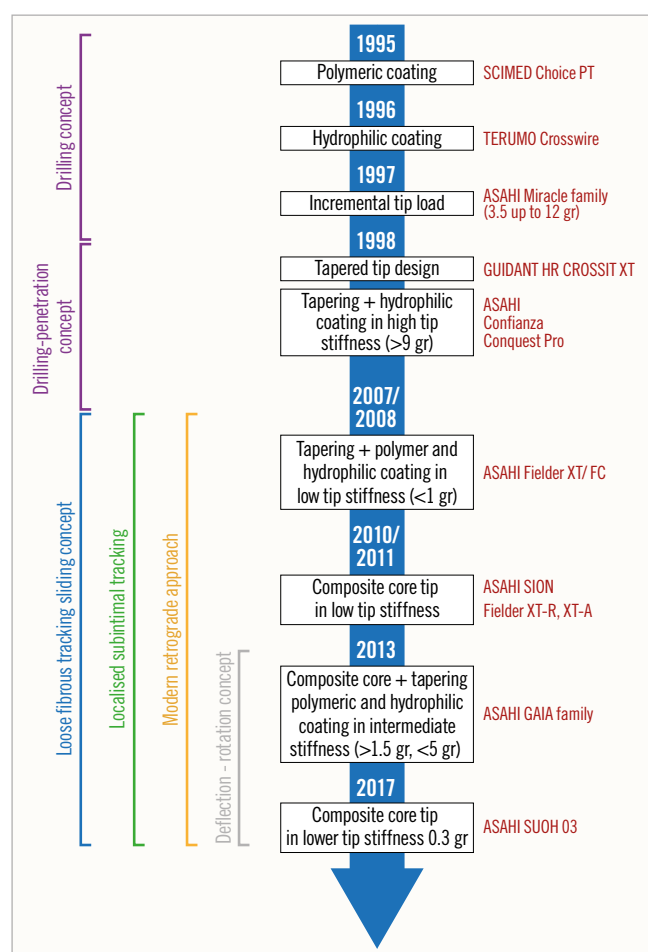
In the early era of CTO PCI stiff wires, non-tapered (Miracle family) and tapered (Confianza family; both Asahi Intecc, Aichi, Japan), were predominantly used for lesion crossing. These wires were limited by incapacity to deflect and poor steerability in tortuous anatomy. In 2008, low tip stiffness ( $<1$  gr) in combination with tapering, polymer and hydrophilic coating was introduced (Fielder™ XT; Asahi Intecc) and was proven to be very good for soft tissue tracking, offering a success rate of 30-40%, but it tended to over-deflect and was also not steerable in more complex anatomy. The advent of two technologies addressed the abovementioned limitations. The first one was the composite core technology, that became available in 2010-2011 (Asahi SION family), dramatically enhancing wire steerability and tip shape retention and which was also introduced in the low stiffness wires to improve their performance (Fielder XT-A/Fielder XT-R). The second one was based on the growing experience and understanding of CTOs over the years, that made it evident that penetration power and steerability can only be combined in intermediate stiffness wires. In 2013 a combination of composite core, tapering, polymeric and hydrophilic coating in

intermediate stiffness wires introduced the “deflection and rotation” concept that prevailed in modern CTO wiring (Gaia family; Asahi Intecc). The use of these wires will continue to increase in all anatomies except heavily calcified lesions, where very stiff wires are indispensable.

The milestones of CTO guidewire development are presented in **Figure 2** and an overview of the currently available CTO guidewires is presented in **Supplementary Table 1**<sup>2,46</sup>.

## MICROCATHETERS

In the current era of CTO PCI, guidewires should always be used with an over-the-wire (OTW) device (microcatheter or over-the-wire balloon) in order to ease torque in the tip response, preventing flexion, kinking, prolapse of the guidewire, and improving penetration ability. Microcatheters also allow reshaping or changing the guidewire without losing the distal position. Microcatheters are generally preferred to OTW balloons. Indeed, they are more flexible and track better. Moreover, they allow better understanding of distal tip position and have less tendency to kink than OTW balloons.



**Figure 2.** Milestones in CTO guidewire technology. CTO: chronic total occlusion

**Table 1** illustrates the most commonly used microcatheters in CTO PCI.

Details concerning the use of several microcatheters are given in **Supplementary Appendix 1**.

## DUAL LUMEN MICROCATHETERS

Dual lumen microcatheters consist of a rapid exchange delivery system in the distal segment associated with an OTW lumen along the catheter. A radiopaque marker band identifies the distal tip of each lumen; the distal band corresponds to the exit point of the rapid exchange segment and the proximal band marks the exit point of the OTW lumen.

The indications for dual lumen microcatheters in CTO PCI can be summarised as follows: a) parallel wire technique; b) wiring a CTO in the presence of a side branch at the proximal cap; c) wiring the distal true lumen without losing access to a side branch near the distal cap; d) antegrade wiring of the distal true lumen if the externalised retrograde guidewire crossed a collateral near the distal cap; e) wiring of difficult-to-access collaterals for the retrograde approach. Hence, such devices are useful to treat bifurcation lesions within the CTO body or located in close proximity to the proximal or distal cap, particularly when a long dissection is present and the second wire has to follow the same course as the first wire for optimal bifurcation treatment using either the one- or two-stent technique.

**Table 1.** An overview of microcatheters used in Europe.

Manufacturer	Catheter	Length	Distal shaft outer diameter
Asahi Intecc	Tornus	135 cm	2.1 and 2.6 Fr
	Corsair and Corsair Pro	135 cm, 150 cm	2.6 Fr
	Caravel	135 cm, 150 cm	1.9 Fr
Boston Scientific	Renegade™ 18	105 cm, 115 cm, 135 cm	2.5 Fr
IMDS	NHancer Pro X	135 cm, 155 cm	2.3 Fr
Roxwood (now BTG)	MicroCross® 14 and MicroCross® 14ES	155 cm	1.6 Fr
Terumo	Finecross®	130 cm, 150 cm	1.8 Fr
Teleflex	Venture®	145 cm (rapid exchange), 140 cm (over-the-wire)	2.2 Fr
	SuperCross™	130 cm, 150 cm Preformed tip angle (45°, 90° or 120°)	2.1 Fr
	Turnpike®	135 cm, 150 cm	2.6 Fr
	Turnpike® LP	135 cm, 150 cm	2.2 Fr
	Turnpike® Spiral	135 cm, 150 cm	3.1 Fr
	Turnpike® Gold	135 cm	3.2 Fr
Acrostak	M-CATH	135 cm	2.25 Fr
Merit Medical	SwiftNINJA	125 cm	2.4 Fr

Asahi Intecc, Aichi, Japan; Boston Scientific Corp., Marlborough, MA, USA; IMDS, Roden, the Netherlands; BTG, Bothell, WA, USA; Terumo Corp., Tokyo, Japan; Teleflex/Vascular Solutions, Minneapolis, MN, USA; Acrostak, Geneva, Switzerland; Merit Medical, Galway, Ireland

An overview of the currently available dual lumen microcatheters is presented in **Supplementary Table 2**.

### SUPPORT CATHETERS AND GUIDE EXTENSION CATHETERS

An overview of the utility and use of currently available support catheters and guide extension catheters is presented in **Supplementary Appendix 2** and **Supplementary Table 3**.

## Techniques for CTO recanalisation

### ACCESS ROUTE – GUIDING CATHETER SELECTION, CONTRALATERAL INJECTION

For CTO recanalisation, it is mandatory to ensure an optimal guide catheter support with a large enough lumen to host devices in parallel, as well as two arterial sheaths for contralateral injections. Good ipsilateral collateralisation may allow one to start unilaterally; however, performing a CTO recanalisation without displaying the distal coronary target is irresponsible. Indeed, dual injection allows better visualisation and understanding of CTO morphology and complexity. In addition, it can improve procedural safety by elucidating guidewire location during crossing attempts. CTO PCI with a single guide can be performed in selected cases with absent collateral circulation or only ipsilateral collateralisation.

Most operators use 7 Fr guides for recanalisation and 5 or 6 Fr guides for contralateral injection<sup>47</sup>. We recommend the use of guide catheters with side holes to prevent forceful intraplaque injections that may easily cause spiral dissections and also to allow proper monitoring of the arterial pressure. For the left coronary artery, extra backup guides (EBU) are most appropriate; sometimes Amplatz left curves are valid alternatives for the circumflex artery. For the right coronary, Judkins right or Amplatz left (AL1 or AL 2) represent the most employed catheters, while internal mammary artery (IMA) guides, shepherd's crook (SC) or hockey stick curves are useful for SC origin engagement. The operator should be familiar with deep intubation, anchoring balloon and mother-and-child techniques (guide-in-guide). The various choices for access are: bifemoral artery, biradial (or ulnar) artery<sup>48</sup>, radial and femoral, and two ipsilateral femoral sheaths<sup>49</sup>. While the radial approach appears more cumbersome, especially in very complex CTO procedures, none of the approaches was shown to be superior to any other<sup>48</sup>.

Regarding periprocedural anticoagulation, an initial bolus of intravenous unfractionated heparin (100 IU/kg) is generally administered. The activated clotting time is then monitored every 30 minutes to determine whether an additional bolus of unfractionated heparin is necessary to maintain an activated clotting time >250-300 s. Upstream use of low molecular weight heparin, glycoprotein IIb/IIIa inhibitor therapy or bivalirudin is generally not recommended.

### ANTEGRADE APPROACH

The antegrade approach, and particularly antegrade wire escalation (AWE), remains the cornerstone of CTO PCI, being performed in approximately three quarters of cases<sup>50,51</sup>. All experts

agree that AWE is the strategy of choice in case of non-ambiguous proximal cap, good distal landing zone, and lesion length <20 mm. Indeed, a true-to-true lumen approach – when feasible – seems recommendable, as extensive vessel disruption with dissection/re-entry techniques is associated with greater intravascular ultrasound (IVUS)-detected vascular injury, angiographic dye staining/extravasation, branch occlusion, and periprocedural myocardial infarction<sup>52</sup>. However, the clinical significance of such findings is debated, since no clear evidence of the superiority of a true-to-true approach has been demonstrated so far<sup>53,54</sup>. The choice of microcatheters and guidewires depends on operator preference and specific angiographic features: in general, highly manoeuvrable guidewires with 1:1 torque response are recommended as initial choices (e.g., Gaia family, Fielder XT-R; FIGHTER™ [Boston Scientific, Marlborough, MA, USA]) to maintain an intra-plaque track. If a subintimal situation at the landing zone is observed, a wide array of techniques for true lumen re-entry is available. These encompass both wire-based and device-based (Stingray™; Boston Scientific) re-entry<sup>55</sup>. Among wire-based techniques, preference should be given to those providing targeted re-entry<sup>56</sup> (e.g., parallel wires, mini-STAR, limited antegrade subintimal tracking, IVUS-guided re-entry ...). Alternatively, antegrade dissection/re-entry (ADR) is suggested by some operators as a first-line strategy. This is usually performed in case of ambiguous proximal cap, adequate distal landing zone, and occlusion length >20 mm. In this setting, the CrossBoss™ (Boston Scientific) is recommended by some operators, since this catheter is meant to create a smaller subintimal space disruption compared with knuckle wires. Subsequently, Stingray-based re-entry may be performed.

### RETROGRADE APPROACH

The retrograde approach should be considered in occlusions with “interventional” collaterals (i.e., collaterals deemed to be negotiable by the operator depending on his/her experience), diseased landing zone, bifurcation at distal cap, and/or proximal cap ambiguity<sup>57</sup>. Dedicated microcatheters and guidewires should be used; the utilisation of OTW balloons and guidewires not specifically designed for collateral crossing should be avoided. Preference should be given to septal collaterals (due to lower risk in case of perforation as compared with epicardial channels)<sup>50,57,58</sup> and diseased/occluded saphenous vein grafts (which do not present side branches and therefore allow easy navigation)<sup>58</sup>. Epicardial collaterals should be considered only by very experienced operators and, in any case, as a second-line option<sup>59</sup>. Fortunately, septal channels are most frequently found in both right coronary artery (72%) and left anterior descending (52%) CTOs<sup>60</sup>. However, circumflex CTOs most frequently present ipsilateral epicardial collaterals, which should be tackled with great care, utilising dedicated wires (e.g., SUOH 03, SION black; both Asahi Intecc) and techniques (e.g., tip injection to delineate vessel course, rendezvous or tip-in for externalisation, etc.). In any case, specific complication-solving skills are needed when undertaking the

retrograde approach, including pericardiocentesis, coiling, covered stent implantation, and establishing haemodynamic support. With regard to the procedural techniques specific to the retrograde approach, although retrograde true-to-true wire crossing is ideally pursued in cases of short, non-calcified occlusions, reverse controlled antegrade and retrograde subintimal tracking (CART) is effectively performed in the majority of cases<sup>50,61</sup>. The recently introduced concept of “directed reverse CART” seems promising to maximise the effectiveness of this technique while limiting the extent of vessel damage. In directed reverse CART, close proximity between the antegrade and retrograde wires is achieved, before performing balloon dilatation with a small balloon (usually 2.0 mm). Then, a highly manoeuvrable retrograde wire (e.g., Gaia) is carefully manoeuvred towards the (lateral side of the) antegrade balloon, thus creating a connection between the retrograde and antegrade systems. If there is difficulty in making the connection, the use of IVUS should be considered to understand the antegrade and retrograde wire position<sup>62</sup>. Finally, in long occlusions with ambiguity or unclear vessel course and severe calcifications, a retrograde knuckle wiring (with polymer-jacketed guidewires) facilitates overcoming the occluded segment with a low risk of perforation.

#### THE CONCEPT OF THE “HYBRID ALGORITHM”

The integration of the aforementioned techniques into a homogeneous set of strategies has become known as the “hybrid algorithm”<sup>57</sup>. This approach was developed by North American operators in 2012 and is based on the concept of a rapid switch from one approach to another in case of low likelihood of success, in order to optimise procedural efficiency. After dual coronary angiography, four angiographic parameters are assessed: 1) proximal cap location and (non-) ambiguity; 2) occlusion length; 3) quality of the distal vessel; 4) presence of collaterals suitable for retrograde techniques (“interventional collaterals”). Based on these four features, an initial strategy and hierarchy for subsequent approaches are established. The hybrid algorithm has been shown

to be effective (success rates of ~90%), safe (low rates of complications: tamponade 1.3%, periprocedural myocardial infarction 1.0%, death 0.4%), and efficient (favourable procedural metrics)<sup>50</sup>. Additionally, the mantra of this algorithm is its reproducibility and the fact that it can be easily taught/learned, resulting in high success rates obtained by new operators<sup>63</sup>.

Recently, the Asia Pacific Chronic Total Occlusion Club developed a modified hybrid algorithm for CTO PCI<sup>35</sup>. Despite similarities with the traditional hybrid algorithm, major changes exist in this new algorithm: i) the role of IVUS-guided entry to overcome proximal cap ambiguity is clearly highlighted; ii) the CTO length alone does not determine the choice of either a wire escalation strategy or a dissection re-entry strategy; iii) the use of the parallel wire technique and IVUS-guided wiring as a bail-out strategy in the antegrade arm; iv) the CrossBoss catheter should be considered as the first-line device for in-stent CTO recanalisation<sup>35</sup>.

In **Figure 3**, we propose a modified hybrid algorithm for CTO PCI using the contemporary techniques.

#### Intravascular imaging in CTO PCI

The section on IVUS<sup>62,64,65</sup> can be found in **Supplementary Appendix 3**.

The section on OCT<sup>66,67</sup> can be found in **Supplementary Appendix 4**.

#### Stents in CTO PCI

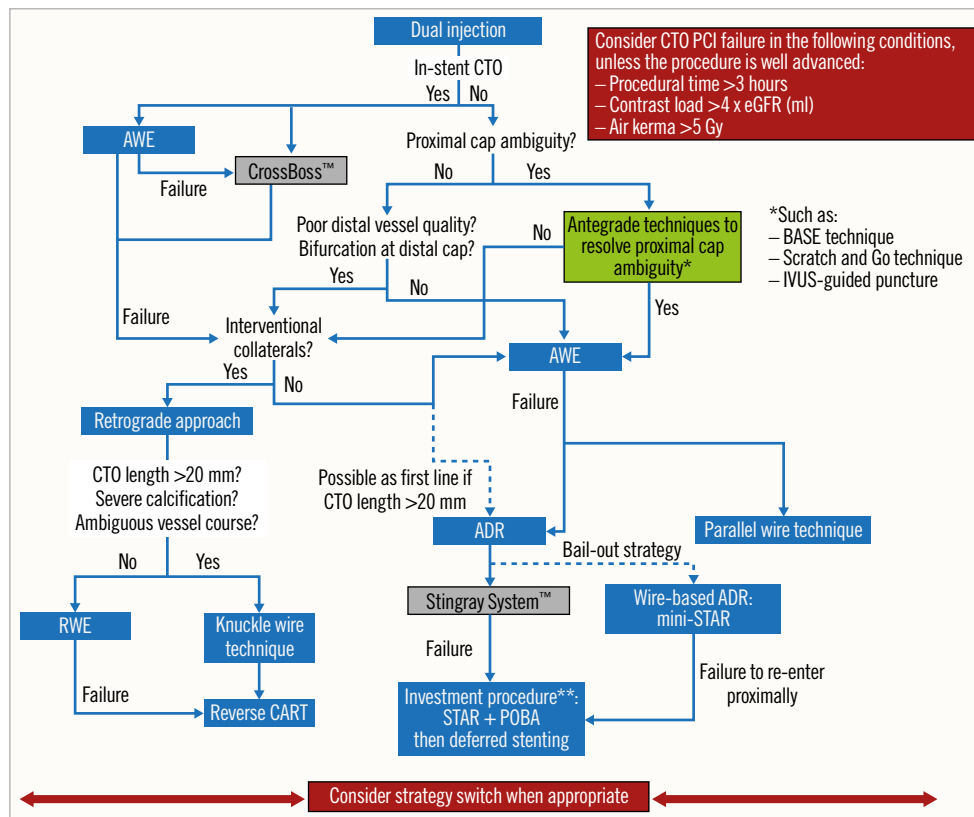
After successful recanalisation of CTOs, implantation of drug-eluting stents (DES) reduces the rates of major cardiac events, restenosis and stent re-occlusion as compared to bare metal stents<sup>68</sup>. Everolimus-eluting (EES) and zotarolimus-eluting stents (second-generation DES) are currently preferred for CTO interventions as they enable better outcomes compared to the first generation of DES<sup>69-73</sup> (**Table 2**). Although the BIOFLOW V study showed superiority of a hybrid ultra-thin sirolimus-eluting stent (SES) compared with EES, this finding was not confirmed in the PRISON IV study (non-inferiority for in-segment late

**Table 2. Comparison of published prospective studies on the clinical and angiographic outcomes with new-generation DES in CTOs.**

Study	Year	DES	N	FU angio time (months)	Prior CABG (%)	Total stent length (mm)	In-stent restenosis (%)	In-segment restenosis (%)	TLR (%)	TVR (%)
CIBELES <sup>69</sup>	2012	SES	101	9	4	47±24	NR	10.5	7.5	11.6
		EES	106	9	4.7	50±23	NR	9.1	6.0	7.9
CATOS <sup>70</sup>	2012	SES	80	9	NR	44.6±20.2	NR	13.7	NR	13.8
		Endeavor ZES	80	9	NR	43.4±21.5	NR	14.1	NR	7.5
PRISON III <sup>71</sup>	2012	SES	60	8	5.0	38.4±18.4	2.0	12.0	6.7	8.3
		Endeavor or Resolute ZES	62	8	8.1	41.0±19.2	5.5	10.9	4.8	4.8
ACE-CTO <sup>72</sup>	2015	EES	100	8	27	85±34	46	46	37	39
EXPERT CTO <sup>73</sup>	2015	EES	222	12	9.9	52±27	NR	NR	6.3	NR

CABG: coronary artery bypass graft surgery; CTO: chronic total occlusion; DES: drug-eluting stents; EES: everolimus-eluting stents; FU: follow-up; NR: not reported; SES: sirolimus-eluting stents; TLR: target lesion revascularisation; TVR: target vessel revascularisation; ZES: zotarolimus-eluting stents





**Figure 3.** Modified hybrid algorithm for CTO PCI. \*\*Investment procedure refers to deferred stenting (during a second procedure) after subintimal plaque modification via the STAR technique and balloon dilatation<sup>43</sup>. ADR: antegrade dissection re-entry; AWE: antegrade wire escalation; BASE: balloon-assisted subintimal entry; CART: controlled antegrade retrograde tracking; CTO: chronic total occlusion; eGFR: estimated glomerular filtration rate; IVUS: intravascular ultrasound; PCI: percutaneous coronary intervention; POBA: plain old balloon angioplasty; RWE: retrograde wire escalation; STAR: subintimal tracking and re-entry

lumen loss not reached, and a higher rate of binary restenosis in the hybrid SES group)<sup>74,75</sup>. The promising concept of this stent design needs further research in CTO lesions. In the EUROCTO trial, biolimus-eluting stents with abluminal biodegradable polymer were used with satisfactory one-year outcome (ischaemia-driven revascularisation – 2.9%)<sup>32</sup>.

Although the concept of biodegradable scaffold use in CTOs appeared to be attractive, they are actually no longer recommended for clinical use. Some authors have also proposed the concept of using drug-coated balloons without stent implantation in CTO PCI; however, this needs further evaluation.

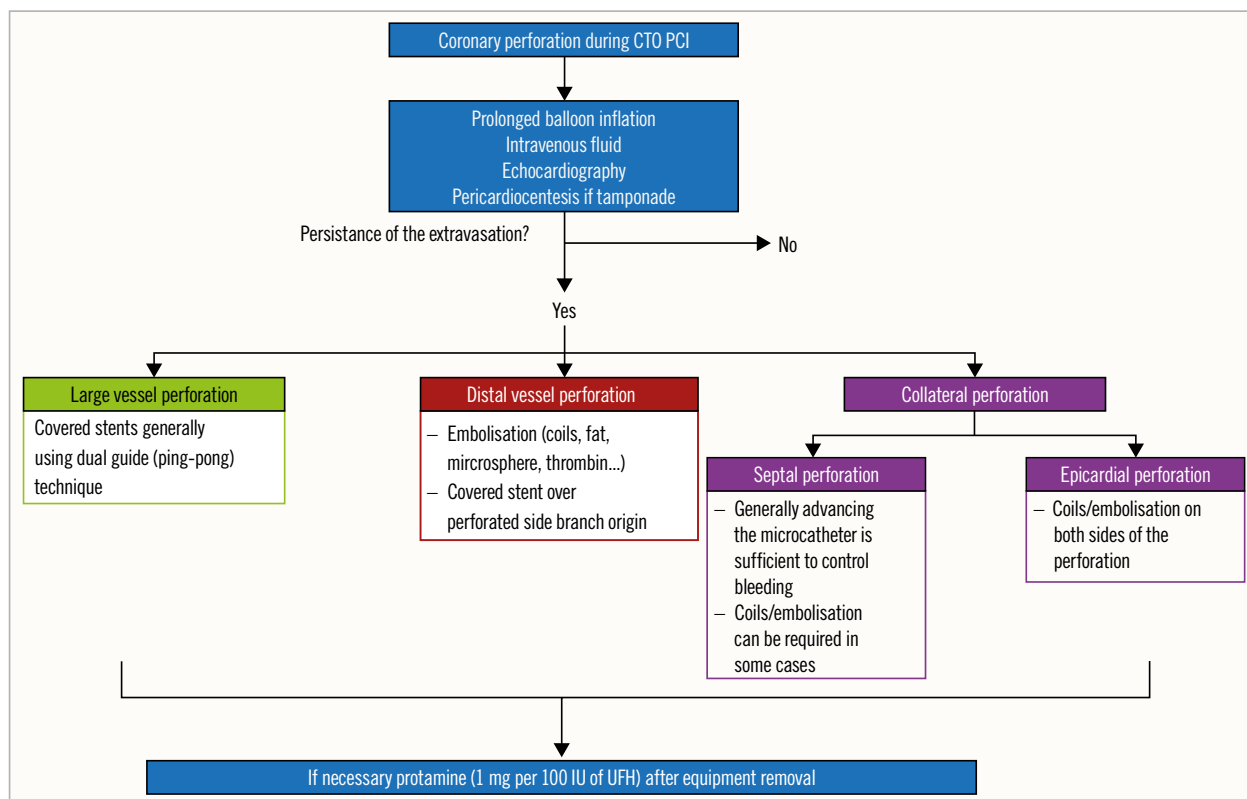
### CTO in particular settings

**Supplementary Appendix 5** is dedicated to CTO PCI in the following particular settings: CTO associated with bifurcation lesions<sup>76-78</sup>, in-stent CTO<sup>79-83</sup> and CTO patients with low left ventricular ejection fraction (LVEF)<sup>27,84-86</sup>.

### Immediate outcome, complications and safety issues

The results of opening a CTO are mainly operator-dependent as well as being driven by a few patient- and morphology-related

parameters. Our experience, now with far more than 20,000 procedures in the monitor-reviewed online registry of the EuroCTO club, shows that operators who performed more than 300 CTOs and maintain an annual procedure number of at least 50 cases will have a success rate of more than 85%, which is still lower than that of non-occlusive lesions<sup>51</sup>. As success rates have increased during recent years, the rate of major complications has decreased to less than 2% and appears close to that of PCI of non-occluded coronary arteries<sup>62</sup>. Periprocedural myocardial injury discovered by measurement of cardiac biomarkers may occur in 5-10% of the patients, is more common with the retrograde approach and is associated with worse clinical outcome at follow-up<sup>87</sup>. Aortic coronary dissection may occur in <1% of CTO PCI attempts<sup>88</sup>; the therapeutic strategy and outcome depend on the rapidity of the entry point sealing and the degree of extension of the dissection<sup>89</sup>. Donor vessel injury during retrograde CTO PCI requires rapid identification and management, since it is frequently associated with extensive ischaemia and haemodynamic instability<sup>90</sup>. Small perforations and pericardial effusions are more likely to occur (3-5%)<sup>51,89</sup>, but are uneventful if addressed rapidly and properly<sup>89-93</sup>. **Figure 4** and **Supplementary Appendix 6** focus on the management of coronary perforations during CTO PCI attempts.



**Figure 4.** Management of coronary perforation in CTO PCI. CTO: chronic total occlusion; UFH: unfractionated heparin; PCI: percutaneous coronary intervention

The section on radiation and contrast use<sup>94-97</sup> can be found in **Supplementary Appendix 7**.

### Dual antiplatelet therapy (DAPT) after CTO PCI

Dual antiplatelet therapy (DAPT) for at least six months is currently recommended post-stenting in patients with stable ischaemic heart disease (class I recommendation)<sup>98</sup>. Prolonged (up to 30 months) DAPT duration may be considered (class IIb recommendation) in patients who have undergone complex PCI<sup>98</sup>. The optimal duration of DAPT in patients who underwent CTO PCI, considered to be at higher ischaemic risk, remains unknown. In a meta-analysis of six RCTs, Giustino et al<sup>99</sup> showed that longer DAPT duration after PCI (>12 months) was not associated with improved clinical outcomes in CTO patients, differently from other subsets of complex non-CTO PCI, such as long stent length (>60 mm), two-stent bifurcation technique and  $\geq 3$  stents implanted. In another retrospective study, Lee et al<sup>100</sup> showed no differences in the incidence of major adverse cardiac and cerebrovascular events or moderate to severe bleeding between CTO patients taking >12-month DAPT and those switched to single antiplatelet therapy after 12 months.

Hence, in the absence of strong clear evidence, DAPT in CTO patients undergoing PCI should be prescribed on a tailored (case-by-case) basis and the duration should be indicated according to the clinical presentation and the assessment of both ischaemic and bleeding risks<sup>98</sup>.

### How to set a CTO programme

**Supplementary Appendix 8** focuses on the learning/training process in CTO PCI as well as centre requirements and centre/operator qualifications.

### Conclusion

During recent years, major advances have been achieved in the field of CTO PCI. The current updated consensus summarises the contemporary European practice in CTO PCI influenced by the development of dedicated material and the growing expertise among European CTO operators. The aim of the EuroCTO Club is to contribute actively to the training of interventional cardiologists in contemporary CTO techniques in order to achieve high levels of success, low rates of complication and to improve the outcome of CTO patients.

### Conflict of interest statement

L. Azzalini reports research grants from Abbott Vascular, ACIST Medical Systems, Guerbet, and Terumo, and honoraria from Guerbet, Terumo and Sahajanand Medical Technologies. A. Avran reports honoraria from Abbott Vascular, Boston Scientific, Biosensors, Terumo and Biotronik for teaching courses and proctoring. A. Gershlick has received travel sponsorship and speaker's fees from Abbott Vascular and Medtronic. C. Di Mario reports speaker's fees from Philips Volcano. The other authors have no conflicts of interest to declare.

## References

The complete list of references can be found in the online version of this paper.

## Supplementary data

**Supplementary Appendix 1.** Overview of the characteristics and use of some microcatheters.

**Supplementary Appendix 2.** Support catheters and guide extension catheters.

**Supplementary Appendix 3.** Intravascular ultrasound (IVUS).

**Supplementary Appendix 4.** Optical coherence tomography (OCT).

**Supplementary Appendix 5.** CTO and bifurcation lesions.

**Supplementary Appendix 6.** Coronary perforations and their management in CTO PCI.

**Supplementary Appendix 7.** Radiation and contrast use.

**Supplementary Appendix 8.** Learning and training in CTO PCI.

**Supplementary Table 1.** An overview of CTO guidewires.

**Supplementary Table 2.** Available dual lumen microcatheters and support catheters for CTO PCI.

**Supplementary Table 3.** Guide extension catheters.

*The supplementary data are published online at:*

*<https://eurointervention.pronline.com/>*

*[doi/10.4244/EIJ-D-18-00826](https://doi.org/10.4244/EIJ-D-18-00826)*



## **Supplementary data**

### **Supplementary Appendix 1. Overview of the characteristics and use of some microcatheters.**

#### **Corsair and Corsair Pro**

The Corsair microcatheter (Asahi Intecc) is composed of eight thin wires wound with two larger wires, to facilitate torque transmission. The inner lumen is lined with a polymer allowing contrast injection and wire advancement. The distal 60 cm are coated with a hydrophilic polymer to improve crossability. A platinum marker coil is placed 5 mm from the tip.

In the Corsair Pro (Asahi Intecc) the distal radiopaque marker band was removed, the tip flexibility was enhanced, and the hub was redesigned to encompass the proximal section of the catheter, reducing the likelihood of guidewire kinking and entrapment.

The Corsair catheter can be advanced by rotating in either direction, although better torque transmission is obtained with counter-clockwise rotation. However, the Corsair should not be over-rotated (>10 consecutive turns without release), as this can lead to catheter deformation and entrapment, and fracture proximal to the catheter tip, or result in the wire binding to the microcatheter (Corsair “fatigue”).

#### **Caravel**

The Caravel microcatheter (Asahi Intecc) was designed for crossing small and tortuous collaterals. It has a very low distal tip profile, a braided shaft and low distal shaft profile with a hydrophilic coating. It can be either advanced with forward push or rotated to cross tortuous collaterals. Importantly, aggressive rotation and advancement should be avoided because it may strain the distal tip connection to the shaft and result in fracturing of the Caravel tip.

#### **Finecross**

The Finecross (Terumo) microcatheter is very flexible and navigates well through tortuosity thanks to its low crossing profile. Its stainless steel braid tends to enhance its torquability; a distal marker is located 0.7 mm from the tip of the microcatheter. The Finecross is generally advanced using forward push; however, a combination of push and rotation can also facilitate its advancement.

## **MicroCross 14 and MicroCross 14ES**

The MicroCross 14 (Roxwood Medical [now BTG]) microcatheter is the longest (155 cm long) and one of the lowest crossing profile microcatheters (1.6 Fr distal tip) available in the market. It has variable pitch braid, a hydrophilic coating and is designed to advance mainly by pushing. The MicroCross 14 is more flexible for advancing through tortuosity or for retrograde approach, while the MicroCross 14ES (extra support) is more suitable for enhanced antegrade crossing.

## **Turnpike, Turnpike LP, Turnpike Spiral, Turnpike Gold**

The Turnpike (Vascular Solutions) has a dual-layer bidirectional coil that facilitates torque transmission while allowing flexibility and preventing kinking. It also has a soft, tapered tip suitable for crossing collaterals.

Turnpike is the standard catheter with a 1.6 Fr outer diameter at the distal tip and 2.6 Fr outer distal shaft diameter. Turnpike LP is a lower-profile version with a 1.6 Fr outer diameter at the distal tip and 2.2 Fr outer distal shaft diameter; it is particularly suitable for crossing very tortuous collaterals (septals, epicardials). The Turnpike Spiral has a distal nylon coil, which “anchors” the microcatheter after advancement and makes it ideal to cross difficult collaterals that might sustain a certain degree of injury (septals and bypass grafts). The Turnpike Gold has a gold-plated, threaded metallic tip and distal nylon coil to increase trackability. Similar to the Tornus (Asahi Intecc), the Turnpike Spiral and Turnpike Gold are well suited for crossing balloon uncrossable lesions. All Turnpike microcatheters are available in 135 and 150 cm lengths, except the Turnpike Gold, which is only available in the 135 cm length.

The Turnpike and Turnpike LP catheters can be rotated in either direction, whereas the Turnpike Spiral and Turnpike Gold are rotated clockwise to advance and counter-clockwise for withdrawal (opposite direction compared with the Tornus catheter).

## **Supplementary Appendix 2. Support catheters and guide extension catheters**

### **Support catheters**

The support catheters are dedicated devices that have a stabilising self-expanding scaffold (MultiCross and CenterCross; Roxwood Medical [now BTG]), an atraumatic elastomeric balloon (Prodigy; Radius Medical) or nitinol struts (NovaCross; Nitiloop) that are deployed proximal to the target CTO lesion. These systems were designed to increase the backup support and the penetration force to cross the proximal cap and traverse through the occlusion. However, their use remains not yet consensual among CTO experts.

### **Guide extension catheters**

Guide extension catheters (GEC) were initially introduced to facilitate device delivery in non-CTO PCI. They can be useful for increasing support during antegrade approach, but also for facilitating stent delivery in tortuous and calcified CTOs. During retrograde approach, mainly the reverse CART technique, GEC can facilitate retrograde wire advancement into the antegrade guiding catheter (by moving the “base of operations” closer to the retrograde gear), enabling wire externalisation (guide extension-facilitated retrograde approach). Most recently, 5 Fr GEC have been commercially available (Guidion; IMDS), enabling a trapping technique inside 8 Fr guiding catheters during single guide retrograde approach. A novel GEC with capability of wire trapping has lately been introduced to facilitate further the exchange of interventional devices during CTO PCI (TrapLiner; Teleflex) and became commercially available in Europe in March 2018.

**Supplementary Table 3** summarises the currently available guide extension catheters.

### **Supplementary Appendix 3. Intravascular ultrasound (IVUS)**

Randomised trials have demonstrated that IVUS improves the outcome of CTO PCI in terms of MACE and definite/probable stent thrombosis [64,65], probably thanks to better stent optimisation. Moreover, IVUS has essential roles in both antegrade and retrograde approaches. In the antegrade approach, IVUS has multiple uses, particularly in case of stumpless CTO lesions with proximal cap ambiguity [62]. The IVUS probe can be advanced into a side branch, and during pullback the precise location and morphologic characteristics of the proximal cap of the occlusion can be identified. Thus, through an on-line IVUS guidance, the CTO wire position can be monitored and the entry of the guidewire (ideally centrally) in the proximal cap can be documented. A second use of IVUS is for antegrade re-entry from subintimal space. In this very complex situation, after a previous failed re-entry attempt, the IVUS probe should be inserted on the subintimal guidewire, in order to identify the correct direction for a stiffer guidewire to puncture and to gain the true lumen distally to the occlusion.

In retrograde approach, the IVUS probe, advanced on an antegrade guidewire, can be useful in two situations: retrograde guidewire crossing and reverse CART technique. In the retrograde wire crossing IVUS could be useful in the ostial occlusions or bifurcations with blunt stump. The IVUS probe should be placed immediately in the very ostial segment to visualise the exact location of the retrograde guidewire and its re-entry in the true lumen. The IVUS evaluation is crucial, in particular in case of ostial left anterior descending or circumflex CTO to avoid left main dissection or side branch occlusion. When retrograde guidewire crossing is unsuccessful, an antegrade subintimal dilation to create a connection channel in the same space between antegrade and retrograde guidewires is mandatory to achieve success. In such a situation, IVUS permits the evaluation of antegrade and retrograde guidewire position (both intimal and subintimal or in different spaces), and the selection of the appropriate balloon sizing for medial disruption. In addition, IVUS can be helpful to select the appropriate position for creating connection (more proximally or more distally) when an initial reverse CART strategy is unsuccessful due to severe calcification [62].

#### **Supplementary Appendix 4. Optical coherence tomography (OCT)**

Optical coherence tomography (OCT) provides high-resolution cross-sectional images that could help in assessing the degree of intima, media, and fibrous cap thickness of an atherosclerotic plaque and give details of plaque morphology. OCT can further be used to determine lesion length, vessel diameter, length of subintimal track, and the constituents of the arterial wall [66]. Hence, OCT might be used to determine stent length more accurately, limiting inadequate stent expansion or incomplete stent strut apposition, thus minimising the risk for stent thrombosis or restenosis. Indeed, high rates of stent strut malapposition and incomplete stent strut coverage have been reported after CTO PCI [67].

Nonetheless, the lack of clinical data on OCT use in CTO PCI in addition to the need for repeated contrast injections and pullbacks are factors against extending its use in CTO procedures, considering that this can be particularly deleterious in cases where dissection/re-entry techniques have been performed (extension of dissection planes).



## **Supplementary Appendix 5. CTO and bifurcation lesions**

Bifurcation lesions are found in approximately 25-30% in the context of CTO PCI [76,77], and represent an additional challenge for the interventional cardiologist. The presence of a bifurcation lesion within the CTO target vessel was demonstrated to increase the complexity of the procedure and may lead to less angiographic success and more periprocedural complications [77]. Although it is well established that the one-stent technique is the gold standard for bifurcation treatment in non-CTO lesions, the appropriate strategy to manage bifurcation in the context of CTO PCI remains debatable. Ojeda et al [76] claimed that bifurcation lesions in CTO can be approached similarly to regular bifurcation lesions, for which provisional stenting is considered the technique of choice. However, the side branch stenting rate seems to be higher (15.6%) than in previous non-CTO series [76]. After adjusted analysis, there were no differences in midterm outcomes between the T-provisional stenting (1-stent technique) and two-stent techniques [76]. To the best of our knowledge, only one randomised study has investigated the appropriate strategy for bifurcation lesions located within a CTO vessel. Baystrukov et al [78] showed that, in comparison with T-provisional stenting, the mini-crush technique appeared to be associated with better one-year clinical and angiographic outcomes, particularly when used to treat bifurcation lesions located within the CTO body or close to the proximal or the distal cap ( $\leq 5$  mm).

The presence of a dissection affecting the bifurcation site in CTO PCI might prevent side branch wiring; in such a scenario dual-lumen microcatheters could be of interest to manage the bifurcation lesion appropriately. Otherwise, in case of the antegrade dissection re-entry technique with no possibility to achieve re-entry before SB take-off, the retrograde approach might be an interesting alternative to preserve both branches.

### **In-stent CTO**

In-stent CTOs represent 11-12% of all CTO PCIs [79,80]. These procedures are often more complex than those in unstented vessels, due to the resistance offered by restenotic fibrocalcific tissue and the close proximity of stent struts with microcatheters, wires and balloons, as well as the need to maintain a within-stent track. In-stent CTOs present similar angiographic complexity compared with de novo occlusions [79]. The CrossBoss catheter (Boston Scientific) is particularly useful to cross long stented segments quickly, avoiding exit into the subadventitial space [81]. Success rates for in-stent CTO PCI were historically lower

than for *de novo* lesions but have recently reached similar figures (86-87% vs. 87-90% [79,80]).

However, long-term follow-up reveals a threefold increase in the risk of target vessel revascularisation for patients with in-stent CTOs, mirroring similar findings in non-occlusive disease, where PCI for in-stent restenosis had been identified as a predictor of future restenotic events [79]. For this reason, use of intravascular imaging to identify the cause of restenosis, guide stent choice, and optimise the final result is of the utmost importance.

Although a within-stent track is the recommended approach to recanalise in-stent CTOs, sometimes this is impossible to achieve, and subadventitial crossing with subsequent crushing might represent the only feasible option [82]. This approach has recently been proposed to treat very complex occlusions, after failure of within-stent techniques. Subadventitial crossing appears to be effective and safe, and is associated with acceptable outcomes on mid-term follow-up, which are similar to those achieved using within-stent techniques [83]. However, subadventitial crossing and crushing of occluded stents should be considered only as a last resort by very experienced operators, since it is technically demanding, not devoid of complications (e.g., perforation), and its long-term outcomes are poorly characterised.

### **CTO in patients with impaired left LVEF**

Current guidelines and appropriate use criteria for myocardial revascularisation do not provide any recommendation regarding the most appropriate management strategy in CTO patients with low LVEF [27]. Severe ischaemic left ventricular dysfunction is associated with higher morbidity, an increased risk of sudden death due to ventricular arrhythmias, poor quality of life, and frequent re-hospitalisation for heart failure. Successful CTO PCI in these patients is associated with significant improvement of LVEF and symptoms at six-month follow-up and also improves the midterm clinical outcome [84]. Although CTO PCI represents an efficient as well as safe strategy in patients with low LVEF, important precautions have to be taken before treating this subgroup of patients. Particularly in patients with acute left heart failure and/or retrograde PCI over a last remaining vessel, additional haemodynamic support such as an intra-aortic balloon pump, Impella<sup>®</sup> device (Abiomed, Danvers, MA, USA) or even an extracorporeal life support system may be mandatory during the procedure [85,86].

## **Supplementary Appendix 6. Coronary perforations and their management in CTO PCI**

Coronary perforation represents one of the most feared complications of CTO PCI, as it can be responsible for pericardial effusion and tamponade, requiring emergency pericardiocentesis, and in some cases cardiac surgery. Coronary perforation is generally located within the target CTO vessel (either the main vessel or its distal segment) or in the collateral supplying the CTO territory. Although coronary perforations are relatively common [89,90], the risk of tamponade is low (~0.3%) [89]. This risk is higher with retrograde CTO PCI (1.3%) [91], particularly when epicardial collaterals are used [89].

While small perforations can be managed conservatively, those causing pericardial effusion often require appropriate measures to stop bleeding into the pericardium.

Generally, a semi-compliant balloon (sized the same as the vessel) should immediately be inflated (8-10 mm) proximal to the perforation. In case of haemodynamic instability, immediate pericardiocentesis is required, while small size pericardial effusion (without haemodynamic collapse) is preferably managed conservatively. Anticoagulation reversal (generally with 1 mg protamine per 100 IU of UFH) should not be performed until the equipment removal to avoid catheters and vessel thrombosis.

If the extravasation persists in spite of prolonged balloon inflation, further measures [92,93] should be applied, depending on the vessel size and the perforation location, as shown in **Figure 2**.

If different percutaneous attempts fail, cardiac surgery remains the last alternative to stop bleeding.

Importantly, coronary perforations in patients with prior CABG can be lethal as they may lead to loculated effusions that compress cardiac structures and are challenging to drain percutaneously [91].

## **Supplementary Appendix 7. Radiation and contrast use**

We strongly believe that radiation injury to the skin (reported to be 0.42%) [94], as well as contrast-induced kidney injury (CIN) that probably occurs in up to 10% [95] are both underreported complications. The average amount of radiation dose in CTO procedures measured as air kerma is 3-6 Gy and 2-4 times that of non-CTO lesions PCI [96], while contrast load averages 350 ml, which is 150-200 ml more than required for PCI of non-occlusive disease [97]. Excessive dye consumption and radiation exposure are both mainly driven by lesion complexity, operator experience, radiation habits and cath lab settings (low pulse frequencies, e.g., 7.5 pulses per second instead of 15-30). Since the amount of dye that will be required may not be predictable, we recommend i.v. hydration with isotonic saline one day prior to and 12 hours after the procedure for all patients with chronic kidney disease (eGFR <60 ml/min/1.73 m<sup>2</sup>) and consider it also for CTO patients irrespective of their eGFR.

## **Supplementary Appendix 8. Learning and training in CTO PCI**

Learning CTO PCI can be achieved either through a formal fellowship programme or through “on the job” training, while practising. Both can provide excellent training; however, high procedural volume is required as it does correlate with skills [50].

A multifaceted approach to learning CTO PCI is advised. Reading CTO-related literature represents the knowledge base upon which all subsequent learning should be built. Attending CTO courses and meetings allows sharing of experience and challenging scenarios delivered by expert operators, as well as facilitating professional networking with experts. Moreover, interaction through social media and online communities promotes constant sharing of experiences with peers. Finally, getting proctored by experienced CTO interventionalists (“on the job training”) is an invaluable resource for learning CTO PCI.

The basic set of techniques for developing expertise in CTO PCI is represented by antegrade wire escalation. Then, the operator interested in developing his/her CTO skills further can embrace two paths: ADR or the retrograde approach. ADR is favoured by the so-called “hybrid” operators and represents a technically less demanding approach compared with retrograde techniques. Embracing the retrograde approach requires acquisition of specific material (microcatheters, wires, snares, etc.), learning several different techniques to deal with each step from collateral channel engagement to wire externalisation, as well as being prepared to deal with complications (e.g., perforation, tamponade, donor vessel ischaemia, etc.). With regard to collateral channel choice, it might be advisable to start tackling bypass grafts and septal channels first, before embarking on retrograde CTO PCI via epicardial collaterals, which present higher risk for rupture.

### **Centre requirements**

At the logistics level, deliberate support from the hospital administration is key to setting up a successful CTO PCI programme. This involves availability to acquire dedicated material for CTO intervention, designation of specific CTO operators (one or ideally two) and “CTO days”, and an outreach programme to build and foster a strong network of referring physicians [2]. Cath lab leadership should strive to promote training not only among CTO PCI interventionalists, but also among nurses and technicians. Specific protocols to manage CTO-specific issues during the procedure should be set up and implemented. These include: checking activated clotting time at regular intervals (e.g., every 30 minutes), warning the

operator(s) when specific thresholds of contrast volume and radiation dose are reached, managing patients' complaints related to long procedures (back pain, urination, etc.), and so on. While specific gear (e.g., retrograde wires, snares, etc.) related to specific approaches of CTO PCI are not necessarily must-haves for all CTO PCI programmes (e.g., those initially willing to focus on antegrade techniques exclusively), it is mandatory that every cath lab where CTO recanalisation is performed owns certain devices needed to solve life-threatening complications (and the skills needed to use them). These include coils and covered stents to deal with perforation, pericardiocentesis kit to relieve tamponade, and mechanical circulatory support devices (at least intra-aortic balloon pump) for assistance in case of ischaemic complications. Finally, on-site surgical back-up ought not to be mandatory, but the appropriateness of indications must be confirmed by the regular involvement of a "Heart Team" including cardiac surgeons.

### **Centre/operator expertise**

A direct relationship between case volume and success rate exists for CTO PCI. In fact, it has been shown that at least 100 CTO PCIs/year must be performed by an operator to reach a success rate >90% [50]. While achieving such high volumes might be challenging for most institutions and operators, we strongly believe that centres and operators performing fewer than 30 CTO procedures annually should refer their CTO patients to a more experienced operator [2].

Retrograde techniques should be reserved for experienced operators (i.e., those performing >50 per year). A minimum of 50 retrograde procedures (25 as second operator and 25 as first under supervision) might be advised before a cardiologist becomes an independent retrograde operator [2].

# **Corrigendum to “Percutaneous recanalisation of chronic total occlusions: 2019 consensus document from the EuroCTO Club”**

Marouane Boukhris MD<sup>1,2</sup>, Georgios Sianos<sup>3</sup>, Alfredo R Galassi MD<sup>4</sup>.

1 Centre Hospitalier de l'Université de Montréal (CHUM), Montréal, Québec, Canada

2 Faculty of Medicine of Tunis, University of Tunis El Manar, Tunisia

3 AHEPA University General Hospital of Thessaloniki, 1st Cardiology Department,  
Thessaloniki, Greece

4 Department of Health Promotion, Mother and Child Care, Internal Medicine and medical specialities, University of Palermo, Italy

## **Corresponding author:**

Alfredo R Galassi

Department of Health Promotion, Mother and Child Care, Internal Medicine and medical specialities, University of Palermo, Italy

E-mail: argalassi@gmail.com

We would like to thank Dr Fathelbab and Dr Abdelgany for their appropriate comments.

Accordingly, we have now corrected the Online Supplemental Material 1 of the EuroCTO club Consensus

## Online Supplemental Material 1. An overview of CTO guidewires

Guidewire		Wire diameter (inch/mm)	Tip stiffness (g)	Polymeric	Hydrophilic tip	Hydrophilic shaft
Abbott Vascular	Cross-It™ 100	0.014"/0.35 mm Tapered tip 0.010"/0.26 mm	1.7	N	N	N
	Cross-It™ 200	0.014"/0.35 mm Tapered tip 0.010"/0.26 mm	3	N	N	N
	Cross-It™ 300	0.014"/0.35 mm Tapered tip 0.010"/0.26 mm	4	N	N	N
	Cross-It™ 400	0.014"/0.35 mm Tapered tip 0.010"/0.26 mm	6	N	N	N
	Whisper LS, MS, ES™ (Light, Medium, Extra Support)	0.014"/0.35 mm	0.8,1.0 and 1.2	Y	Y	N
	Pilot™ 50	0.014"/0.35 mm	1.5	Y	Y	N
	Pilot™ 150 and 200	0.014"/0.35 mm	2.7 and 4.1	Y	Y	Y
	Progress 40	0.014"/0.35 mm	4.8	N	N	Y
	Progress 80	0.014"/0.35 mm	9.7	N	N	Y
	Progress 120	0.014"/0.35 mm	13.9	N	N	Y
	Progress 140T	0.014"/0.35 mm Tapered tip 0.010"/0.26 mm	12.5	N	N	Y
	Progress 200T	0.014"/0.35 mm Tapered tip 0.009"/0.23 mm	13.9	N	N	Y
Asahi Intecc Corporation	Intermediate™	0.014"/0.35 mm	3	N	N	N
	Miraclebros™	0.014"/0.35 mm	3, 4.5, 6, 9 and 12	N	N	N
	Confianza™	0.014"/0.35 mm Tapered tip 0.009"/0.23 mm	9	N	N	N
	Confianza™ Pro	0.014"/0.35 mm Tapered tip 0.009"/0.23 mm	9.3 and 12.4	N	N	Y
	Confianza™ Pro "8-20"	0.014"/0.35 mm Tapered tip 0.008"/0.20 mm	20	N	N	Y



	Fielder™	0.014"/0.35 mm	1	Y	Y	N
	Fielder™ FC	0.014"/0.35 mm	0.8	Y	Y	N
	Fielder™ XT	0.014"/0.35 mm Tapered tip 0.009"/0.23 mm	0.8	Y	Y	N
	Fielder™ XT-A	0.014"/0.35 mm Tapered tip 0.010"/0.26 mm	1.0	Y	Y	N
	Fielder™ XT-R	0.014"/0.35 mm Tapered tip 0.010"/0.26 mm	0.6	Y	Y	N
	Decillion FL™	0.010"/0.26 mm	0.8	N	Y	N
	Decillion HS™	0.010"/0.26 mm	1.5	Y	Y	N
	Decillion MD™	0.010"/0.26 mm	3.0	N	Y	N
	SION™	0.014"/0.35 mm	0.7	N	Y	Y
	SION blue™	0.014"/0.35 mm	0.5	N	N	Y
	SION blue ES™	0.014"/0.35 mm	0.5	N	N	Y
	SION black™	0.014"/0.35 mm	0.8	Y	Y	Y
	SUOH 0.3™	0.014"/0.35 mm	0.3	Y	Y	Y
	GAIA First	0.014"/0.35 mm Tapered tip 0.010"/0.26 mm	1.7	N	Y	Y
	GAIA Second	0.014"/0.35 mm Tapered tip 0.011"/0.28 mm	3.5	N	Y	Y
	GAIA Third	0.014"/0.35 mm Tapered tip 0.012"/0.30 mm	4.5	N	Y	Y
	RG3	0.010"/0.26 mm	3.0	N	Y	Y
Boston Scientific	Choice™ PT and PT2 LS and MS	0.014"/0.35 mm	2.1	Y	Y	Y
	PT Graphix™ Intermediate Graphix P2™ LS and MS	0.014"/0.35 mm	1.7 and 2.9	Y	Y	Y
	Marvel™	0.014"/0.35 mm	0.9	N	Y	N

	Samurai™	0.014"/0.35 mm	0.5	N	Y (reduced on distal 1cm)	N
	Samurai RC™	0.014"/0.35 mm	0.5	N	Y	N
	Fighter™	0.014"/0.35 mm Tapered tip 0.009"/0.23 mm	1.2	Y	Y	Y
	Hornet™	0.014"/0.35 mm Tapered tip 0.008"/0.20 mm	1.0	N	Y	N
	Hornet 10™	0.014"/0.35 mm Tapered tip 0.008"/0.20 mm	10	N	Y	N
	Hornet 14™	0.014"/0.35 mm Tapered tip 0.008"/0.20 mm	14	N	Y	N
Cordis/ Johnson & Johnson	Shinobi™	0.014"/0.35 mm	7	Y	Y	N
	Shinobi™ Plus	0.014"/0.35 mm	6.8	Y	Y	N
Medtronic	Persuader™ 3 and 6	0.014"/0.35 mm	3 and 6	N	B	N
	Persuader™ 9	0.014"/0.35 mm Tapered tip 0.011"/0.28 mm	9	N	B	N
Terumo	Crosswire NT™	0.014"/0.35 mm	7.7	N	Y	N
	Crosswire™ Hard type 40	0.014"/0.35 mm	15.6	N	Y	Y
	Crosswire™ Hard type 80	0.014"/0.35 mm	26.7	N	Y	Y
	Runthrough™ NS Floppy	0.014"/0.35 mm	1	N	Y	N
	Runthrough™ NS Hypercoat	0.014"/0.35 mm	1	Y	Y	Y
	Runthrough™ NS Intermediate	0.014"/0.35 mm	3.6	N	Y	N
	Glidewire™ Gold Neuro	0.011"/0.27 mm	1	N	Y	Y

### Abbreviations

*B=both; CTO=chronic total occlusion; N=No; Y=Yes.*

**Supplementary Table 2. Available dual lumen microcatheters and support catheters for CTO PCI.**

<b>Manufacturer</b>	<b>Catheter</b>	<b>Length</b>	<b>Distal shaft outer diameter</b>
IMDS	NHancer Rx	135 cm	2.6 Fr
Kaneka	Crusade	140 cm	1.3 Fr distal tip 3.1 Fr crossing profile
Terumo	FineDuo	140 cm	
Teleflex	Twin-Pass and Twin-Pass Torque	140 cm	1.9 Fr distal tip 3 Fr crossing profile
Asahi Intecc	SASUKE	145 cm	1.5 Fr distal tip 2.5 Fr crossing profile

CTO: chronic total occlusion; PCI: percutaneous coronary intervention

**Supplementary Table 3. Guide extension catheters.**

<b>Guide extension catheter</b>	<b>Sizes (Fr)</b>	<b>Guide segment</b>	<b>Working length</b>	<b>Coating</b>	<b>Characteristics</b>
<b>Guidion Hydro (IMDS, the Netherlands)</b>	5, 6, 7, 8 Fr	25 cm	150 cm	Hydrophilic coating	True visible soft tip. Low distal shaft friction. Lumen with flat wire coil reinforcement.
<b>GUIDEZILLA (Boston Scientific, USA)</b>	6, 7, 8 and 6 Fr long	25 cm on 6 Fr, 7 Fr, 8 Fr  (40 cm on 6 Fr long)	150 cm	Hydrophilic coating	Marker 2 mm from distal end. Large-profile proximal shaft. Lumen with braid reinforcement.
<b>GuideLiner (Teleflex, USA)</b>	5, 5.5, 6, 7, 8 Fr and 6 Fr long	25 cm on 6 Fr, 7 Fr, 8 Fr  (40 cm on 6 Fr long)	150 cm	Hydrophobic coating	Marker 2 mm from distal end. Lumen with flat wire coil reinforcement.

## REFERENCES

1. Di Mario C, Werner GS, Sianos G, Galassi AR, Buttner J, Dudek D, Chevalier B, Lefevre T, Schofer J, Koolen J, Sievert H, Reimers B, Fajadet J, Colombo A, Gershlick A, Serruys PW, Reifart N. European perspective in the recanalisation of Chronic Total Occlusions (CTO): consensus document from the EuroCTO Club. *EuroIntervention*. 2007;3:30-43.
2. Sianos G, Werner GS, Galassi AR, Papafaklis MI, Escaned J, Hildick-Smith D, Christiansen EH, Gershlick A, Carlino M, Karlas A, Konstantinidis NV, Tomasello SD, Di Mario C, Reifart N; EuroCTO Club. Recanalisation of chronic total coronary occlusions: 2012 consensus document from the EuroCTO club. *EuroIntervention*. 2012;8:139-45.
3. Råmunddal T, Hoebers LP, Henriques JP, Dworeck C, Angerås O, Odenstedt J, Ioanes D, Olivecrona G, Harnek J, Jensen U, Aasa M, Jussila R, James S, Lagerqvist B, Matejka G, Albertsson P, Omerovic E. Chronic total occlusions in Sweden--a report from the Swedish Coronary Angiography and Angioplasty Registry (SCAAR). *PLoS One*. 2014;9:e103850.
4. Tomasello SD, Boukhris M, Giubilato S, Marzà F, Garbo R, Contegiacomo G, Marzocchi A, Niccoli G, Gagnor A, Varbella F, Desideri A, Rubartelli P, Cioppa A, Baralis G, Galassi AR. Management strategies in patients affected by chronic total occlusions: results from the Italian Registry of Chronic Total Occlusions. *Eur Heart J*. 2015;36:3189-98.
5. Azzalini L, Jolicœur EM, Pighi M, Millán X, Picard F, Tadros VX, Fortier A, L'Allier PL, Ly HQ. Epidemiology, Management Strategies, and Outcomes of Patients With Chronic Total Coronary Occlusion. *Am J Cardiol*. 2016;118:1128-35.
6. Jeroudi OM, Alomar ME, Michael TT, El Sabbagh A, Patel VG, Mogabgab O, Fuh E, Sherbet D, Lo N, Roesle M, Rangan BV, Abdullah SM, Hastings JL, Grodin J, Banerjee S,

Brilakis ES. Prevalence and management of coronary chronic total occlusions in a tertiary Veterans Affairs hospital. *Catheter Cardiovasc Interv.* 2014;84:637-43.

7. Fefer P, Knudtson ML, Cheema AN, Galbraith PD, Osheroov AB, Yalonetsky S, Gannot S, Samuel M, Weisbrod M, Bierstone D, Sparkes JD, Wright GA, Strauss BH. Current perspectives on coronary chronic total occlusions: the Canadian Multicenter Chronic Total Occlusions Registry. *J Am Coll Cardiol.* 2012;59:991-7.

8. Claessen BE, van der Schaaf RJ, Verouden NJ, Stegenga NK, Engstrom AE, Sjauw KD, Kikkert WJ, Vis MM, Baan J Jr, Koch KT, de Winter RJ, Tijssen JG, Piek JJ, Henriques JP. Evaluation of the effect of a concurrent chronic total occlusion on long-term mortality and left ventricular function in patients after primary percutaneous coronary intervention. *JACC Cardiovasc Interv.* 2009;2:1128-34.

9. Sachdeva R, Agrawal M, Flynn SE, Werner GS, Uretsky BF. The myocardium supplied by a chronic total occlusion is a persistently ischemic zone. *Catheter Cardiovasc Interv.* 2014;83:9-16.

10. Galassi AR, Tomasello SD, Crea F, Costanzo L, Campisano MB, Marza F, Tamburino C. Transient impairment of vasomotion function after successful chronic total occlusion recanalization. *J Am Coll Cardiol.* 2012;59:711-8.

11. Werner GS, Surber R, Kueth F, Emig U, Schwarz G, Bahrmann P, Figulla HR. Collaterals and the recovery of left ventricular function after recanalization of a chronic total coronary occlusion. *Am Heart J.* 2005;149:129-37.

12. Jang WJ, Yang JH, Choi SH, Song YB, Hahn JY, Choi JH, Kim WS, Lee YT, Gwon HC. Long-term survival benefit of revascularization compared with medical therapy in patients

with coronary chronic total occlusion and well-developed collateral circulation. *JACC Cardiovasc Interv.* 2015;8:271-9.

13. Werner GS, Ferrari M, Heinke S, Kuethe F, Surber R, Richartz BM, Figulla HR. Angiographic assessment of collateral connections in comparison with invasively determined collateral function in chronic coronary occlusions. *Circulation.* 2003;107:1972-7.

14. Huang CC, Lee CK, Meng SW, Hung CS, Chen YH, Lin MS, Yeh CF, Kao HL. Collateral Channel Size and Tortuosity Predict Retrograde Percutaneous Coronary Intervention Success for Chronic Total Occlusion. *Circ Cardiovasc Interv.* 2018;11:e005124.

15. Werner GS, Surber R, Ferrari M, Fritzenwanger M, Figulla HR. The functional reserve of collaterals supplying long-term chronic total coronary occlusions in patients without prior myocardial infarction. *Eur Heart J.* 2006;27:2406-12.

16. Sachdeva R, Agrawal M, Flynn SE, Werner GS, Uretsky BF. Reversal of ischemia of donor artery myocardium after recanalization of a chronic total occlusion. *Catheter Cardiovasc Interv.* 2013;82:E453-8.

17. Azzalini L, Vo M, Dens J, Agostoni P. Myths to Debunk to Improve Management, Referral, and Outcomes in Patients With Chronic Total Occlusion of an Epicardial Coronary Artery. *Am J Cardiol.* 2015;116:1774-80.

18. Safley DM, Koshy S, Grantham JA, Bybee KA, House JA, Kennedy KF, Rutherford BD. Changes in myocardial ischemic burden following percutaneous coronary intervention of chronic total occlusions. *Catheter Cardiovasc Interv.* 2011;78:337-43.

19. Rossello X, Pujadas S, Serra A, Bajo E, Carreras F, Barros A, Cinca J, Pons-Lladó G, Vaquerizo B. Assessment of Inducible Myocardial Ischemia, Quality of Life, and Functional

Status After Successful Percutaneous Revascularization in Patients With Chronic Total Coronary Occlusion. *Am J Cardiol.* 2015;117:720-6.

20. Safley DM, Grantham JA, Hatch J, Jones PG, Spertus JA. Quality of life benefits of percutaneous coronary intervention for chronic occlusions. *Catheter Cardiovasc Interv.* 2014;84:629-34.

21. Azzalini L, Torregrossa G, Puskas JD, Brilakis ES, Lombardi WL, Karpaliotis D, Nakamura S, Colombo A, Carlino M. Percutaneous revascularization of chronic total occlusions: rationale, indications, techniques, and the cardiac surgeon's point of view. *Int J Cardiol.* 2017;231:90-6.

22. Farooq V, Serruys PW, Garcia-Garcia HM, Zhang Y, Bourantas CV, Holmes DR, Mack M, Feldman T, Morice M, Stähle E, James S, Colombo A, Diletti R, Papafaklis MI, de Vries T, Morel MA, van Es GA, Mohr FW, Dawkins KD, Kappetein A, Sianos G, Boersma E. The negative impact of incomplete angiographic revascularization on clinical outcomes and its association with total occlusions: the SYNTAX (Synergy Between Percutaneous Coronary Intervention with Taxus and Cardiac Surgery) trial. *J Am Coll Cardiol.* 2013;61:282-94.

23. Azzalini L, Candilio L, Ojeda S, Dens J, La Manna A, Benincasa S, Bellini B, Hidalgo F, Chavarría J, Maeremans J, Gravina G, Micciché E, D'Agosta G, Venuti G, Tamburino C, Pan M, Carlino M, Colombo A. Impact of Incomplete Revascularization on Long-Term Outcomes Following Chronic Total Occlusion Percutaneous Coronary Intervention. *Am J Cardiol.* 2018;121:1138-48.

24. Nombela-Franco L, Iannaccone M, Anguera I, Amat-Santos IJ, Sanchez-Garcia M, Bautista D, Calvelo MN, Di Marco A, Moretti C, Pozzi R, Scaglione M, Cañadas V, Sandin-Fuentes M, Arenal A, Bagur R, Perez-Castellano N, Fernandez-Perez C, Gaita F, Macaya C,



Escaned J, Fernández-Lozano I. Impact of Chronic Total Coronary Occlusion on Recurrence of Ventricular Arrhythmias in Ischemic Secondary Prevention Implantable Cardioverter-Defibrillator Recipients (VACTO Secondary Study): Insights From Coronary Angiogram and Electrogram Analysis. *JACC Cardiovasc Interv.* 2017;10:879-88.

25. Canty JM Jr, Suzuki G, Banas MD, Verheyen F, Borgers M, Fallavollita JA. Hibernating myocardium: chronically adapted to ischemia but vulnerable to sudden death. *Circ Res.* 2004;94:1142-9.

26. Galassi AR, Brilakis ES, Boukhris M, Tomasello SD, Sianos G, Karpaliotis D, Di Mario C, Strauss BH, Rinfret S, Yamane M, Katoh O, Werner GS, Reifart N. Appropriateness of percutaneous revascularization of coronary chronic total occlusions: an overview. *Eur Heart J.* 2016;37:2692-700.

27. Neumann FJ, Sousa-Uva M, Ahlsson A, Alfonso F, Banning AP, Benedetto U, Byrne RA, Collet JP, Falk V, Head SJ, Juni P, Kastrati A, Koller A, Kristensen SD, Niebauer J, Richter DJ, Seferovic PM, Sibbing D, Stefanini GG, Windecker S, Yadav R, Zembala MO; ESC Scientific Document Group. 2018 ESC/EACTS Guidelines on myocardial revascularization. *Eur Heart J.* 2019;40:87-165.

28. Christakopoulos GE, Christopoulos G, Carlino M, Jeroudi OM, Roesle M, Rangan BV, Abdullah S, Grodin J, Kumbhani DJ, Vo M, Luna M, Alaswad K, Karpaliotis D, Rinfret S, Garcia S, Banerjee S, Brilakis ES. Meta-analysis of clinical outcomes of patients who underwent percutaneous coronary interventions for chronic total occlusions. *Am J Cardiol.* 2015;115:1367-75.

29. Joyal D, Afilalo J, Rinfret S. Effectiveness of recanalization of chronic total occlusions: a systematic review and meta-analysis. *Am Heart J.* 2010;160:179-87.

30. Lee PH, Lee SW, Park HS, Kang SH, Bae BJ, Chang M, Roh JH, Yoon SH, Ahn JM, Park DW, Kang SJ, Kim YH, Lee CW, Park SW, Park SJ. Successful Recanalization of Native Coronary Chronic Total Occlusion Is Not Associated With Improved Long-Term Survival. *JACC Cardiovasc Interv.* 2016;9:530-8.
31. Henriques JP, Hoehlers LP, Ramunddal T, Laanmets P, Eriksen E, Bax M, Ioanes D, Suttorp MJ, Strauss BH, Barbato E, Nijveldt R, van Rossum AC, Marques KM, Elias J, van Dongen IM, Claessen BE, Tijssen JG, van der Schaaf RJ; EXPLORE Trial Investigators. Percutaneous Intervention for Concurrent Chronic Total Occlusions in Patients With STEMI: The EXPLORE Trial. *J Am Coll Cardiol.* 2016;68:1622-32.
32. Werner GS, Martin-Yuste V, Hildick-Smith D, Boudou N, Sianos G, Gelev V, Rumoroso JR, Erglis A, Christiansen EH, Escaned J, di Mario C, Hovasse T, Teruel L, Bufe A, Lauer B, Bogaerts K, Goicolea J, Spratt JC, Gershlick AH, Galassi AR, Louvard Y; EUROCTO trial investigators. A randomized multicentre trial to compare revascularization with optimal medical therapy for the treatment of chronic total coronary occlusions. *Eur Heart J.* 2018;39:2484-93.
33. Obedinskiy AA, Kretov EI, Boukhris M, Kurbatov VP, Osiev AG, Ibn Elhadj Z, Obedinskaya NR, Kasbaoui S, Grazhdankin IO, Prokhorikhin AA, Zubarev DD, Biryukov A, Pokushalov E, Galassi AR, Baystrukov VI. The IMPACTOR-CTO Trial. *JACC Cardiovasc Interv.* 2018;11:1309-11.
34. Konstantinidis NV, Werner GS, Deftereos S, Di Mario C, Galassi AR, Buettner JH, Avran A, Reifart N, Goktekin O, Garbo R, Bufe A, Mashayekhi K, Boudou N, Meyer-Geßner M, Lauer B, Elhadad S, Christiansen EH, Escaned J, Hildick-Smith D, Carlino M, Louvard Y, Lefèvre T, Angelis L, Giannopoulos G, Sianos G; Euro CTO Club. Temporal

Trends in Chronic Total Occlusion Interventions in Europe. *Circ Cardiovasc Interv.* 2018;11:e006229.

35. Harding SA, Wu EB, Lo S, Lim ST, Ge L, Chen JY, Quan J, Lee SW, Kao HL, Tsuchikane E. A New Algorithm for Crossing Chronic Total Occlusions From the Asia Pacific Chronic Total Occlusion Club. *JACC Cardiovasc Interv.* 2017;10:2135-43.

36. Morino Y, Abe M, Morimoto T, Kimura T, Hayashi Y, Muramatsu T, Ochiai M, Noguchi Y, Kato K, Shibata Y, Hiasa Y, Doi O, Yamashita T, Hinohara T, Tanaka H, Mitsudo K; J-CTO Registry Investigators. Predicting successful guidewire crossing through chronic total occlusion of native coronary lesions within 30 minutes: the J-CTO (Multicenter CTO Registry in Japan) score as a difficulty grading and time assessment tool. *JACC Cardiovasc Interv.* 2011;4:213-21.

37. Alessandrino G, Chevalier B, Lefèvre T, Sanguineti F, Garot P, Untersee T, Hovasse T, Morice MC, Louvard Y. A Clinical and Angiographic Scoring System to Predict the Probability of Successful First-Attempt Percutaneous Coronary Intervention in Patients With Total Chronic Coronary Occlusion. *JACC Cardiovasc Interv.* 2015;8:1540-8.

38. Galassi AR, Boukhris M, Azzarelli S, Castaing M, Marzà F, Tomasello SD. Percutaneous Coronary Revascularization for Chronic Total Occlusions: A Novel Predictive Score of Technical Failure Using Advanced Technologies. *JACC Cardiovasc Interv.* 2016;9:911-22.

39. Christopoulos G, Kandzari DE, Yeh RW, Jaffer FA, Karpaliotis D, Wyman MR, Alaswad K, Lombardi W, Grantham JA, Moses J, Christakopoulos G, Tarar MNJ, Rangan BV, Lembo N, Garcia S, Cipher D, Thompson CA, Banerjee S, Brilakis ES. Development and Validation of a Novel Scoring System for Predicting Technical Success of Chronic Total Occlusion Percutaneous Coronary Interventions: The PROGRESS CTO (Prospective Global

Registry for the Study of Chronic Total Occlusion Intervention) Score. *JACC Cardiovasc Interv.* 2016;9:1-9.

40. Yu CW, Lee HJ, Suh J, Lee NH, Park SM, Park TK, Yang JH, Song YB, Hahn JY, Choi SH, Gwon HC, Lee SH, Choe YH, Kim SM, Choi JH. Coronary Computed Tomography Angiography Predicts Guidewire Crossing and Success of Percutaneous Intervention for Chronic Total Occlusion: Korean Multicenter CTO CT Registry Score as a Tool for Assessing Difficulty in Chronic Total Occlusion Percutaneous Coronary Intervention. *Circ Cardiovasc Imaging.* 2017 Apr;10(4).

41. Opolski MP, Achenbach S, Schuhbäck A, Rolf A, Möllmann H, Nef H, Rixe J, Renker M, Witkowski A, Kepka C, Walther C, Schlundt C, Debski A, Jakubczyk M, Hamm CW. Coronary computed tomographic prediction rule for time-efficient guidewire crossing through chronic total occlusion: insights from the CT-RECTOR multicenter registry (Computed Tomography Registry of Chronic Total Occlusion Revascularization). *JACC Cardiovasc Interv.* 2015;8:257-67.

42. Tan Y, Zhou J, Zhang W, Zhou Y, Du L, Tian F, Guo J, Chen L, Cao F, Chen Y. Comparison of CT-RECTOR and J-CTO scores to predict chronic total occlusion difficulty for percutaneous coronary intervention. *Int J Cardiol.* 2017;235:169-75.

43. Goleski PJ, Nakamura K, Liebeskind E, Salisbury AC, Grantham JA, McCabe JM, Lombardi WL. Revascularization of coronary chronic total occlusions with subintimal tracking and reentry followed by deferred stenting: Experience from a high-volume referral center. *Catheter Cardiovasc Interv.* 2019;93:191-8.

44. Hirai T, Grantham JA, Sapontis J, Cohen DJ, Marso SP, Lombardi W, Karpaliotis D, Moses J, Nicholson WJ, Pershad A, Wyman RM, Spaedy A, Cook S, Doshi P, Federici R,

Nugent K, Gosch KL, Spertus JA, Salisbury AC; OPEN CTO Study Group. Impact of subintimal plaque modification procedures on health status after unsuccessful chronic total occlusion angioplasty. *Catheter Cardiovasc Interv.* 2018;91:1035-42.

45. Karacsonyi J, Karatasakis A, Karpaliotis D, Alaswad K, Yeh RW, Jaffer FA, Wyman MR, Lombardi WL, Grantham JA, Kandzari DE, Lembo N, Moses JW, Kirtane AJ, Parikh MA, Green P, Finn M, Garcia S, Doing A, Patel M, Bahadorani J, Martinez Parachini JR, Resendes E, Rangan BV, Ungi I, Thompson CA, Banerjee S, Brilakis ES. Effect of Previous Failure on Subsequent Procedural Outcomes of Chronic Total Occlusion Percutaneous Coronary Intervention (from a Contemporary Multicenter Registry). *Am J Cardiol.* 2016;117:1267-71.

46. Sianos G, Konstantinidis NV, Di Mario C, Karvounis H. Theory and practical based approach to chronic total occlusions. *BMC Cardiovasc Disord.* 2016;16:33.

47. Ghione M, Agudo P, Kilickesmez K, Estevez-Loureiro R, Zivelonghi C, Lindsay A, Foin N, Secco GG, Di Mario C. Tools and techniques - clinical: catheter compatibility in CTO recanalisation. *EuroIntervention.* 2013;9:290-1.

48. Bakker EJ, Maeremans J, Zivelonghi C, Faurie B, Avran A, Walsh S, Spratt JC, Knaapen P, Hanratty CG, Bressollette E, Kayaert P, Bagnall AJ, Egred M, Smith D, McEntegart MB, Smith WHT, Kelly P, Irving J, Smith EJ, Strange JW, Dens J, Agostoni P. Fully Transradial Versus Transfemoral Approach for Percutaneous Intervention of Coronary Chronic Total Occlusions Applying the Hybrid Algorithm: Insights From RECHARGE Registry. *Circ Cardiovasc Interv.* 2017 Sep;10(9).

49. Reifart N, Sotoudeh N. The parallel sheath technique in severe iliac tortuosity: a simple and novel technique to improve catheter manoeuvrability. *EuroIntervention.* 2014;10:231-5.

50. Maeremans J, Walsh S, Knaapen P, Spratt JC, Avran A, Hanratty CG, Faurie B, Agostoni P, Bressollette E, Kayaert P, Bagnall AJ, Egred M, Smith D, Chase A, McEntegart MB, Smith WH, Harcombe A, Kelly P, Irving J, Smith EJ, Strange JW, Dens J. The Hybrid Algorithm for Treating Chronic Total Occlusions in Europe: The RECHARGE Registry. *J Am Coll Cardiol.* 2016;68:1958-70.

51. Galassi AR, Tomasello SD, Reifart N, Werner GS, Sianos G, Bonnier H, Sievert H, Ehladad S, Bufe A, Shofer J, Gershlick A, Hildick-Smith D, Escaned J, Erglis A, Sheiban I, Thuesen L, Serra A, Christiansen E, Buettner A, Costanzo L, Barrano G, Di Mario C. In-hospital outcomes of percutaneous coronary intervention in patients with chronic total occlusion: insights from the ERCTO (European Registry of Chronic Total Occlusion) registry. *EuroIntervention.* 2011;7:472-9.

52. Song L, Maehara A, Finn MT, Kalra S, Moses JW, Parikh MA, Kirtane AJ, Collins MB, Nazif TM, Fall KN, Hatem R, Liao M, Kim T, Green P, Ali ZA, Batres C, Leon MB, Mintz GS, Karpaliotis D. Intravascular Ultrasound Analysis of Intraplaque Versus Subintimal Tracking in Percutaneous Intervention for Coronary Chronic Total Occlusions and Association With Procedural Outcomes. *JACC Cardiovasc Interv.* 2017;10:1011-21.

53. Azzalini L, Dautov R, Brilakis ES, Ojeda S, Benincasa S, Bellini B, Karatasakis A, Chavarría J, Rangan BV, Pan M, Carlino M, Colombo A, Rinfret S. Impact of crossing strategy on mid-term outcomes following percutaneous revascularisation of coronary chronic total occlusions. *EuroIntervention.* 2017;13:978-85.

54. Wilson WM, Walsh SJ, Bagnall A, Yan AT, Hanratty CG, Egred M, Smith E, Oldroyd KG, McEntegart M, Irving J, Douglas H, Strange J, Spratt JC. One-year outcomes after successful chronic total occlusion percutaneous coronary intervention: The impact of dissection re-entry techniques. *Catheter Cardiovasc Interv.* 2017;90:703-12.

55. Azzalini L, Carlino M, Brilakis ES, Vo M, Rinfret S, Uretsky BF, Karpaliotis D, Colombo A. Subadventitial techniques for chronic total occlusion percutaneous coronary intervention: The concept of “vessel architecture”. *Catheter Cardiovasc Interv.* 2018;91:725-34.
56. Galassi AR, Boukhris M, Tomasello SD, Marzà F, Azzarelli S, Giubilato S, Khamis H. Long-term clinical and angiographic outcomes of the mini-STAR technique as a bailout strategy for percutaneous coronary intervention of chronic total occlusion. *Can J Cardiol.* 2014;30:1400-6.
57. Brilakis ES, Grantham JA, Rinfret S, Wyman RM, Burke MN, Karpaliotis D, Lembo N, Pershad A, Kandzari DE, Buller CE, DeMartini T, Lombardi WL, Thompson CA. A percutaneous treatment algorithm for crossing coronary chronic total occlusions. *JACC Cardiovasc Interv.* 2012;5:367-79.
58. Dautov R, Manh Nguyen C, Altisent O, Gibrat C, Rinfret S. Recanalization of Chronic Total Occlusions in Patients With Previous Coronary Bypass Surgery and Consideration of Retrograde Access via Saphenous Vein Grafts. *Circ Cardiovasc Interv.* 2016;9:e003515.
59. Azzalini L, Brilakis ES. Ipsilateral vs. contralateral vs. no collateral (antegrade only) chronic total occlusion percutaneous coronary interventions: What is the right choice for your practice? *Catheter Cardiovasc Interv.* 2017;89:656-7.
60. McEntegart MB, Badar AA, Ahmad FA, Shaukat A, Macpherson M, Irving J, Strange J, Bagnall AJ, Hanratty CG, Walsh SJ, Werner GS, Spratt JC. The collateral circulation of coronary chronic total occlusions. *EuroIntervention.* 2016;11:e1596-603.
61. Galassi AR, Sianos G, Werner GS, Escaned J, Tomasello SD, Boukhris M, Castaing M, Buttner JH, Bufe A, Kalnins A, Spratt JC, Garbo R, Hildick-Smith D, Elhadad S, Gagnor A,

Lauer B, Bryniarski L, Christiansen EH, Thuesen L, Meyer-Gessner M, Goktekin O, Carlino M, Louvard Y, Lefevre T, Lismanis A, Gelev VL, Serra A, Marza F, Di Mario C, Reifart N; Euro CTO Club. Retrograde Recanalization of Chronic Total Occlusions in Europe: Procedural, In-Hospital, and Long-Term Outcomes From the Multicenter ERCTO Registry. *J Am Coll Cardiol*. 2015;65:2388-400.

62. Galassi AR, Sumitsuji S, Boukhris M, Brilakis ES, Di Mario C, Garbo R, Spratt JC, Christiansen EH, Gagnor A, Avran A, Sianos G, Werner GS. Utility of Intravascular Ultrasound in Percutaneous Revascularization of Chronic Total Occlusions: An Overview. *JACC Cardiovasc Interv*. 2016;9:1979-91.

63. Vo MN, McCabe JM, Lombardi WL, Ducas J, Ravandi A, Brilakis ES. Adoption of the hybrid CTO approach by a single non-CTO operator: procedural and clinical outcomes. *J Invasive Cardiol*. 2015;27:139-44.

64. Tian NL, Gami SK, Ye F, Zhang JJ, Liu ZZ, Lin S, Ge Z, Shan SJ, You W, Chen L, Zhang YJ, Mintz G, Chen SL. Angiographic and clinical comparisons of intravascular ultrasound- versus angiography-guided drug-eluting stent implantation for patients with chronic total occlusion lesions: two-year results from a randomised AIR-CTO study. *EuroIntervention*. 2015;10:1409-17.

65. Kim BK, Shin DH, Hong MK, Park HS, Rha SW, Mintz GS, Kim JS, Kim JS, Lee SJ, Kim HY, Hong BK, Kang WC, Choi JH, Jang Y; CTO-IVUS Study Investigators. Clinical Impact of Intravascular Ultrasound-Guided Chronic Total Occlusion Intervention With Zotarolimus-Eluting Versus Biolimus-Eluting Stent Implantation: Randomized Study. *Circ Cardiovasc Interv*. 2015;8:e002592.



66. Bhatt H, Janzer S, George JC. Utility of adjunctive modalities in Coronary chronic total occlusion intervention. *Indian Heart J.* 2017;69:375-81.
67. Jia H, Hu S, Liu H, Zhu Y, Zhe CY, Li L, Mustafina I, Hou J, Zhang S, Yu B. Chronic total occlusion is associated with a higher incidence of malapposition and uncovered stent struts: OCT findings at 6 months following DES implantation. *Catheter Cardiovasc Interv.* 2017;89:582-91.
68. Colmenarez HJ, Escaned J, Fernández C, Lobo L, Cano S, del Angel JG, Alfonso F, Jimenez P, Bañuelos C, Gonzalo N, García E, Hernández R, Macaya C. Efficacy and safety of drug-eluting stents in chronic total coronary occlusion recanalization: a systematic review and meta-analysis. *J Am Coll Cardiol.* 2010;55:1854-66.
69. Moreno R, García E, Teles R, Rumoroso JR, Cyrne Carvalho H, Goicolea FJ, Moreu J, Mauri J, Sabaté M, Mainar V, Patricio L, Valdés M, Fernández Vázquez F, Sánchez-Recalde A, Galeote G, Jimenez-Valero S, Almeida M, Lopez de Sa E, Calvo L, Plaza I, Lopez-Sendón JL, Martín JL; CIBELES Investigators. Randomized comparison of sirolimus-eluting and everolimus-eluting coronary stents in the treatment of total coronary occlusions: results from the chronic coronary occlusion treated by everolimus-eluting stent randomized trial. *Circ Cardiovasc Interv.* 2013;6:21-8.
70. Park HJ, Kim HY, Lee JM, Choi YS, Park CS, Kim DB, Her SH, Koh YS, Park MW, Kwon BJ, Kim PJ, Chang K, Chung WS, Seung KB. Randomized comparison of the efficacy and safety of zotarolimus-eluting stents vs. sirolimus-eluting stents for percutaneous coronary intervention in chronic total occlusion--Catholic Total Occlusion Study (CATOS) trial. *Circ J.* 2012;76:868-75.

71. Van den Branden BJ, Teeuwen K, Koolen JJ, van der Schaaf RJ, Henriques JP, Tijssen JG, Kelder JC, Vermeersch PH, Rensing BJ, Suttorp MJ. Primary Stenting of Totally Occluded Native Coronary Arteries III (PRISON III): a randomized comparison of sirolimus-eluting stent implantation with zotarolimus-eluting stent implantation for the treatment of total coronary occlusions. *EuroIntervention*. 2013;9:841-53.

72. Kotsia A, Navara R, Michael TT, Sherbet DP, Roesle M, Christopoulos G, Rangan BV, Haagen D, Garcia S, Maniu C, Pershad A, Abdullah SM, Hastings JL, Kumbhani DJ, Luna M, Addo T, Banerjee S, Brilakis ES. The AngiographiC Evaluation of the Everolimus-Eluting Stent in Chronic Total Occlusion (ACE-CTO) Study. *J Invasive Cardiol*. 2015;27:393-400.

73. Kandzari DE, Kini AS, Karpaliotis D, Moses JW, Tummala PE, Grantham JA, Orr C, Lombardi W, Nicholson WJ, Lembo NJ, Popma JJ, Wang J, Larracas C, Rutledge DR. Safety and Effectiveness of Everolimus-Eluting Stents in Chronic Total Coronary Occlusion Revascularization: Results From the EXPERT CTO Multicenter Trial (Evaluation of the XIENCE Coronary Stent, Performance, and Technique in Chronic Total Occlusions). *JACC Cardiovasc Interv*. 2015;8:761-769.

74. Kandzari DE, Mauri L, Koolen JJ, Massaro JM, Doros G, Garcia-Garcia HM, Bennett J, Roguin A, Gharib EG, Cutlip DE, Waksman R; BIOFLOW V Investigators. Ultrathin, bioresorbable polymer sirolimus-eluting stents versus thin, durable polymer everolimus-eluting stents in patients undergoing coronary revascularisation (BIOFLOW V): a randomised trial. *Lancet*. 2017;390:1843-52.

75. Teeuwen K, van der Schaaf RJ, Adriaenssens T, Koolen JJ, Smits PC, Henriques JP, Vermeersch PH, Tjon Joe Gin RM, Schölzel BE, Kelder JC, Tijssen JG, Agostoni P, Suttorp MJ. Randomized Multicenter Trial Investigating Angiographic Outcomes of Hybrid

Sirolimus-Eluting Stents With Biodegradable Polymer Compared With Everolimus-Eluting Stents With Durable Polymer in Chronic Total Occlusions: The PRISON IV Trial. *JACC Cardiovasc Interv.* 2017;10:133-143.

76. Ojeda S, Azzalini L, Chavarría J, Serra A, Hidalgo F, Benincasa S, Gheorghe LL, Diletti R, Romero M, Bellini B, Gutiérrez A, Suárez de Lezo J, Mazuelos F, Segura J, Carlino M, Colombo A, Pan M. One Versus 2-stent Strategy for the Treatment of Bifurcation Lesions in the Context of a Coronary Chronic Total Occlusion. A Multicenter Registry. *Rev Esp Cardiol (Engl Ed).* 2018;71:432-9.

77. Galassi AR, Boukhris M, Tomasello SD, Marzà F, Azzarelli S, Giubilato S, Khamis H. Incidence, treatment, and in-hospital outcome of bifurcation lesions in patients undergoing percutaneous coronary interventions for chronic total occlusions. *Coron Artery Dis.* 2015;26:142-9.

78. Baystrukov VI, Kretov EI, Boukhris M, Osiev AG, Grazhdankin IO, Biryukov AV, Najjar H, Verin VV, Zubarev DD, Naryshkin IA, Bogachev-Prokophiev AV, Mashayekhi K, Galassi AR, Prokhorikhin AA. A randomized trial of bifurcation stenting technique in chronic total occlusions percutaneous coronary intervention. *Coron Artery Dis.* 2018;29:30-8.

79. Azzalini L, Dautov R, Ojeda S, Benincasa S, Bellini B, Giannini F, Chavarría J, Pan M, Carlino M, Colombo A, Rinfret S. Procedural and Long-Term Outcomes of Percutaneous Coronary Intervention for In-Stent Chronic Total Occlusion. *JACC Cardiovasc Interv.* 2017;10:892-902.

80. Christopoulos G, Karpaliotis D, Alaswad K, Lombardi WL, Grantham JA, Rangan BV, Kotsia AP, Lembo N, Kandzari DE, Lee J, Kalynych A, Carlson H, Garcia S, Banerjee S, Thompson CA, Brilakis ES. The efficacy of “hybrid” percutaneous coronary intervention in

chronic total occlusions caused by in-stent restenosis: insights from a US multicenter registry. *Catheter Cardiovasc Interv.* 2014;84:646-51.

81. Wilson WM, Walsh S, Hanratty C, Strange J, Hill J, Sapontis J, Spratt JC. A novel approach to the management of occlusive in-stent restenosis (ISR). *EuroIntervention.* 2014;9:1285-93.

82. Capretti G, Mitomo S, Giglio M, Carlino M, Colombo A, Azzalini L. Subintimal Crush of an Occluded Stent to Recanalize a Chronic Total Occlusion Due to In-Stent Restenosis: Insights From a Multimodality Imaging Approach. *JACC Cardiovasc Interv.* 2017;10:e81-e83.

83. Azzalini L, Karatasakis A, Spratt JC, Tajti P, Riley RF, Ybarra LF, Schumacher SP, Benincasa S, Bellini B, Candilio L, Mitomo S, Henriksen P, Hidalgo F, Timmers L, Kraaijeveld AP, Agostoni P, Roy J, Ramsay DR, Weaver JC, Knaapen P, Nap A, Starcevic B, Ojeda S, Pan M, Alaswad K, Lombardi WL, Carlino M, Brilakis ES, Colombo A, Rinfret S, Mashayekhi K. Subadventitial stenting around occluded stents: a bailout technique to recanalize in-stent chronic total occlusions. *Catheter Cardiovasc Interv.* 2018;92:466-76.

84. Galassi AR, Boukhris M, Toma A, Elhadj Z, Laroussi L, Gaemperli O, Behnes M, Akin I, Lüscher TF, Neumann FJ, Mashayekhi K. Percutaneous Coronary Intervention of Chronic Total Occlusions in Patients With Low Left Ventricular Ejection Fraction. *JACC Cardiovasc Interv.* 2017;10:2158-70.

85. O'Neill WW, Kleiman NS, Moses J, Henriques JP, Dixon S, Massaro J, Palacios I, Maini B, Mulukutla S, Dzavík V, Popma J, Douglas PS, Ohman M. A prospective, randomized clinical trial of hemodynamic support with Impella 2.5 versus intra-aortic balloon pump in

patients undergoing high-risk percutaneous coronary intervention: the PROTECT II study. *Circulation*. 2012;126:1717-27.

86. Tomasello SD, Boukhris M, Ganyukov V, Galassi AR, Shukevich D, Haes B, Kochergin N, Tarasov R, Popov V, Barbarash L. Outcome of extracorporeal membrane oxygenation support for complex high-risk elective percutaneous coronary interventions: A single-center experience. *Heart Lung*. 2015;44:309-13.

87. Lo N, Michael TT, Moin D, Patel VG, Alomar M, Papayannis A, Cipher D, Abdullah SM, Banerjee S, Brilakis ES. Periprocedural myocardial injury in chronic total occlusion percutaneous interventions: a systematic cardiac biomarker evaluation study. *JACC Cardiovasc Interv*. 2014;7:47-54.

88. Boukhris M, Tomasello SD, Marzà F, Azzarelli S, Galassi AR. Iatrogenic aortic dissection complicating percutaneous coronary intervention for chronic total occlusion. *Can J Cardiol*. 2015;31:320-7.

89. Patel VG, Brayton KM, Tamayo A, Mogabgab O, Michael TT, Lo N, Alomar M, Shorrock D, Cipher D, Abdullah S, Banerjee S, Brilakis ES. Angiographic success and procedural complications in patients undergoing percutaneous coronary chronic total occlusion interventions: a weighted meta-analysis of 18,061 patients from 65 studies. *JACC Cardiovasc Interv*. 2013;6:128-36.

90. Rathore S, Matsuo H, Terashima M, Kinoshita Y, Kimura M, Tsuchikane E, Nasu K, Ehara M, Asakura Y, Katoh O, Suzuki T. Procedural and in-hospital outcomes after percutaneous coronary intervention for chronic total occlusions of coronary arteries 2002 to 2008: impact of novel guidewire techniques. *JACC Cardiovasc Interv*. 2009;2:489-97.

91. Danek BA, Karatasakis A, Karpaliotis D, Alaswad K, Yeh RW, Jaffer FA, Patel MP, Mahmud E, Lombardi WL, Wyman MR, Grantham JA, Doing A, Kandzari DE, Lembo NJ, Garcia S, Toma C, Moses JW, Kirtane AJ, Parikh MA, Ali ZA, Karacsonyi J, Rangan BV, Thompson CA, Banerjee S, Brilakis ES. Development and Validation of a Scoring System for Predicting Periprocedural Complications During Percutaneous Coronary Interventions of Chronic Total Occlusions: The Prospective Global Registry for the Study of Chronic Total Occlusion Intervention (PROGRESS CTO) Complications Score. *J Am Heart Assoc.* 2016 Oct 11;5(10).

92. Danek BA, Karatasakis A, Tajti P, Sandoval Y, Karpaliotis D, Alaswad K, Jaffer F, Yeh RW, Kandzari DE, Lembo NJ, Patel MP, Mahmud E, Choi JW, Doing AH, Lombardi WL, Wyman RM, Toma C, Garcia S, Moses JW, Kirtane AJ, Hatem R, Ali ZA, Parikh M, Karacsonyi J, Rangan BV, Khalili H, Burke MN, Banerjee S, Brilakis ES. Incidence, Treatment, and Outcomes of Coronary Perforation During Chronic Total Occlusion Percutaneous Coronary Intervention. *Am J Cardiol.* 2017;120:1285-92.

93. Boukhris M, Tomasello SD, Azzarelli S, Elhadj ZI, Marzà F, Galassi AR. Coronary perforation with tamponade successfully managed by retrograde and antegrade coil embolization. *J Saudi Heart Assoc.* 2015;27:216-21.

94. Wei KC, Yang KC, Mar GY, Chen LW, Wu CS, Lai CC, Wang WH, Lai PC. STROBE-- Radiation Ulcer: An Overlooked Complication of Fluoroscopic Intervention: A Cross-Sectional Study. *Medicine (Baltimore).* 2015;94:e2178.

95. Liu YH, Liu Y, Tan N, Chen JY, Zhou YL, Luo JF, Yu DQ, Li LW, Li HL, Ye P, Ran P. Contrast-induced nephropathy following chronic total occlusion percutaneous coronary intervention in patients with chronic kidney disease. *Eur Radiol.* 2015;25:2274-81.

96. Suzuki S, Furui S, Kohtake H, Yokoyama N, Kozuma K, Yamamoto Y, Isshiki T. Radiation exposure to patient's skin during percutaneous coronary intervention for various lesions, including chronic total occlusion. *Circ J*. 2006;70:44-8.
97. Pavlidis AN, Jones DA, Sirker A, Mathur A, Smith EJ. Prevention of contrast-induced acute kidney injury after percutaneous coronary intervention for chronic total coronary occlusions. *Am J Cardiol*. 2015;115:844-51.
98. Valgimigli M, Bueno H, Byrne RA, Collet JP, Costa F, Jeppsson A, Jüni P, Kastrati A, Kolh P, Mauri L, Montalescot G, Neumann FJ, Petricevic M, Roffi M, Steg PG, Windecker S, Zamorano JL, Levine GN; ESC Scientific Document Group; ESC Committee for Practice Guidelines (CPG); ESC National Cardiac Societies. 2017 ESC focused update on dual antiplatelet therapy in coronary artery disease developed in collaboration with EACTS: The Task Force for dual antiplatelet therapy in coronary artery disease of the European Society of Cardiology (ESC) and of the European Association for Cardio-Thoracic Surgery (EACTS). *Eur Heart J*. 2018;39:213-60.
99. Giustino G, Chieffo A, Palmerini T, Valgimigli M, Feres F, Abizaid A, Costa RA, Hong MK, Kim BK, Jang Y, Kim HS, Park KW, Gilard M, Morice MC, Sawaya F, Sardella G, Genereux P, Redfors B, Leon MB, Bhatt DL, Stone GW, Colombo A. Efficacy and Safety of Dual Antiplatelet Therapy After Complex PCI. *J Am Coll Cardiol*. 2016;68:1851-64.
100. Lee SH, Yang JH, Choi SH, Park TK, Jang WJ, Song YB, Hahn JY, Choi JH, Gwon HC. Duration of dual antiplatelet therapy in patients treated with percutaneous coronary intervention for coronary chronic total occlusion. *PLoS One*. 2017;12:e0176737.