

Percutaneous Melody valve implantation for tricuspid valve regurgitation with very large annulus: the diabolo-shaped bridge for valve-in-stent technique



Sophie Malekzadeh-Milani^{1,2}, MD; Mehul Patel^{1,2}, MD; Younes Boudjemline^{1,2,3*}, MD, PhD

1. Centre de Référence Malformations Cardiaques Congénitales Complexes - M3C, Necker Hospital for Sick Children, Assistance Publique des Hôpitaux de Paris, Pediatric Cardiology, Paris, France; 2. Centre de Référence Malformations Cardiaques Congénitales Complexes - M3C, George Pompidou European Hospital, Assistance Publique des Hôpitaux de Paris, Unit for Adults with Congenital Heart Defects, Paris, France; 3. Université Paris Descartes, Sorbonne Paris Cité, Paris, France

This paper also includes supplementary data published online at: http://www.pcronline.com/eurointervention/97th_issue/301

Tricuspid valve insertion of the Melody® (Medtronic, Minneapolis, MN, USA) valve has been described in patients with a bioprosthesis. However, size limitations restrict its use. We report implantation of a Melody valve in a patient with severe regurgitation of a 33 mm Carpentier-Edwards PERIMOUNT valve (Edwards Lifesciences, Irvine, CA, USA). The procedure was conducted from the right femoral vein. Balloon calibration showed an inner diameter of 28 mm. The platform for the Melody valve was created using a short ev3 Mega™ LD (ev3 Endovascular Inc., Plymouth, MN, USA) fitted over a CP covered stent (8Z39; NuMED, Inc., Hopkinton, NY, USA), the two stents being crimped on a 28 mm NuCLEUS™ balloon (NuMED). The assembly was delivered in the bioprosthesis (**Figure 1**). This allowed full expansion and flaring of the extremities of the CP stent and only partial opening of the centre of the CP stent, creating a diabolo-shaped

platform. A Melody valve mounted on a 22 mm delivery catheter was implanted and post-dilated with a 24 mm balloon (**Moving image 1**). Five months post implantation, there was no valvular or paravalvular regurgitation with a mean gradient of 3 mmHg.

Conflict of interest statement

Y. Boudjemline acts as a proctor for Medtronic Inc. The other authors have no conflicts of interest to declare.

Supplementary data

Moving image 1. Creation of a diabolo-shaped platform and percutaneous implantation of a Melody valve. A) Right ventricle angiogram: severe tricuspid regurgitation. B) Calibration with PTS balloon. C) & D) Pre-stenting: creation of a diabolo-shaped platform. E) Melody valve is advanced. F) Post-dilatation.

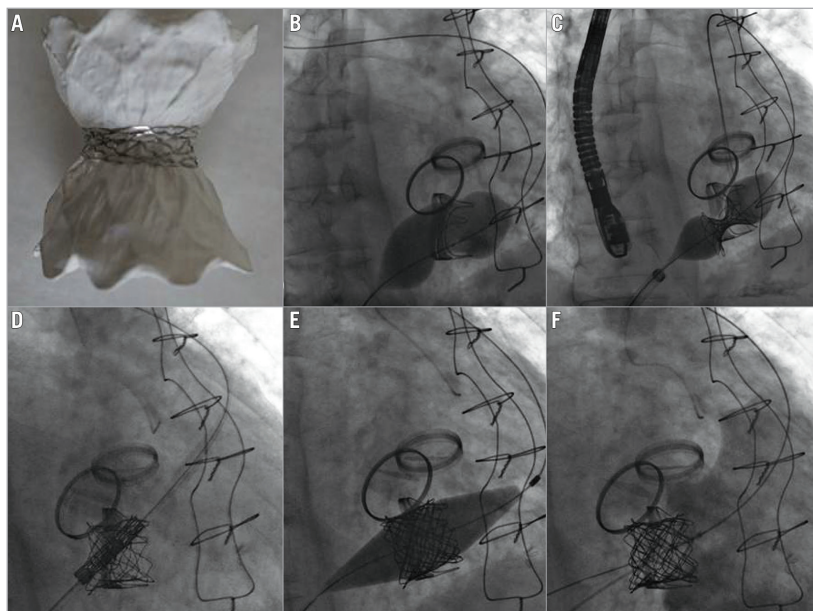


Figure 1. Bench testing of the valve-in-stent technique. The properties of two different stents were used with one fitted on the second one to create a platform: 1) a bare metal stent with limited expansion to create a restrictive region; 2) a covered stent without limited expansion to allow anchoring to the large surgically inserted bioprosthesis. A) Lateral view of the two stents after inflation of the balloon. B) Sizing with PTS balloon. C) Inflation of the assembly on the balloon. D) The Melody valve is advanced within the bioprosthesis. E) Post-dilatation with a balloon. F) Post-implantation angiogram: no regurgitation.

*Corresponding author: Cardiologie Pédiatrique, Hôpital Necker Enfants Malades, 149 rue de Sèvres, 75015 Paris Cedex, France. E-mail: younes.boudjemline@nck.aphp.fr

