

Percutaneous coronary intervention for bifurcation coronary lesions using optimised angiographic guidance: the 18th consensus document from the European Bifurcation Club

Francesco Burzotta^{1,2*}, MD, PhD; Yves Louvard³, MD; Jens Flensted Lassen⁴, MD, PhD; Thierry Lefèvre³, MD; Gérard Finet⁵, MD; Carlos Collet⁶, MD, PhD; Jacek Legutko⁷, MD, PhD; Maciej Lesiak⁸, MD, PhD; Yutaka Hikichi⁹, MD, PhD; Remo Albiero¹⁰, MD; Manuel Pan¹¹, MD, PhD; Yiannis S. Chatzizisis¹², MD, PhD; David Hildick-Smith¹³, MD; Mirosław Ferenc¹⁴, MD, PhD; Thomas W. Johnson¹⁵, MD, PhD; Alaide Chieffo^{16,17}, MD, PhD; Olivier Darremont¹⁸, MD; Adrian Banning¹⁹, MD, PhD; Patrick W. Serruys²⁰, MD, PhD; Goran Stankovic²¹, MD, PhD

*Corresponding author: Department of Cardiovascular Sciences, Fondazione Policlinico Universitario A. Gemelli IRCCS, Università Cattolica del Sacro Cuore, Largo A. Gemelli 1, 00168, Rome, Italy. E-mail: francesco.burzotta@unicatt.it

This paper also includes supplementary data published online at: <https://eurointervention.pconline.com/doi/10.4244/EIJ-D-24-00160>

ABSTRACT

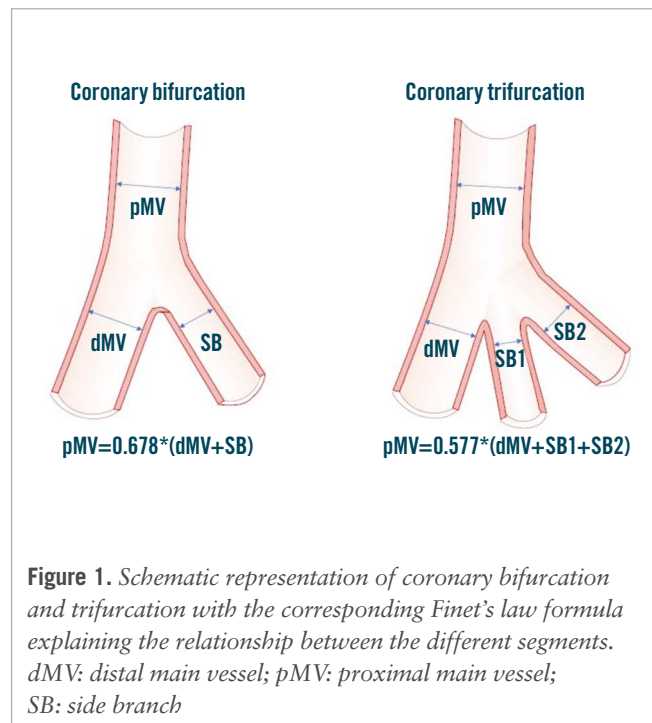
The 2023 European Bifurcation Club (EBC) meeting took place in Warsaw in October, and the latest evidence for the use of intravascular ultrasound (IVUS) and optical coherence tomography (OCT) to optimise percutaneous coronary interventions (PCI) on coronary bifurcation lesions (CBLs) was a major focus. The topic generated deep discussions and general appraisal on the potential benefits of IVUS and OCT in PCI procedures. Nevertheless, despite an increasing recognition of IVUS and OCT capabilities and their recognised central role for guidance in complex CBL and left main PCI, it is expected that angiography will continue to be the primary guidance modality for CBL PCI, principally due to educational and economic barriers. Mindful of the restricted access/adoption of intracoronary imaging for CBL PCI, the EBC board decided to review and describe a series of tips and tricks which can help to optimise angiography-guided PCI for CBLs. The identified key points for achieving an optimal angiography-guided PCI include a thorough analysis of pre-PCI images (computed tomography angiography, multiple angiographic views, quantitative coronary angiography vessel estimation), a systematic application of the technical steps suggested for a given selected technique, an intraprocedural or post-PCI use of stent enhancement and a low threshold for bailout use of intravascular imaging.

KEYWORDS: angiography; bifurcation lesions; computed tomography; DES; PCI; stent enhancement

Since 2004, the European Bifurcation Club (EBC) has been consistently advocating for the improvement and standardisation of percutaneous coronary interventions (PCI) on coronary bifurcation lesions (CBLs) and the unprotected left main (LM) coronary artery. The annual 2-day EBC meeting facilitates multidisciplinary discussions, leading to the creation of a series of consensus papers covering general updates on CBL evaluation and treatment¹⁻³, as well as specific technical problems⁴⁻⁶ encountered in bifurcation lesion stenting. The use of intracoronary imaging (ICI) modalities, such as intravascular ultrasound (IVUS) and optical coherence tomography (OCT), to optimise PCI on CBL and the LM artery has been a major and frequently debated issue. Thus, dedicated documents^{7,8} were generated aiming at promoting the use of IVUS and OCT for optimising technical results in these settings. However, the routine use of ICI requires appropriate training, is cost intensive, is limited by the need for specialised education, and may not be applicable in all clinical and anatomical scenarios. Although ICI is the best approach for achieving an optimal result in bifurcation stenting, the ultimate success of a bifurcation PCI procedure still depends on the final configuration achieved in the stented area. This, in turn, depends on the success of the specific distinct steps required for each bifurcation stenting technique. Finally, not all the possible technical imperfections that could potentially occur during bifurcation PCI are reasonably prevented, recognised or corrected by ICI alone. As a result, although ICI guidance should be regarded as a gold standard, angiography-guided PCI maintains a central role in bifurcation PCI practice. In the present paper, we report a series of tips and tricks for angiography-based optimisation of bifurcation PCI which have been proposed, discussed or shared during the various EBC meetings.

Key rules for coronary bifurcations

The universal law of conservation of mass (or flow) states that the sum of the total outflow must be equal to the inflow⁹. As a result, arterial geometry is intricately tied to its function. An experimental clinical study¹⁰ demonstrated the fractal nature based on this geometry and a linear relationship between the diameters of the mother vessel (the proximal main vessel [pMV]) and the diameters of the daughter vessels (the distal main vessel [dMV] and the side branch [SB]). This is expressed by the following formula: $pMV=0.678*(dMV+SB)^{10-12}$ (Figure 1). Likewise, for an arterial trifurcation, an appropriate linear relationship has been proposed: $pMV=0.58*(dMV+SB_1+SB_2)^{13}$ (Figure 1). These validated and simple laws find application



in the context of PCI to select balloons and stent sizes, particularly when the bifurcation/trifurcation has not been evaluated by ICI. It is noteworthy that a series of conditions (occluded branches, diffusely diseased bifurcation/trifurcation segments, etc.) may generate uncertainties about the size of a bifurcation/trifurcation segment during angiography-guided PCI. To facilitate the estimation of segment size under such circumstances, an online calculator has been developed (<https://bifurc.eu/ebc-diameter-calculator/>) allowing for the calculation of the theoretical nominal segment diameter after identifying the size of the other bifurcation/trifurcation segments. It should be emphasised that diseased coronary vessels have variable degrees of positive or negative remodelling, so estimations based on such formulae should be regarded as merely indicative.

How to approach a bifurcation PCI in the absence of intracoronary imaging

Attempting to simplify and standardise the procedure as much as possible and limiting the number of implanted stents by using a stepwise provisional strategy remains the recommended strategy for the majority of true LM and non-LM CBLs¹. This enduring recommendation of the EBC has recently been

Abbreviations

CBL	coronary bifurcation lesion	EBC	European Bifurcation Club	PCI	percutaneous coronary intervention
CT	computed tomography	FFR	fractional flow reserve	pMV	proximal main vessel
CTA	computed tomography angiography	ICI	intracoronary imaging	POT	proximal optimisation technique
DK	double-kissing	IVUS	intravascular ultrasound	QCA	quantitative coronary angiography
dMV	distal main vessel	LM	left main	SB	side branch
EAPCI	European Association of Percutaneous Cardiovascular Interventions	MV	main vessel		
		OCT	optical coherence tomography		

further supported by the results of the EBC TWO¹⁴ and EBC MAIN¹⁵ randomised trials. These studies have proven that a second stent was needed in only 20% of the cases randomised to a stepwise provisional approach and that fewer revascularisations occurred if the amount of metal was kept to a minimum^{14,15}. When SB stent placement is required after main vessel stenting, use of T-stenting, T and small protrusion (TAP) or culottes are the possible technical options³. A planned 2-stent strategy may be considered for bifurcation lesions when the atherosclerotic involvement of a relevant SB is extensive¹⁶ and/or the anatomical complexity is high, as estimated by the angiographic criteria outlined in the Bifurcation Academic Research Consortium (Bif-ARC) consensus document¹⁷. In bifurcations likely requiring two stents, the double-kissing (DK) crush technique has been promoted as a valuable strategy for systematic 2-stent implantation when the target vessel is the LM and PCI is performed by high-volume operators¹⁸. The DK crush technique, however, is complex and can only end safely with the two stents implanted and final kissing balloon inflation performed. Of note, it should be emphasised that, in the complex lesions enrolled in the EBC MAIN trial, the provisional technique, which was also performed according to the “inverted” strategy – implanting the first stent from the SB to the pMV, was highly effective¹⁵.

Optimised stent(s) expansion and apposition are the most likely main procedural surrogates for a good clinical outcome¹. Accordingly, with increasing lesion complexity, adequate lesion preparation, particularly in the presence of a high burden of calcium, becomes crucial. The ICI evaluation provides invaluable information for lesion preparation, but this is not always readily available. The use of balloon-based techniques (cutting balloons, scoring balloons, high- and super-high-pressure balloons), atherectomy tools (rotational atherectomy, orbital atherectomy, laser) or intravascular lithotripsy should be considered in accordance with the recent algorithm proposed in the EAPCI Euro4C-PCR group consensus document¹⁹. The selection of an appropriately sized stent, tailored to accommodate the distinct bifurcation segments, is inherently challenging and warrants careful consideration. This is due to instances of notable stent malapposition, particularly in the pMV. Such malapposition is a systematic issue and poses a significant risk factor for subsequent stent deformation and/or abluminal wiring during the next stages of the procedure^{4,5}. To overcome such complications, adequate expansion (from the proximal edge to the bifurcation core) of the pMV stent segment through the proximal optimisation technique (POT) becomes crucial. This specific technical step is recognised as pivotal for all major bifurcation stenting techniques^{1,2}. Before completion of the procedure, high-pressure balloon post-dilatation of all stented segments of the coronary bifurcation is recommended¹. This includes extensive use of non-compliant balloons in both 1- and 2-stent techniques and the systematic performance of high-pressure final kissing balloon inflation in 2-stent techniques¹. According to the Bif-ARC endpoints classification, the goal of any angiography-guided bifurcation PCI is to achieve “procedural success”, defined as the proper placement of the stent(s) in the bifurcation segments and the absence of in-hospital significant cardiac events¹⁷. This definition translates into an optimal expansion of the implanted stents, along with the absence of procedural

angiographic complications (dissections, thrombosis, etc.) potentially leading to adverse clinical events. **Table 1** summarises the essential targets that should be pursued during bifurcation PCI.

The critical information provided by coronary computed tomography angiography

Coronary computed tomography angiography (CTA) has become the preferred non-invasive modality for assessing coronary artery disease in patients presenting with chest pain²⁰. Consequently, the number of patients undergoing invasive angiography with prior CTA evaluation is increasing. In addition to luminal analysis for the assessment of stenosis severity, coronary CTA provides a comprehensive evaluation of atherosclerotic plaque composition^{21,22} that may help in planning a PCI strategy, similarly to intravascular imaging. New advances, through the development of photon-counting computed tomography (CT) will further enhance the capabilities of non-invasive assessment.

Within the specific field of CBLs, the three-dimensional (3D) nature of CT provides pre-PCI identification of the optimal angiographic views, which may help during the procedure, and even facilitate virtual physiological assessment during Murray law-based angiographic assessment of quantitative flow ratio²³. These benefits also concern the performance of the bifurcation PCI procedure. Indeed, CTA permits a careful analysis of the anatomical relationship between the plaque and the SB²⁴, anticipating potential procedural challenges. The presence of non-calcified plaques, characterised by low attenuation, in the pMV or SB has been shown to predict SB occlusion²⁵. Furthermore, the presence of calcium in the main vessel on the contralateral side of the SB anticipates difficulties in achieving symmetric stent expansion, leading to the risk of stent protrusion toward the SB ostium and of carina shift and branch occlusion²⁵. The acquisition of such data before PCI assists preprocedural PCI planning, prompting adequate vessel preparation¹⁹. This becomes particularly critical in cases of complex bifurcations, with severe calcification, where coronary CTA can stratify calcified plaque based on its arc, length, and thickness in both the main vessel and the SB²⁶. Another relevant aspect involves the quantification of the myocardial mass subtended by the main vessel and the SB²⁷. As recently reported in the Bif-ARC document, this offers valuable insights into the clinical significance of the branch¹⁷. In this regard, the computation of blood flow from CTA, using dedicated algorithms (CT-derived fractional flow reserve [FFR_{CT}]), provides information on the extent of flow reduction and the presence of ischaemia in different myocardial territories. This is most relevant in coronary bifurcations or trifurcations, where invasive functional assessment is more complex than in single diseased vessels (need for multiple measures, risk of extensive ischaemia during hyperaemia). Furthermore, FFR_{CT} might allow the quantification of translesional pressure gradients across the bifurcation lesion, which, in addition to the classical physiological assessment at the distal segment of the vessels, enhances patient selection for bifurcation PCI²⁸. Additionally, FFR_{CT} technology has the potential to predict the outcomes of PCI in both the main vessel and in the SB (virtual stenting function). The current FFR_{CT} planner technology supports provisional and

Table 1. Key principles of bifurcation PCI promoted by the European Bifurcation Club.

Essential target	Description
Keep the procedure simple and safe	- Choose a provisional stepwise stenting strategy
Respect the original bifurcation anatomy and physiology and aim to reproduce it	- Reconstruct the bifurcation anatomy with respect to the Finet, Murray and Huo-Kassab laws
Limit the number of stents	- Use a stepwise provisional strategy when the use of two stents is anticipated - Implant the first stent reversely from the SB to main branch when the SB is severely diseased - Use kissing balloons (opens the SB and centres the carina) - Implant a second stent only if needed (as T, TAP or culotte)
Do not stent the SB by default	- Consider the significance of the SB (CT scan, length, and diameter) - Conditions supporting SB stent implantation after provisional stenting of the main vessel: 1. impaired TIMI flow in the SB 2. significant stenosis (>70%) with angina and/or ECG changes 3. extensive dissection (>type B) in the SB
Remember the step down in reference diameter from the proximal main vessel to the distal main vessel below the side branch take-off	- Size the first stent 1:1 to the distal main vessel reference diameter - Choose a stent diameter for which the platform accommodates expansion to the reference diameter of the proximal main vessel - Use of POT with balloon sized 1:1 to the proximal main vessel reference diameter - Be aware of geographical miss during POT (avoid bottle neck configuration of the stent)
Limit metal overlap	- Long segments and multiple layers of stents are associated with an increased risk of stent failure (ST and restenosis) - Presence of multiple layers of stent struts across the side branch ostium makes it more difficult to perform kissing balloon inflations - Reduce the stent overlap in DK crush and DK culotte
Achieve sufficient stent expansion	- Suboptimal stent expansion correlates with stent failure (ST and restenosis) - Stent expansion can accurately be estimated only by intracoronary imaging, but major underexpansion might be recognised by meticulous angiography revision and should be avoided - Optimal lesion preparation before stent implantation aids stent expansion - High-pressure non-compliant balloon post-dilatation of all stented segments of coronary bifurcation is recommended - Overdilate the stents by 5-10%, to compensate for recoil - Aim for: TIMI 3 flow in the main vessel and side branch; Minimal residual stenosis in the stented segments (DS <10%).
Avoid major stent malapposition	- Major malapposition is associated with increased risk of major safety events, including cardiac death, MI and ST - Stent apposition can accurately be estimated only by intracoronary imaging but major malapposition might be recognised by meticulous angiography revision and should be avoided - Stent malapposition is most often present in the proximal main vessel of a coronary bifurcation lesion due to suboptimal POT (undersized balloon used for POT) - The presence of stent malapposition in the proximal main vessel increases the risk of abluminal wiring and stent deformation during baseline and subsequent follow-up procedures - Use a stent-enhanced view when possible - Size the devices with respect to the vascular branching laws - Consider using contrast puffing during balloon inflations when a doubt of significant undersizing exists

CT: computed tomography; DK: double-kissing; DS: diameter stenosis; ECG: electrocardiogram; MI: myocardial infarction; PCI: percutaneous coronary intervention; POT: proximal optimisation technique; SB: side branch; ST: stent thrombosis; TAP: T and small protrusion; TIMI: Thrombolysis in Myocardial Infarction

2-stent strategies, offering a comprehensive morphological and physiological approach to planning^{29,30}. **Supplementary Figure 1** shows an example of advanced processing of CTA for planning PCI.

In conclusion, if CTA has been performed, it is strongly recommended that operators meticulously review the CTA images before CBL and LM PCI.

Updated coronary vessel sizing by angiography

Coronary angiography encounters limitations when applied to CBL due to its inherent two-dimensional (2D) nature. Consequently, pre-PCI angiography requires careful

consideration to identify optimal angulations for visualising critical aspects, such as plaque distribution, vessel relevance, and subsequent post-PCI assessment. It is important to note that there is no single best projection capable of thoroughly evaluating the entire CBL. Certain views may be optimal for assessing lesion length, while others may offer superior insights into the SB ostium. In terms of stenosis severity and plaque distribution, visual assessment in CBLs is limited by its interoperator variability, with a tendency to overestimate SB disease significance³¹. Moreover, quantitative coronary angiography (QCA) analysis using the traditional single-vessel approach overestimates disease severity due to a failure

to account for the natural step down in vessel diameter after the SB take-off. To overcome this limitation, 2D and 3D QCA analysis software dedicated to bifurcation has been developed³², and its use is strongly recommended.

Compared to traditional QCA, ICI demonstrated superior precision and accuracy in quantitative assessments. Comparative analyses between angiography and ICI modalities have consistently revealed that dimensions derived from IVUS and OCT are, on average, larger than those derived from QCA, with OCT providing the highest accuracy³³.

These considerations emphasise the crucial role of ICI in optimising decision-making and interventional precision in the complex setting of CBLs. Despite the inherent limitations of angiographic interpretation, efforts to enhance our assessment should be considered. In a recent prospective randomised trial, an “adjusted” angiographic stent-sizing approach was employed for the first time. This protocol involved adjusting software-measured QCA reference vessel diameters by applying a 5-10% oversizing to create target diameters for stent sizing and post-dilatation³⁴. Notably, bifurcation lesions, including those treated with 2-stent techniques, were included, demonstrating the feasibility of this approach³⁴. **Table 2** shows the estimation of “target” vessel reference diameters successfully adopted in the GUIDE DES trial³⁴. Of note, only intravascular imaging is able to ascertain the true vessel size; it is impossible to recognise healthy references with angiography, especially in the presence of diffuse coronary artery disease.

Technical basics for stent selection and deployment

THE DYNAMIC NATURE OF THE EXPANSION OF BALLOONS AND STENTS

An understanding of balloon and stent device characteristics can assist in the technical success of CBL PCI.

Coronary balloon construction differs according to the manufacturer, and their size is not fixed³⁵⁻³⁷. This is due to their intrinsic elasticity causing a device-specific compliance (calculated as mm/atm). Two types of balloons are available in daily practice: non-compliant (small compliance) and semicompliant (intermediate compliance). The manufacturers provide pressure/diameter curves and define a nominal diameter (the “size” of the balloon on the packaging) achievable with a specific pressure. The nominal diameter of semicompliant balloons is determined at low pressures, typically ranging

from 6 to 12 atmospheres (atm). This provides a higher capacity for diameter increase. On the contrary, the nominal diameter is achieved at a higher pressure with non-compliant balloons (14-16 atm). Bench test studies have shown that the pressure-diameter curves are specific to the balloon type and size³⁷⁻³⁸. Importantly, the number of inflations affects the balloon behaviour. In particular, measured diameters are inferior to those declared by the manufacturer during the first inflation, similar at the second inflation, and superior for the third. For non-compliant balloons, the nominal diameter is determined with maximal pressure at the third inflation only (see **Supplementary Figure 2** for examples of the behaviour of semicompliant and non-compliant balloons).

Stents offer minimal resistance to balloon inflation, indicating that, in the absence of external resistance, a stent's expansion relies on the compliance of the stent's balloon. Notably, vessel calcification is a significant factor contributing to stent underdeployment³⁸. Manufacturers typically provide a range of potential expansion diameters based on the applied pressures of a stent's balloon. These charts often include a range where the lower pressure is 7-8 atm.

It is essential to recognise that inflation pressure and inflation time significantly influence stent expansion. Firstly, if a stent's balloon is inflated at pressures lower than 6-7 atm, stent expansion initiates, but it takes a longer time to complete³⁹. Additionally, a series of observations documented that the stent diameter achieved at a fixed inflation pressure increases with inflation time⁴⁰⁻⁴³. Manufacturers' charts typically indicate the pressure required to reach the stent diameter achievable with sustained (>20-30 sec) inflation at a specific pressure. Importantly, inflation times and numbers are cumulative, meaning that the same expansion can be achieved with either a prolonged inflation or multiple shorter inflations³⁷. This property can be used to adapt the expansion modality (prolonged inflation or multiple short inflations) to the patients' characteristics.

Overall, these characteristics play a crucial role in both the initial deployment of the stent and subsequent expansion through post-dilatation of the proximal or distal segments.

STENT ADAPTATION TO THE BIFURCATION ANATOMY BASED ON A STENT'S EXPANSION POTENTIAL

In the vast majority of bifurcation stenting procedures (from stepwise provisional to DK crush), a stent is implanted across the take-off of a branch vessel, implying the need to “adjust” the stent expansion to two vessel segments with different sizes. In other words, when such “crossover stenting” is performed, the stent size should be selected according to the dMV diameter, with consideration of the overexpansion required to achieve the pMV diameter using the POT with an appropriately sized balloon. Recently, dedicated bench tests demonstrated that the ideal POT is performed when inflating an appropriate balloon: diameter sized according to pMV reference diameter and length equal to the length of the stented pMV⁴⁴. In clinical practice, this is rarely possible, as POT balloons are often shorter than the pMV stent segment, leading to multiple inflations in order to expand both the bifurcation area and the pMV up to the proximal stent edge. When multiple inflations with different balloon positions are performed, the balloon expansion sequence has been

Table 2. Target diameters of the reference segments obtained by adjusting QCA values in the GUIDE DES trial.

QCA-estimated reference vessel diameter	Target vessel estimation
≤3.5 mm	QCA-estimated reference vessel diameter+10%
>3.5 mm and <4.0 mm	QCA-estimated reference vessel diameter+6-9%
≥4.0 mm	QCA-estimated reference vessel diameter+5%

DES: drug-eluting stent; QCA: quantitative coronary angiography

shown to influence stent geometry. In particular, bench tests documented that distal to proximal POT is associated with pMV stent elongation, a phenomenon which is preventable by performing proximal to distal POT⁴⁴.

In addition to POT, it is crucial to give maximum attention to ensuring proper stent expansion in the dMV. Consequently, a distal post-dilatation, utilising an appropriately sized non-compliant balloon, is frequently necessary. This step is usually called “distal optimisation technique” (DOT). Because of the technical characteristics discussed earlier, the stent compliance chart should be carefully analysed, in order to facilitate the adaptation of the stent to any of the two segments. This can be accomplished by examining the technical characteristics of various stent platforms, taking into account not only the maximum expansion (necessary for achieving apposition in the proximal segment) but also the minimum expansion required to safely fit within the smaller distal segment. It is essential to choose a stent platform that is suitable for both the pMV and the dMV in order to achieve optimal stent deployment. **Table 3** reports the “on-label” minimal expansion (with the corresponding atmospheres) and the “on-label” maximal expansions for some common stent platforms, demonstrating the wide range of options and supporting the process of stent selection and post-dilatation in the setting of bifurcations. Indeed, **Table 3** shows how a particular bifurcation anatomy might be treated with different stent platforms, even among the options offered by the same manufacturer. Of note, a bench test study by Hikichi et al⁴⁴ has demonstrated that choosing a bigger stent platform, with a nominal size close to the reference diameter of the pMV (instead of the segment), is associated with a more favourable stent configuration (**Figure 2**), resulting in a reduced incidence of incomplete stent apposition and better vessel coverage. In this regard, recognising the expansion characteristics has a greater relevance in specific conditions, such as “inverted”

provisional techniques for the treatment of Medina type 0,0,1 large bifurcation lesions. For instance, these considerations have led to the development of the extreme concept of “stent underdeployment”, whereby the larger stent platform (sized according to the pMV or SB diameter) is preferred. Consequently, the stent is first implanted at below nominal pressure, avoiding overexpansion of the dMV. Subsequently, the pMV stent segment is expanded with a 1:1-sized balloon. This technique has been recently proposed to treat patients presenting a major size mismatch between the LM (large diameter) and proximal left anterior descending artery (LAD), with a novel extra-large drug-eluting stent (DES) platform⁴⁵.

Enhanced assessment of stent conformation during bifurcation PCI

The final goal of bifurcation PCI is to restore the native anatomy/physiology of the bifurcation and to minimise metal coverage (stented areas)¹⁷. From the first stent implantation to the procedure’s end, the stent(s) implanted into a CBL is required to conform to complex geometries through multiple steps of balloon modification. The sequence, the number and the quality of the different bifurcation PCI procedural steps are well known to influence the final conformation of the stent(s)⁴⁶. The identification of the proper reference vessel size is pivotal (to drive adequate balloon selection) and undoubtedly more challenging in the absence of ICI. Stent post-dilatation (often performed through multiple non-compliant or semicompliant balloons) is of paramount importance to obtain adequate expansion and apposition. Therefore, appropriate balloon sizing is crucial, but there is a tendency to undersize in procedures not guided by ICI. For instance, significant undersizing of the POT balloon is a common cause of major malapposition in the pMV, leading to potential complications both during the procedure (abluminal rewiring, stent deformation)^{4,5} and in the postprocedural course⁴⁷.

Table 3. Compliance charts for common DES platforms.

DES platform	Nominal size range for each platform	Minimal expansion diameter (according to manufacturers’ chart)	Maximal overexpansion diameter with appropriately sized postdilating balloon (on-label use)
XIENCE Skypoint ¹	2.0-3.0 mm	2.05 mm (for 2.0 mm stent @ 8 atm)	3.75 mm
XIENCE Skypoint ¹	3.5-5.0 mm	3.36 mm (for 3.5 mm stent @ 8 atm)	5.75 mm
Onyx Frontier ²	2.0-2.5 mm	1.89 mm (for 2.0 mm stent @ 7 atm)	3.00 mm
Onyx Frontier ²	2.75-3.0 mm	2.50 mm (for 2.75 mm stent @ 7 atm)	4.00 mm
Onyx Frontier ²	3.5-4.0 mm	3.20 mm (for 3.5 mm stent @ 7 atm)	5.00 mm
Onyx Frontier ²	4.5-5.0 mm	4.10 mm (for 4.5 mm stent @ 7 atm)	6.00 mm
SYNERGY XD ³	2.25-2.75 mm	2.05 mm (for 2.0 mm stent @ 8 atm)	3.50 mm
SYNERGY XD ³	3.0-3.5 mm	3.05 mm (for 3.0 mm stent @ 8 atm)	4.25 mm
SYNERGY XD ³	4.0 mm	3.88 mm (for 4.0 mm stent @ 8 atm)	5.75 mm
SYNERGY MEGATRON ³	3.5-5.0 mm	3.18 mm (for 3.5 mm stent @ 8 atm)	6.00 mm
Ultimaster Nagomi ⁴	2.0-2.5 mm	1.84 mm (for 2.0 mm stent @ 7 atm)	3.50 mm
Ultimaster Nagomi ⁴	2.75-3.0 mm	2.56 mm (for 2.75 mm stent @ 7 atm)	4.50 mm
Ultimaster Nagomi ⁴	3.5-4.5 mm	3.26 mm (for 3.5 mm stent @ 7 atm)	6.25 mm
Orsiro Mission ⁵	2.25-3.0 mm	2.31 mm (for 2.25 mm stent @ 8 atm)	3.5 mm
Orsiro Mission ⁵	3.5-4.0 mm	3.56 mm (for 3.5 mm stent @ 10 atm)	4.5 mm

¹Abbott; ²Medtronic; ³Boston Scientific; ⁴Terumo; ⁵BIOTRONIK. DES: drug-eluting stent

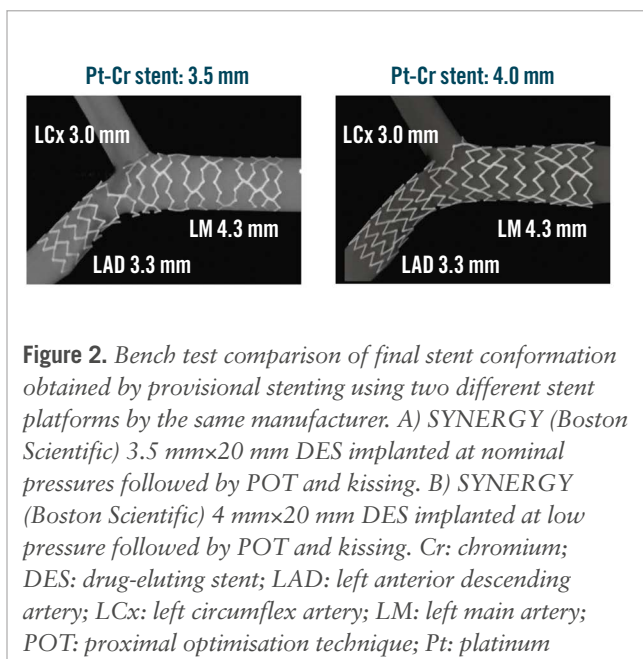


Figure 2. Bench test comparison of final stent conformation obtained by provisional stenting using two different stent platforms by the same manufacturer. A) SYNERGY (Boston Scientific) 3.5 mm×20 mm DES implanted at nominal pressures followed by POT and kissing. B) SYNERGY (Boston Scientific) 4 mm×20 mm DES implanted at low pressure followed by POT and kissing. Cr: chromium; DES: drug-eluting stent; LAD: left anterior descending artery; LCx: left circumflex artery; LM: left main artery; POT: proximal optimisation technique; Pt: platinum

A recent innovation involves a technique where a small contrast injection is delivered during the stent post-dilatation phase, aiming to detect balloon undersizing in angiography-guided procedures^{48,49}. When contrast is able to bypass the inflated balloon, creating a “distal puff sign”, a substantial gap between the stent/balloon and vessel wall, indicating major malapposition, is likely. This phenomenon has been named the “POT-puff sign” when observed during POT⁴⁹.

Of note, during bifurcation PCI, the adaptation of stent geometry at each step of any technique can easily be evaluated by stent enhancement tools (**Figure 3**). Although requiring a slight increased radiation dose, stent enhancement acquisition

is extremely helpful whenever uncertainty regarding the achievement of appropriate stent geometry exists.

SB rewiring site check

SB rewiring⁵⁰ is a key step in any bifurcation PCI in which the SB is treated, as the specific site where the wire crosses the stent struts influences the shape of the main vessel (MV) stent after SB dilatation. Accordingly, different rewiring sites are considered more appropriate depending on the different bifurcation PCI technique used. Current evidence supports the following concepts:

1. In stepwise provisional procedures (including those completed with double stenting according to T/TAP or culotte), the most favourable SB rewiring site is distal (close to the bifurcation carina)³;
2. In crushing procedures, SB rewiring should be non-distal (away from the bifurcation carina)³.

OCT represents the gold standard imaging modality to assess the rewiring site in bifurcation interventions⁸, and OCT-guided distal rewiring has been proven to be associated with more favourable stent healing⁵¹. Furthermore, a recent trial showing the superiority of OCT guidance in complex bifurcation PCI required, as part of the OCT-guided protocol, that operators confirm the ideal SB rewiring site⁵². In the absence of OCT guidance, it is self-evident that operators should pay maximum attention when manipulating the wire through the stent cells towards the SB, aiming at increasing the chance to rewire the most appropriate site according to the selected technique.

In the stepwise provisional technique, a pullback manoeuvre (from dMV to pMV) with an appropriately shaped wire tip increases the likelihood of distal rewiring^{3,50}. Angiography may be used to confirm the achievement of the expected position. **Figure 4** shows an example of distal rewiring assessed by angiography, resulting in an optimal OCT result. When the angiography is not reassuring, it can be useful to

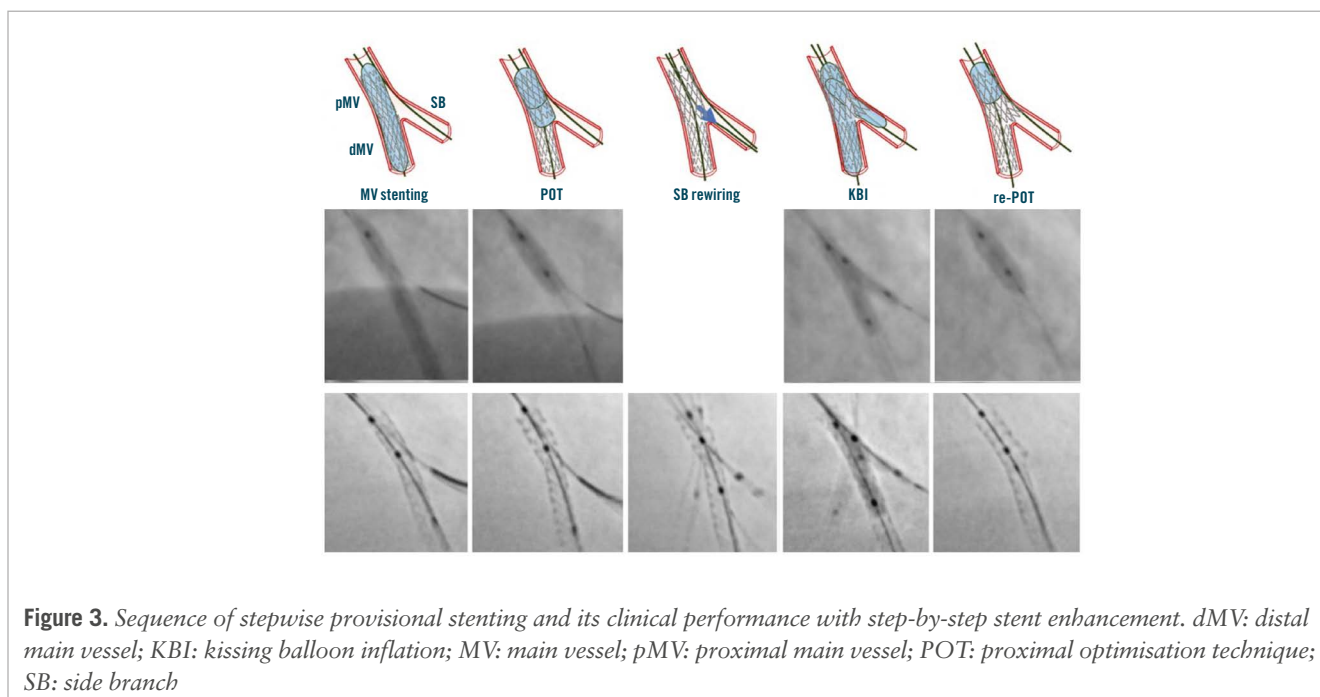


Figure 3. Sequence of stepwise provisional stenting and its clinical performance with step-by-step stent enhancement. dMV: distal main vessel; KBI: kissing balloon inflation; MV: main vessel; pMV: proximal main vessel; POT: proximal optimisation technique; SB: side branch

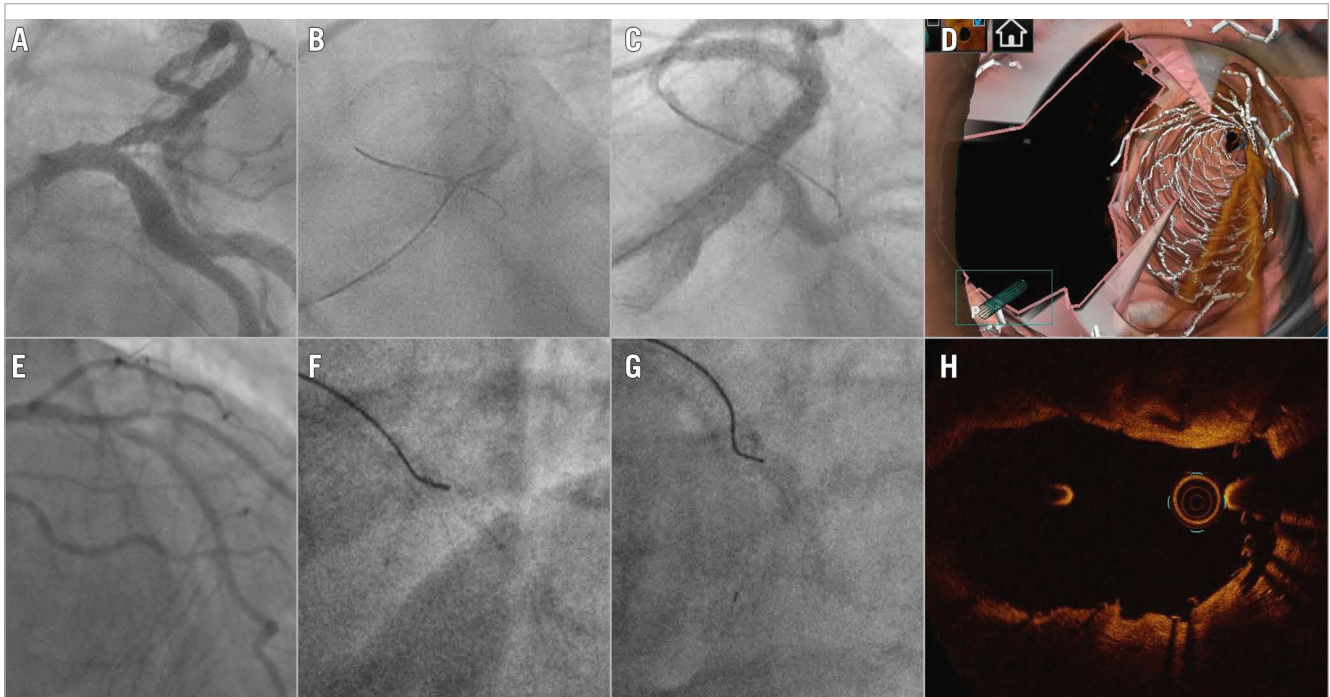


Figure 4. Optimal SB rewiring site check by angiography resulting in good OCT results after 1-stent (A-D) and 2-stent techniques (E-H). A) Baseline angiography in a patient treated by provisional. B) “Pullback rewiring” manoeuvre. C) Angiography confirming the achievement of distal rewiring. D) Post-PCI 3D OCT showing wide opening of the side branch. E) Baseline angiography in a patient treated by DK crush. F) Advancement of the wire towards the side branch ostium after balloon crush; G) Fluoroscopic image confirming the “non-distal” rewiring site. H) Post-PCI OCT at the level of bifurcation showing optimal crushing of the side branch stent.

use a third wire to check if it is possible to wire closer to the carina.

In the setting of DK crush procedures, the appropriateness of stent crushing is considered pivotal to streamline a controlled rewiring³. In such cases, the wire tip should be shaped to be oriented toward the SB, in order to avoid distal crossing³. As soon as the wire crosses the crushed stent, fluoroscopy should be used to confirm the non-distal crossing site of the radiopaque wire tip (**Figure 4**).

Procedural complications during angiography-guided PCI

Bifurcation stenting poses considerable technical challenges, and the absence of ICI guidance heightens the risk of complications while making it difficult to identify the underlying causes. Generally, adhering to a validated technique and following the recommended steps minimises the risk of suboptimal procedural outcomes⁴⁶. However, the inherent complexity associated with bifurcation PCI, and the clinical conditions in which they are performed, often lead to stent imperfections. Their prompt recognition is crucial to mitigating the risk of major clinical pitfalls^{4,5}. Following stent implantation and/or rewiring, any difficulty in balloon delivery within the MV or SB may reflect either stent deformation induced by the guide catheter or device interaction or imperfect stent geometry achieved in the previous steps of the bifurcation stenting techniques. As a common example, resistance when advancing the SB balloon through the MV stent struts may

arise from inadequate POT, wire wrapping, or abluminal MV stent wiring. Prompt recognition of the underlying mechanistic cause allows the appropriate manoeuvres (removal of the SB wire, repetition of POT with a larger balloon) to be performed, avoiding further complications^{4,5}. In such circumstances, stent enhancement imaging is highly informative, as displayed in **Figure 5**. Even in the presence of a satisfactory angiographic result, especially in the setting of 2-stent techniques, a post-PCI stent enhancement image acquisition has the potential to provide additional information about the real stent expansion/conformation achieved. **Figure 5** shows some examples of incomplete SB ostium coverage and undesirable displacement of the neocarina detected by stent enhancement in the presence of a good angiographic result. A similar approach is advisable in the presence of intraprocedural thrombus formation (**Figure 6**).

Finally, whenever a procedural issue arises, and angiographic assessment or stent enhancement fail to elucidate its cause, operators should consider the use of ICI (IVUS or OCT according to operator experience) to better identify the aetiology and optimise the result.

Conclusions

ICI is increasingly considered to provide gold standard guidance for CBL PCI, with evidence demonstrating superior results to angiography alone. However, education and access to technologies remain a major barrier to ICI adoption, and the vast majority of CBL PCI, worldwide, are undertaken with angiographic guidance alone. As shown in the **Central illustration**, the key points for

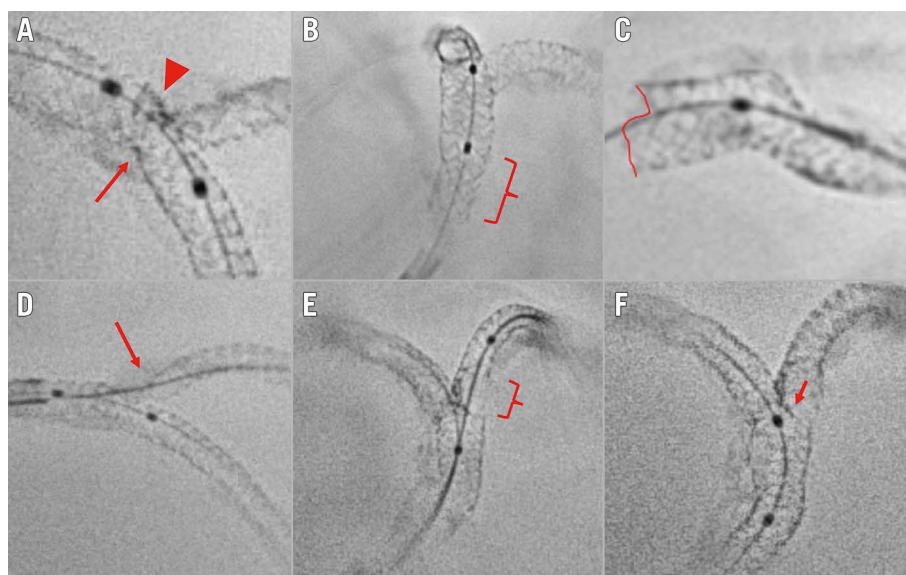


Figure 5. Suboptimal stent implantation revealed by stent enhancement imaging during bifurcation PCI. A) Stent underexpansion caused by the calcified plaque (arrow); the incomplete crush of the SB stent (arrowhead). B) Incomplete POT in the proximal segment of the LM stent (brace). C) Partial stent deformation caused by the guiding catheter at the LM ostium. D) Uncovered SB ostium (arrow) due to a too distal stent implantation. E) Abluminal SB rewiring and SB stent deformation after kissing balloon inflation (brace). F) Neocarina displacement (arrow) towards the SB ostium caused by a too distal final POT. LM: left main artery; PCI: percutaneous coronary intervention; POT: proximal optimisation technique; SB: side branch

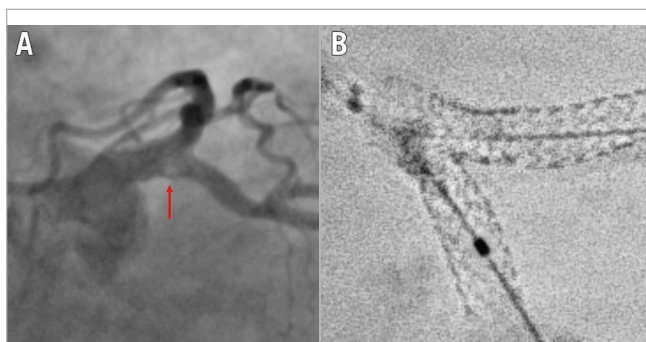

Figure 6. Example of recognised cause for intraprocedural thrombus formation during a 2-stent bifurcation stenting procedure. A) Intraprocedural angiography showing filling defect (arrow) at the SB ostium during a DK crush procedure on the LM. B) Stent enhancement revealing major deformation after kissing balloon inflation due to abluminal LM stent wiring. DK: double-kissing; LM: left main artery; SB: side branch

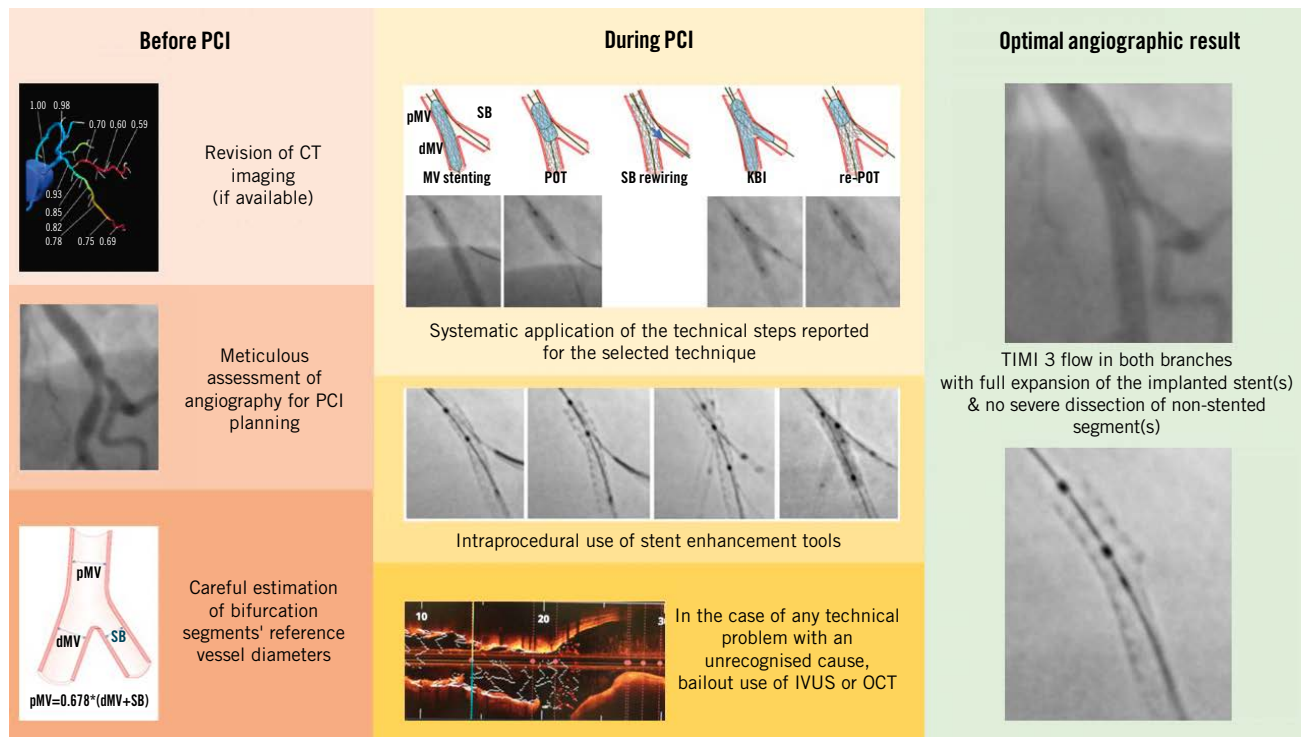
achieving an optimal angiography-guided PCI include a thorough analysis of pre-PCI images (CTA, multiple angiographic views, QCA vessel estimation), a systematic application of the technical steps suggested for a given selected technique, an intraprocedural or post-PCI use of stent enhancement, and a low threshold for bailout use of intravascular imaging.

Authors' affiliations

1. Department of Cardiovascular Sciences, Fondazione Policlinico Universitario A. Gemelli IRCCS, Rome, Italy;

2. Università Cattolica del Sacro Cuore, Rome, Italy; 3. Ramsay Générale de Santé – Institut cardiovasculaire Paris Sud, Hôpital Privé Jacques Cartier, Massy, France; 4. Department of Cardiology B, Odense Universitets Hospital & University of Southern Denmark, Odense, Denmark; 5. Department of Interventional Cardiology, Cardiovascular Hospital, Hospices Civils de Lyon, Lyon, France and INSERM U1060, CarMeN Laboratory, Université de Lyon, Lyon, France; 6. Cardiovascular Center Aalst, OLV Clinic, Aalst, Belgium; 7. Department of Interventional Cardiology, Institute of Cardiology, Jagiellonian University Medical College, Kraków, Poland and Clinical Department of Interventional Cardiology, Saint John Paul II Hospital, Kraków, Poland; 8. Department of Cardiology, Poznan University of Medical Sciences, Poznan, Poland; 9. Heart Centre, Saga-Ken Medical Centre Koseikan, Saga, Japan; 10. Interventional Cardiology Unit, Ospedale Civile Sondrio, Sondrio, Italy; 11. Department of Cardiology, Reina Sofía Hospital, University of Córdoba (IMIBIC), Córdoba, Spain; 12. Division of Cardiovascular Medicine, Center for Digital Cardiovascular Innovations, University of Miami, Miller School of Medicine, Miami, FL, USA; 13. Sussex Cardiac Centre, Brighton and Sussex University Hospitals, Brighton, United Kingdom; 14. Division of Cardiology and Angiology II, University Heart Center Freiburg-Bad Krozingen, Bad Krozingen, Germany; 15. Department of Cardiology, Bristol Heart Institute, University Hospitals Bristol & Weston NHSFT, Bristol, United Kingdom and University of Bristol, Bristol, United Kingdom; 16. Vita-Salute San Raffaele University, Milan, Italy; 17. Interventional Cardiology Unit, San Raffaele Scientific Institute, Milan, Italy; 18. Clinique Saint-Augustin – Elsan, Bordeaux, France; 19. Oxford Heart Centre, Oxford University Hospitals NHS Foundation Trust,

Key points for achieving an optimal angiography-guided PCI.



Francesco Burzotta *et al.* • *EuroIntervention* 2024;20:e915-e926 • DOI: 10.4244/EIJ-D-24-00160

The key points for achieving an optimal angiography-guided PCI include a thorough analysis of pre-PCI images (computed tomography angiography, multiple angiographic views, quantitative coronary angiography vessel estimation), a systematic application of the technical steps suggested for a given selected technique, an intraprocedural or post-PCI use of stent enhancement and a low threshold for bailout use of intravascular imaging. CT: computed tomography; dMV: distal main vessel; IVUS: intravascular ultrasound; KBI: kissing balloon inflation; MV: main vessel; OCT: optical coherence tomography; PCI: percutaneous coronary intervention; pMV: proximal main vessel; POT: proximal optimisation technique; SB: side branch; TIMI: Thrombolysis in Myocardial Infarction

Oxford, United Kingdom; 20. Department of Cardiology, National University of Ireland Galway (NUIG), Galway, Ireland and CORRIB Research Centre for Advanced Imaging and Core Laboratory, Galway, Ireland; 21. Department of Cardiology, Clinical Center of Serbia, Belgrade, Serbia and Faculty of Medicine, University of Belgrade, Belgrade, Serbia

Conflict of interest statement

F. Burzotta has received speaker fees from Medtronic, Abiomed, Abbott, and Terumo. J.F. Lassen has received speaker fees from Medtronic, Boston Scientific, Biotronik, and Abbott. R. Albiero has received speaker fees from Medtronic and Abbott. J. Legutko has received speaker fees from Abbott, Insight Lifetech, Philips, and Procardia. M. Pan has received speaker fees from Abbott, Boston Scientific, and Asahi. Y.S. Chatzizisis has received speaker fees/consultancy/research funding from Boston Scientific and Medtronic; and is co-founder of ComKardia Inc. T.W. Johnson has received speaker/consultancy fees from Abbott, Boston Scientific, Cordis, Medtronic, Shockwave Medical, and Terumo; and

has received research funding from Abbott. A. Chieffo has received speaker/consultant fees from Abbott, Abiomed, Biosensors, Boston Scientific, Medtronic, and Menarini. G. Stankovic has received speaker fees from Medtronic, Abbott, Boston Scientific, and Terumo. M. Lesiak has received speaker fees from Abbott, Biotronik, Boston Scientific, Medtronic, Philips, and Terumo. T. Lefèvre has received minor fees from Terumo, Boston Scientific, Abbott, and Edwards Lifesciences. C. Collet has received a research grant and speaker fees and been on advisory board for Boston Scientific; has received a research grant and speaker fees from GE HealthCare, Insight Lifetech, Siemens Healthineers, HeartFlow, and Shockwave Medical; has received a research grant from Medis Medical Imaging, and Pie Medical; has stock options in Medyria; and has been a research director and equity holder of CoreAalst. O. Darremont reports support from Boston Scientific, Abbott, and Edwards Lifesciences. P.W. Serruys has received consulting fees from SMT, Meril Life Sciences, Novartis, Philips, and Xeltis. The other authors have no conflict of interest to declare.

References

- Burzotta F, Lassen JF, Lefèvre T, Banning AP, Chatzizisis YS, Johnson TW, Ferenc M, Rathore S, Albiero R, Pan M, Darremont O, Hildick-Smith D, Chieffo A, Zimarino M, Louvard Y, Stankovic G. Percutaneous coronary intervention for bifurcation coronary lesions: the 15th consensus document from the European Bifurcation Club. *EuroIntervention*. 2021;16:1307-17.
- Burzotta F, Lassen JF, Banning AP, Lefèvre T, Hildick-Smith D, Chieffo A, Darremont O, Pan M, Chatzizisis YS, Albiero R, Louvard Y, Stankovic G. Percutaneous coronary intervention in left main coronary artery disease: the 13th consensus document from the European Bifurcation Club. *EuroIntervention*. 2018;14:112-20.
- Burzotta F, Lassen JF, Louvard Y, Lefèvre T, Banning AP, Darremont O, Pan M, Hildick-Smith D, Chieffo A, Chatzizisis YS, Džavík V, Gwon HC, Hikichi Y, Murasato Y, Koo BK, Chen SL, Serruys P, Stankovic G. European Bifurcation Club white paper on stenting techniques for patients with bifurcated coronary artery lesions. *Catheter Cardiovasc Interv*. 2020;96:1067-79.
- Albiero R, Burzotta F, Lassen JF, Lefèvre T, Banning AP, Chatzizisis YS, Johnson TW, Ferenc M, Pan M, Darremont O, Hildick-Smith D, Chieffo A, Louvard Y, Stankovic G. Treatment of coronary bifurcation lesions, part I: implanting the first stent in the provisional pathway. The 16th expert consensus document of the European Bifurcation Club. *EuroIntervention*. 2022;18:e362-76.
- Lassen JF, Albiero R, Johnson TW, Burzotta F, Lefèvre T, Iles TL, Pan M, Banning AP, Chatzizisis YS, Ferenc M, Džavík V, Milasinovic D, Darremont O, Hildick-Smith D, Louvard Y, Stankovic G. Treatment of coronary bifurcation lesions, part II: implanting two stents. The 16th expert consensus document of the European Bifurcation Club. *EuroIntervention*. 2022;18:457-70.
- Pan M, Lassen JF, Burzotta F, Ojeda S, Albiero R, Lefèvre T, Hildick-Smith D, Johnson TW, Chieffo A, Banning AP, Ferenc M, Darremont O, Chatzizisis YS, Louvard Y, Stankovic G. The 17th expert consensus document of the European Bifurcation Club – techniques to preserve access to the side branch during stepwise provisional stenting. *EuroIntervention*. 2023;19:26-36.
- Mintz GS, Lefèvre T, Lassen JF, Testa L, Pan M, Singh J, Stankovic G, Banning AP. Intravascular ultrasound in the evaluation and treatment of left main coronary artery disease: a consensus statement from the European Bifurcation Club. *EuroIntervention*. 2018;14:e467-74.
- Onuma Y, Katagiri Y, Burzotta F, Holm NR, Amabile N, Okamura T, Mintz GS, Darremont O, Lassen JF, Lefèvre T, Louvard Y, Stankovic G, Serruys PW. Joint consensus on the use of OCT in coronary bifurcation lesions by the European and Japanese bifurcation clubs. *EuroIntervention*. 2019;14:e1568-77.
- Candrea A, Gallinoro E, Fournier S, Izaga E, Finet G, De Bruyne B, Gutiérrez-Barrios A. Absolute Blood Flow in the Left Main Coronary Artery and Its Distribution. *JACC Cardiovasc Interv*. 2021;14:482-4.
- Finet G, Gilard M, Perrenot B, Rioufol G, Motreff P, Gavitt L, Prost R. Fractal geometry of arterial coronary bifurcations: a quantitative coronary angiography and intravascular ultrasound analysis. *EuroIntervention*. 2008;3:490-8.
- Zieliński J, Nowosielski JM. Finet's Law as a Special Case of the Generalised Murray's Law. *SN Comput Sci*. 2020;1:42.
- Huo Y, Finet G, Lefèvre T, Louvard Y, Moussa I, Kassab GS. Optimal diameter of diseased bifurcation segment: a practical rule for percutaneous coronary intervention. *EuroIntervention*. 2012;7:1310-6.
- Kassab GS, Finet G. Anatomy and function relation in the coronary tree: from bifurcations to myocardial flow and mass. *EuroIntervention*. 2015;11 Suppl V:V13-7.
- Arunothayaraj S, Behan MW, Lefèvre T, Lassen JF, Chieffo A, Stankovic G, Burzotta F, Pan M, Ferenc M, Hovasse T, Spence MS, Brunel P, Cotton JM, Cockburn J, Carrié D, Baumbach A, Maeng M, Louvard Y, Hildick-Smith D. Stepwise provisional versus systematic culotte for stenting of true coronary bifurcation lesions: five-year follow-up of the multicentre randomised EBC TWO Trial. *EuroIntervention*. 2023;19:e297-304.
- Hildick-Smith D, Egred M, Banning A, Brunel P, Ferenc M, Hovasse T, Wlodarczyk A, Pan M, Schmitz T, Silvestri M, Erglis A, Kretov E, Lassen JF, Chieffo A, Lefèvre T, Burzotta F, Cockburn J, Darremont O, Stankovic G, Morice MC, Louvard Y. The European bifurcation club Left Main Coronary Stent study: a randomized comparison of stepwise provisional vs. systematic dual stenting strategies (EBC MAIN). *Eur Heart J*. 2021;42:3829-39.
- Di Gioia G, Sonck J, Ferenc M, Chen SL, Colaiori I, Gallinoro E, Mizukami T, Kodeboina M, Nagumo S, Franco D, Bartunek J, Vanderheyden M, Wyffels E, De Bruyne B, Lassen JF, Bennett J, Vassilev D, Serruys PW, Stankovic G, Louvard Y, Barbato E, Collet C. Clinical Outcomes Following Coronary Bifurcation PCI Techniques: A Systematic Review and Network Meta-Analysis Comprising 5,711 Patients. *JACC Cardiovasc Interv*. 2020;13:1432-44.
- Lunardi M, Louvard Y, Lefèvre T, Stankovic G, Burzotta F, Kassab GS, Lassen JF, Darremont O, Garg S, Koo BK, Holm NR, Johnson TW, Pan M, Chatzizisis YS, Banning AP, Chieffo A, Dudek D, Hildick-Smith D, Garot J, Henry TD, Dangas G, Stone G, Krucoff MW, Cutlip D, Mehran R, Wijns W, Sharif F, Serruys PW, Onuma Y. Definitions and Standardized Endpoints for Treatment of Coronary Bifurcations. *EuroIntervention*. 2023;19:e807-31.
- Chen X, Li X, Zhang JJ, Han Y, Kan J, Chen L, Qiu C, Santoso T, Paiboon C, Kwan TW, Sheiban I, Leon MB, Stone GW, Chen SL; DKCRUSH-V Investigators. 3-Year Outcomes of the DKCRUSH-V Trial Comparing DK Crush With Provisional Stenting for Left Main Bifurcation Lesions. *JACC Cardiovasc Interv*. 2019;12:1927-37.
- Barbato E, Gallinoro E, Abdel-Wahab M, Andreini D, Carrié D, Di Mario C, Dudek D, Escaned J, Fajadet J, Guagliumi G, Hill J, McEntegart M, Mashayekhi K, Mezilis N, Onuma Y, Reczuch K, Shlofmitz R, Stefanini G, Tarantini G, Toth GG, Vaquerizo B, Wijns W, Ribichini FL. Management strategies for heavily calcified coronary stenoses: an EAPCI clinical consensus statement in collaboration with the EURO4C-PCR group. *Eur Heart J*. 2023;44:4340-56.
- Knuuti J, Wijns W, Saraste A, Capodanno D, Barbato E, Funck-Brentano C, Prescott E, Storey RF, Deaton C, Cuisset T, Agewall S, Dickstein K, Edvardsen T, Escaned J, Gersh BJ, Svtil P, Gilard M, Hasdai D, Hatala R, Mahfoud F, Masip J, Muneretto C, Valgimigli M, Achenbach S, Bax JJ; ESC Scientific Document Group. 2019 ESC Guidelines for the diagnosis and management of chronic coronary syndromes. *Eur Heart J*. 2020;41:407-77.
- Serruys PW, Kotoku N, Nørgaard BL, Garg S, Nieman K, Dweck MR, Bax JJ, Knuuti J, Narula J, Perera D, Taylor CA, Leipsic JA, Nicol ED, Piazza N, Schultz CJ, Kitagawa K, Bruyne B, Collet C, Tanaka K, Mushtaq S, Belmonte M, Dudek D, Zlahoda-Huzior A, Tu S, Wijns W, Sharif F, Budoff MJ, Mey J, Andreini D, Onuma Y. Computed tomographic angiography in coronary artery disease. *EuroIntervention*. 2023;18:e1307-27.
- Andreini D, Collet C, Leipsic J, Nieman K, Bittencourt M, De Mey J, Buls N, Onuma Y, Mushtaq S, Conte E, Bartorelli AL, Stefanini G, Sonck J, Knaapen P, Ghoshhajra B, Serruys PW. Pre-procedural planning of coronary revascularization by cardiac computed tomography: An expert consensus document of the Society of Cardiovascular Computed Tomography. *EuroIntervention*. 2022;18:e872-87.
- Kotoku N, Ninomiya K, Ding D, O'Leary N, Tobe A, Miyashita K, Masuda S, Kageyama S, Garg S, Leipsic JA, Mushtaq S, Andreini D, Tanaka K, de Mey J, Wijns W, Tu S, Piazza N, Onuma Y, Serruys PW. Murray law-based quantitative flow ratio to assess left main bifurcation stenosis: selecting the angiographic projection matters. *Int J Cardiovasc Imaging*. 2024;40:195-206.
- Collet C, Sonck J, Leipsic J, Monizzi G, Buytaert D, Kitslaar P, Andreini D, De Bruyne B. Implementing Coronary Computed Tomography Angiography in the Catheterization Laboratory. *JACC Cardiovasc Imaging*. 2021;14:1846-55.
- Lee SH, Lee JM, Song YB, Park TK, Yang JH, Hahn JY, Choi SH, Gwon HC, Lee SH, Kim SM, Choe YH, Choi JH. Prediction of side branch occlusions in percutaneous coronary interventions by coronary computed tomography: the CT bifurcation score as a novel tool for predicting intra-procedural side branch occlusion. *EuroIntervention*. 2019;15:e788-95.
- Monizzi G, Sonck J, Nagumo S, Buytaert D, Van Hoe L, Grancini L, Bartorelli AL, Vanhoenacker P, Simons P, Bladt O, Wyffels E, De Bruyne B, Andreini D, Collet C. Quantification of calcium burden by coronary CT

- angiography compared to optical coherence tomography. *Int J Cardiovasc Imaging*. 2020;36:2393-402.
27. Kim HY, Doh JH, Lim HS, Nam CW, Shin ES, Koo BK, Lee JM, Park TK, Yang JH, Song YB, Hahn JY, Choi SH, Gwon HC, Lee SH, Kim SM, Choe Y, Choi JH. Identification of Coronary Artery Side Branch Supplying Myocardial Mass That May Benefit From Revascularization. *JACC Cardiovasc Interv*. 2017;10:571-81.
 28. Collet C, Collison D, Mizukami T, McCartney P, Sonck J, Ford T, Munhoz D, Berry C, De Bruyne B, Oldroyd K. Differential Improvement in Angina and Health-Related Quality of Life After PCI in Focal and Diffuse Coronary Artery Disease. *JACC Cardiovasc Interv*. 2022;15:2506-18.
 29. Sonck J, Nagumo S, Norgaard BL, Otake H, Ko B, Zhang J, Mizukami T, Maeng M, Andreini D, Takahashi Y, Jensen JM, Ihdahid A, Heggermont W, Barbato E, Mileva N, Munhoz D, Bartunek J, Updegrove A, Collinsworth A, Penicka M, Van Hoe L, Leipsic J, Koo BK, De Bruyne B, Collet C. Clinical Validation of a Virtual Planner for Coronary Interventions Based on Coronary CT Angiography. *JACC Cardiovasc Imaging*. 2022;15:1242-55.
 30. Ohashi H, Zivelonghi C, Seki R, Sakai K, Collet C, Scott B, Vermeersch P, Agostoni P. Virtual 2-Stent Bifurcation Percutaneous Coronary Intervention Using the Fractional Flow Reserve Computed Tomography Planner. *JACC Cardiovasc Interv*. 2023;16:863-4.
 31. Grundeken MJ, Collet C, Ishibashi Y, Généreux P, Muramatsu T, LaSalle L, Kaplan AV, Wykrzykowska JJ, Morel MA, Tijssen JG, de Winter RJ, Onuma Y, Leon MB, Serruys PW. Visual estimation versus different quantitative coronary angiography methods to assess lesion severity in bifurcation lesions. *Catheter Cardiovasc Interv*. 2018;91:1263-70.
 32. Grundeken MJ, Ishibashi Y, Ramcharitar S, Tuinenburg JC, Reiber JH, Tu S, Aben JP, Girasis C, Wykrzykowska JJ, Onuma Y, Serruys PW. The need for dedicated bifurcation quantitative coronary angiography (QCA) software algorithms to evaluate bifurcation lesions. *EuroIntervention*. 2015;11 Suppl V:V44-9.
 33. Kubo T, Akasaka T, Shite J, Suzuki T, Uemura S, Yu B, Kozuma K, Kitabata H, Shinke T, Habara M, Saito Y, Hou J, Suzuki N, Zhang S. OCT compared with IVUS in a coronary lesion assessment: the OPUS-CLASS study. *JACC Cardiovasc Imaging*. 2013;6:1095-104.
 34. Lee PH, Hong SJ, Kim HS, Yoon YW, Lee JY, Oh SJ, Lee JS, Kang SJ, Kim YH, Park SW, Lee SW, Lee CW; GUIDE-DES Trial Research Group. Quantitative Coronary Angiography vs Intravascular Ultrasonography to Guide Drug-Eluting Stent Implantation: A Randomized Clinical Trial. *JAMA Cardiol*. 2024;13:e240059.
 35. Lefevre T, Bernard A, Bayet G. Intérêt de l'étalonnage des ballons d'angioplastie coronaire [Value of the calibration of coronary angioplasty balloons]. *Arch Mal Coeur Vaiss*. 1989;82:1839-42.
 36. Amstutz C, Behr J, Krebs S, Haerlin A, Vogel R, Zurbuchen A, Burger J. Design of percutaneous transluminal coronary angioplasty balloon catheters. *Biomed Eng Online*. 2023;22:94.
 37. Skowroński J, Wolny R, Jastrzębski J, Tyczyński P, Szlazak K, Pręgowski J, Mintz GS, Liżewska K, Świeszkowski W, Chmielak Z, Witkowski A. Impact of the Balloon Inflation Time and Pattern on the Coronary Stent Expansion. *J Interv Cardiol*. 2019;2019:6945372.
 38. Dong P, Colmenarez J, Lee J, Hassani NS, Wilson DL, Bezerra HG, Gu L. Load-sharing characteristics of stenting and post-dilation in heavily calcified coronary artery. *Sci Rep*. 2023;13:16878.
 39. Trindade IS, Sarmiento-Leite R, Santos de Freitas M, Gottschall CA. Determination of the minimum inflation time necessary for total stent expansion and apposition: an in vitro study. *J Invasive Cardiol*. 2008;20:396-8.
 40. Iwamoto Y, Okamoto M, Hashimoto M, Fukuda Y, Iwamoto A, Iwasaki T, Kinoshita H, Kihara Y. Better stent expansion by two-time inflation of stent balloon and its responsible mechanism. *J Cardiol*. 2012;59:160-6.
 41. Hovasse T, Mylotte D, Garot P, Salvatella N, Morice MC, Chevalier B, Pichard A, Lefèvre T. Duration of balloon inflation for optimal stent deployment: five seconds is not enough. *Catheter Cardiovasc Interv*. 2013;81:446-53.
 42. Saha M, Poliacikova P, de Belder A, Holmberg S, Clarke M, Rajani R, Hildick-Smith D. Coronary stent implantation technique: prolonged inflation time maximizes stent expansion. *J Invasive Cardiol*. 2013;25:28-31.
 43. Ann SH, Chung JW, DE Jin C, Lee JH, Kim JM, Garg S, Shin ES. Better inflation time of stent balloon for second-generation drug-eluting stent expansion and apposition: an optical coherence tomography study. *J Interv Cardiol*. 2014;27:171-6.
 44. Y. Hikichi. Importance of stent selection in LMT Bifurcation stenting – Insights from the bench test, distal low pressure dilatation technique. EBC meeting. 13 Oct 2023. Warsaw, Poland.
 45. Burzotta F, Aurigemma C, Paraggio L, Romagnoli E, Leone AM, Vergallo R, Cangemi S, Bianchini F, Trani C. Under-deployment of extra-large drug-eluting stent: an adapted provisional technique for selected patients with distal lesions in large left main. *Minerva Cardiol Angiol*. 2023;71:20-6.
 46. Cangemi S, Burzotta F, Bianchini F, DeVos A, Valenzuela T, Trani C, Aurigemma C, Romagnoli E, Lassen JF, Stankovic G, Iazzo PA. Configuration of two-stent coronary bifurcation techniques in explanted beating hearts: the MOBBEM study. *EuroIntervention*. 2023;19:e423-31.
 47. Lombardi M, Chiabrando JG, Romagnoli E, D'Amario D, Leone AM, Aurigemma C, Montone RA, Ricchiuto A, Biondi-Zoccai G, Burzotta F, Jang IK, Escaned J, Trani C, Porto I, Crea F, Vergallo R. Impact of acute and persistent stent malapposition after percutaneous coronary intervention on adverse cardiovascular outcomes. *Minerva Cardiol Angiol*. 2023;71:525-34.
 48. Vural M, Hancıoğlu E. A Novel Technique for Stent Optimization: A Stepwise STENT PUFF Sign and POT PUFF Sign. *Turk Kardiyol Dern Ars*. 2024;52:77-8. English.
 49. Aminfar F, Rubimbura V, Maillard L, Noble S, Rangé G, Belle L, Derimay F, Bellemain-Appaix A, Al Karaky A, Morelle JF, Sideris G, Motreff P, Muller O, Adjedj J. The POT-PUFF sign: an angiographic mark of stent malapposition during proximal optimisation. *EuroIntervention*. 2023;18:1456-7.
 50. Burzotta F, De Vita M, Sgueglia G, Todaro D, Trani C. How to solve difficult side branch access? *EuroIntervention*. 2010;6 Suppl J:J72-80.
 51. Yamawaki M, Okamura T, Nagoshi R, Fujimura T, Murasato Y, Ono S, Serikawa T, Hikichi Y, Norita H, Nakao F, Sakamoto T, Shinke T, Shite J. Vascular healing after kissing balloon inflation: Nine-month 3D optical coherence tomography analysis in corelab. *Int J Cardiol Heart Vasc*. 2022;40:101034.
 52. Holm NR, Andreasen LN, Neghabat O, Laanmets P, Kumsars I, Bennett J, Olsen NT, Odenstedt J, Hoffmann P, Dens J, Chowdhary S, O'Kane P, Bülow Rasmussen SH, Heigert M, Havndrup O, Van Kuijk JP, Biscaglia S, Mogensen LJH, Henareh L, Burzotta F, H Eek C, Mylotte D, Llinas MS, Koltowski L, Knaepen P, Calic S, Witt N, Santos-Pardo I, Watkins S, Lönborg J, Kristensen AT, Jensen LO, Calais F, Cockburn J, McNeice A, Kajander OA, Heestermans T, Kische S, Eftekhari A, Spratt JC, Christiansen EH; OCTOBER Trial Group. OCT or Angiography Guidance for PCI in Complex Bifurcation Lesions. *N Engl J Med*. 2023;389:1477-87.
 53. G. Finet. UM technical features supported by the bench tests. EBC meeting. 13 Oct 2017. Porto, Portugal.

Supplementary data

Supplementary Figure 1. Example of advanced processing pre-procedural coronary CT angiography used to guide bifurcation PCI.

Supplementary Figure 2. Impact of the number of balloon inflations on a balloon's compliance.

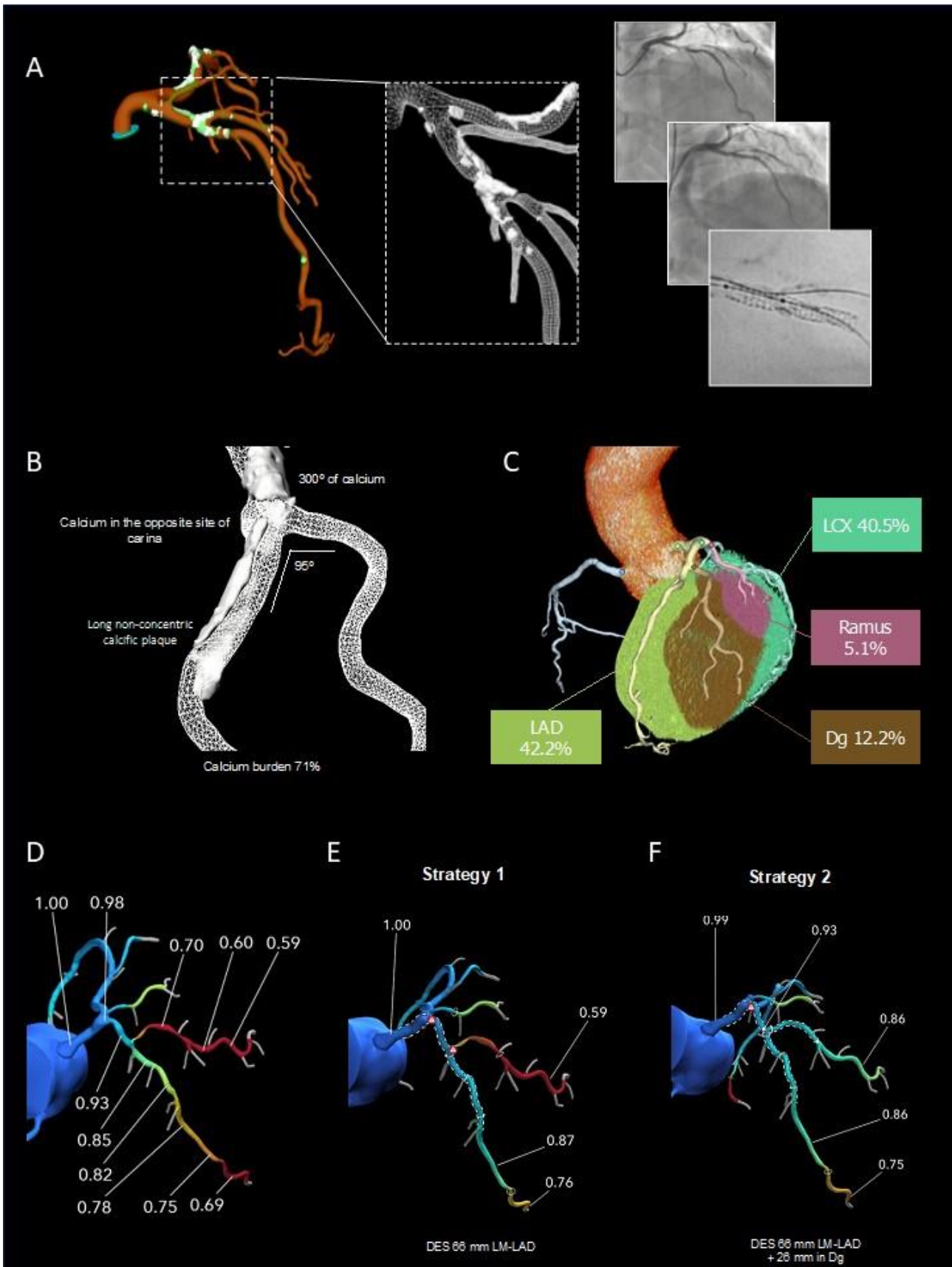
The supplementary data are published online at:

<https://eurointervention.pcronline.com/>

doi/10.4244/EIJ-D-24-00160



Supplementary data

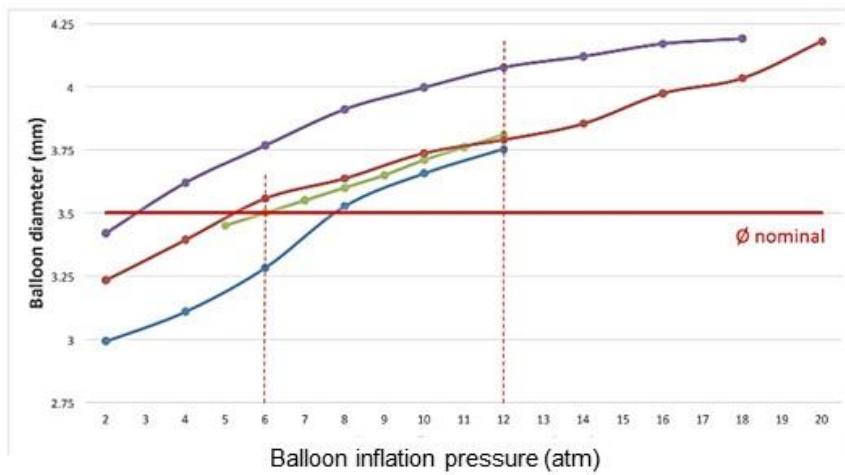


Supplementary Figure 1. Example of advanced processing preprocedural coronary CT angiography used to guide bifurcation PCI.

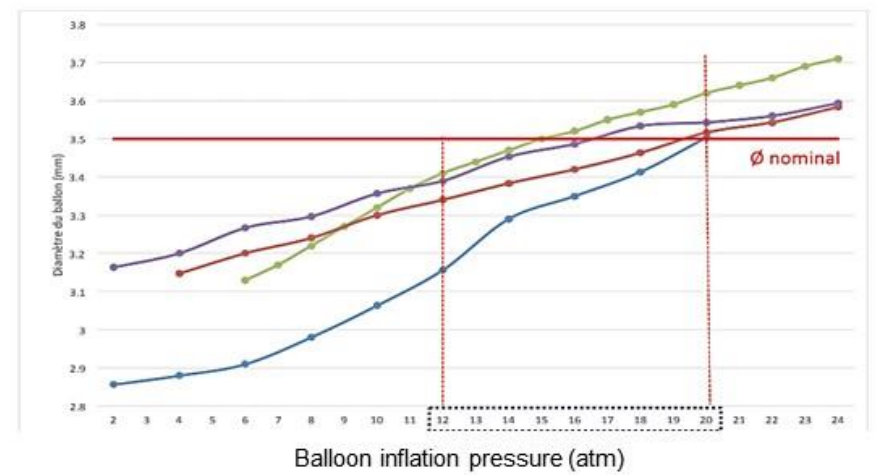
Panel A. At the left side, three-dimensional coronary CT reconstruction of a patient with a left anterior descending/diagonal branch bifurcation lesion. The dashed rectangle shows the calcium reconstruction in 3D, and the left side shows three angiographies pre-PCI (on top), after stent implantation with compromise of the diagonal branch (mid) and stent enhancement showing stent underexpansion due to the calcified plaque. **Panel B** shows a 3D calcium reconstruction highlighting the bifurcation angle and calcium characteristics. **Panel C** shows the myocardial mass subtended by the different coronary branches. **Panel D** displays the fractional flow reserve derived from CT (FFR_{CT}) across the left main and left anterior descending/diagonal bifurcation. **Panel E and F** show the predicted, “virtual”, results potentially achieved by, respectively, stenting the main branch only (strategy 1) and using a two-stent bifurcation technique (strategy 2).

IMPACT OF THE NUMBER OF BALLOON INFLATIONS ON BALLOON'S COMPLIANCE

A. Example of semi-compliant balloon



B. Example of non-compliant balloon



—●— Manufacturer
 —●— Inflation #1
 —●— Inflation #2
 —●— Inflation #3
 — 3.5mm

Supplementary Figure 2. Impact of the number of balloon inflations on a balloon's compliance.

Panel A: Example of semi-compliant balloon behaviour. Bench tests conducted using Emerge (Boston Scientific) 3.5 x 15 mm balloons. **Panel B:**

Example of non-compliant balloon Bench tests conducted using NC Euphora, Medtronic 3.5 x 15 mm balloons.

Bench test results modified with permission from an oral presentation {53}.