

Outcomes of a preoperative “bridging” strategy with glycoprotein IIb/IIIa inhibitors to prevent perioperative stent thrombosis in patients with drug-eluting stents who undergo surgery necessitating interruption of thienopyridine administration

Laith I. Alshawabkeh^{1,2}, MD; Amit Prasad³, MD; Fima Lenkovsky^{2,4}, MD; Laila F. Makary^{2,4}, MD; Enas S. Kandil^{2,4}, MD; Rick A. Weideman⁵, PharmD; Kevin C. Kelly⁵, PharmD; Bavana V. Rangan¹, BDS, MPH; Subhash Banerjee^{1,2}, MD; Emmanouil S. Brilakis^{1,2*}, MD, PhD

1. Department of Cardiovascular Diseases, VA North Texas Health Care System, Dallas, TX, USA; 2. University of Texas Southwestern Medical Center, Dallas, TX, USA; 3. Department of Cardiovascular Diseases, Oschner Clinic, New Orleans, LA, USA; 4. Department of Anesthesiology, VA North Texas Health Care System, Dallas, TX, USA; 5. Department of Pharmacy, VA North Texas Health Care System, Dallas, TX, USA

KEYWORDS

- bleeding
- drug-eluting stent
- stent thrombosis

Abstract

Aims: Surgery after drug-eluting stent (DES) implantation may be associated with increased risk for perioperative stent thrombosis (ST).

Methods and results: We evaluated the outcomes of 67 patients who underwent non-cardiac (n=51) or cardiac (n=16) surgery after DES implantation at our institution between 2008 and 2010 and who underwent preoperative “bridging” with a glycoprotein IIb/IIIa inhibitor. Surgery occurred after a mean time of 13.9±1.7 and 8.7±2 months post stenting for non-cardiac (NCS) and cardiac surgery, respectively. Glycoprotein IIb/IIIa inhibitors were administered preoperatively for a mean of 7.1±0.4 and 7.8±0.7 days, respectively, then discontinued four to six hours before surgery. Most patients received aspirin through the perioperative period (33 NCS patients and 15 cardiac surgery patients). Clopidogrel was restarted as early as possible in the postoperative period. In the non-cardiac surgery group, two patients (3.9%, 95% confidence intervals 0.5% to 13.5%) suffered acute ST in the immediate postoperative period and four patients suffered major bleeding by the Global Utilisation of Streptokinase and Tissue Plasminogen Activator for Occluded Coronary Arteries (GUSTO) criteria. One cardiac surgery patient had probable ST one hour postoperatively.

Conclusions: In spite of preoperative “bridging” with a glycoprotein IIb/IIIa inhibitor, postoperative stent thrombosis can still occur in patients with prior DES undergoing surgery requiring antiplatelet medication interruption.

*Corresponding author: Dallas VA Medical Center (111A), 4500 South Lancaster Road, Dallas, TX, 75216, USA.
E-mail: esbrilakis@yahoo.com

Introduction

Patients with drug-eluting stents (DES) who subsequently require surgery may be at increased risk for perioperative stent thrombosis, a catastrophic complication with high morbidity and mortality^{1,2}. A recent systematic literature review reported a perioperative stent thrombosis rate of 2.3% if non-cardiac surgery was performed within six months, 1.7% if performed between six and 12 months, and 0.9% if performed more than 12 months from DES implantation³. Thus, delaying surgery for at least 12 months after DES implantation is currently recommended^{4,5}. However, in some patients surgery cannot be delayed and the surgical team requires antiplatelet therapy interruption. Moreover, perioperative DES thrombosis has been reported even several years after DES implantation⁶. Although the optimal perioperative management of such patients remains controversial, administration of a short-acting anticoagulant or antiplatelet regimen has been proposed to minimise the risk for perioperative stent thrombosis⁷⁻¹¹. We describe the outcomes of 67 patients who required non-cardiac or cardiac surgery post DES implantation in whom thienopyridine administration was interrupted preoperatively and glycoprotein IIb/IIIa inhibitor infusion was used as a “bridge” to surgery.

Materials and methods

PATIENTS

We retrospectively reviewed the medical records of 67 consecutive patients who required surgery (51 patients underwent non-cardiac and 16 patients underwent cardiac surgery) after DES implantation at our institution between 2008 and 2010 with thienopyridine administration interruption and who underwent “bridging” with a glycoprotein IIb/IIIa inhibitor. Mean age was 65±1.2 years and all patients were men. During the study period all patients who were considered to have an elevated risk for perioperative stent thrombosis (patients who underwent stent implantation within 12 months prior to surgery, patients who had undergone stenting of the left main coronary artery or proximal left anterior descending artery, patients with diabetes, bifurcation stenting, or a history of stent thrombosis) underwent “bridging” with a glycoprotein IIb/IIIa inhibitor. The study was approved by our institutional review board.

BRIDGING PROTOCOL

Bridging was performed using the following protocol: clopidogrel was discontinued for five to seven days prior to surgery. On the day following clopidogrel discontinuation, patients were admitted to the hospital and were started on intravenous glycoprotein IIb/IIIa inhibitor infusion. The type of glycoprotein IIb/IIIa inhibitor used was at the discretion of the treating physician. Eptifibatid was administered as an intravenous bolus of 180 µg/kg followed by a continuous infusion of 2.0 µg/kg/min. In patients with creatinine clearance <50 ml/min the continuous infusion was lowered to 1.0 µg/kg/min. Tirofiban was administered at a dose of 0.4 µg/kg/min over 30 minutes, followed by 0.1 µg/kg/min in patients with normal renal function. In patients with creatinine clearance <30 ml/min, the tirofiban dose was reduced by 50%. The glycoprotein IIb/IIIa

inhibitor infusion was discontinued four to six hours prior to surgery. Postoperatively, a 600 mg loading dose of clopidogrel was given as early as possible after surgery (as soon as cleared by the surgical team) and then continued at a once-daily dose of 75 mg. If clopidogrel could not be resumed, a recommendation was made to restart the glycoprotein IIb/IIIa infusion two hours after the end of surgery and to continue it for up to six hours after the resumption of clopidogrel treatment.

PATIENT MONITORING

During and after surgery, patients were placed on continuous cardiac and haemodynamic monitoring. Electrocardiograms were obtained in patients who had clinical suspicion for cardiac events and cardiac biomarkers were measured at 12-hour intervals, or earlier if clinically indicated. Stent thrombosis was defined using the Academic Research Consortium criteria¹², and significant bleeding was defined using the Global Utilisation of Streptokinase and Tissue Plasminogen Activator for Occluded Coronary Arteries (GUSTO) criteria¹³.

STATISTICAL ANALYSIS

Continuous variables were reported as mean ± SD or median (interquartile range) and discrete variables were reported as frequencies. Analyses were performed using JMP 8 (SAS Institute, Cary, NC, USA) and SPSS (SPSS Inc., Chicago, IL, USA).

Results

PATIENT CHARACTERISTICS

The clinical characteristics of the study patients are presented in **Table 1**. All patients were men with a high prevalence of atherosclerosis risk factors. The indication for DES implantation for most patients was an acute coronary syndrome. Most of the implanted DES were sirolimus-eluting, but all DES types were included in the study.

SURGERY AND PREOPERATIVE MANAGEMENT

The mean and median times between DES implantation and NCS were 13.9±1.7 and 11 (interquartile range 6-18) months, respectively. The mean and median times between DES implantation and cardiac surgery were 8.7±2.0 and 7.5 (interquartile range 4-10.25) months, respectively (**Table 1**). For non-cardiac surgery, two patients (4%) were considered high risk, 32 (63%) were intermediate and 17 (33%) were low risk. Most non-cardiac surgical procedures were abdominal, head and neck and orthopaedic surgeries (**Table 2**). Aspirin was continued during the perioperative periods in most study patients (65% of those with non-cardiac vs. 94% of those with cardiac surgery, **Table 2**). All cardiac surgery patients underwent coronary artery bypass grafting (CABG), except one patient who underwent combined mitral valve repair and CABG.

PERIOPERATIVE OUTCOMES IN THE NON-CARDIAC SURGERY GROUP

In the non-cardiac surgery group, two patients (3.9%, 95% confidence intervals 0.5% to 13.5%) had angiographically confirmed

Table 1. Baseline characteristics of the study population.

	Non-cardiac surgery (n=51)	Cardiac surgery (n=16)
Age (yrs)*	65±1	64±3
Men, n (%)	51 (100%)	16 (100%)
Hypertension, n (%)	46 (90%)	13 (81%)
Hyperlipidaemia, n (%)	45 (88%)	13 (81%)
Diabetes mellitus, n (%)	22 (43%)	7 (44%)
Prior coronary artery bypass graft surgery, n (%)	11 (22%)	0
Congestive heart failure, n (%)	11 (22%)	5 (31%)
Chronic kidney disease, n (%)	9 (18%)	3 (19%)
Peripheral arterial disease, n (%)	13 (25%)	0
PCI information		
Indication for PCI		
Stable angina, n (%)	12 (24%)	6 (38%)
Acute coronary syndrome, n (%)	31 (61%)	9 (56%)
Other, n (%)	8 (15%)	1 (6%)
PCI target vessel		
Left anterior descending artery, n (%)	23 (29%)	10 (43%)
Circumflex, n (%)	11 (14%)	1 (4%)
Right coronary artery, n (%)	20 (25%)	7 (30%)
Left main, n (%)	4 (5%)	2 (9%)
Saphenous vein graft, n (%)	10 (13%)	0
Other, n (%)	11 (14%)	3 (13%)
Number of vessels treated per patient*	1.53±0.12	1.44±0.16
One vessel, n (%)	32 (63%)	10 (63%)
Two vessels, n (%)	14 (27%)	5 (31%)
Three or more vessels, n (%)	5 (10%)	1 (6%)
Number of stents implanted per patient*	2.37±0.28	1.94±0.027
DES type		
Sirolimus-eluting, n (%)	39 (32%)	9 (29%)
Paclitaxel-eluting, n (%)	32 (26%)	3 (10%)
Zotarolimus-eluting, n (%)	14 (12%)	11 (36%)
Everolimus-eluting, n (%)	27 (22%)	6 (19%)
DES of unknown type†, n (%)	9 (8%)	2 (6%)
Time interval between PCI and surgery (months)*	13.9±1.7	8.7±2.0
<6 months, n (%)	12 (24%)	7 (44%)
6-12 months, n (%)	18 (35%)	7 (44%)
>12 months, n (%)	21 (41%)	2 (14%)
Surgery urgency		
Elective, n (%)	44 (86%)	8 (50%)
Urgent, n (%)	7 (14%)	8 (50%)
Surgery type		
Abdominal, n (%)	14 (27%)	NA
Genitourinary, n (%)	6 (11%)	NA
Vascular, n (%)	2 (4%)	NA
Orthopaedic, n (%)	7 (14%)	NA
Head & neck, n (%)	10 (20%)	NA
Neurosurgery, n (%)	2 (4%)	NA
Endoscopic, n (%)	3 (6%)	NA
Thoracic, n (%)	6 (12%)	NA
Other, n (%)	1 (2%)	NA

BMS: bare metal stents; CKD: chronic kidney disease, defined by the Kidney Disease Outcomes Quality Initiative (K/DOQI) of the National Kidney Foundation (NKF) as either kidney damage or a decreased glomerular filtration rate (GFR) of less than 60 ml/min/1.73 m² for 3 or more months; LAD: left anterior descending artery; OM: obtuse marginal; PCI: percutaneous coronary intervention; PES: paclitaxel-eluting stents; PDA: posterior descending artery; RCA: right coronary artery; SVG: saphenous vein graft; TIMI: thrombolysis in myocardial infarction
*mean±standard deviation. †PCI was performed at a different institution and no records were available for the type of DES used

Table 2. Perioperative management and perioperative outcomes of the study population.

	Non-cardiac surgery (n=51)	Cardiac surgery (n=16)
Perioperative management		
Duration of bridging with a glycoprotein IIb/IIIa inhibitor (days)*	7.1±0.4	7.8±0.7
Thrombocytopenia, n (%)	0	2 (12.5%)
Glycoprotein IIb/IIIa type, n (%)		
Eptifibatide	49 (96%)	13 (81%)
Tirofiban	2 (4%)	3 (19%)
Duration of clopidogrel interruption (days)*	8.0±0.4	11.8±1.3
Aspirin continued perioperatively, n (%)	33 (65%)	15 (94%)
Interval between surgery and thienopyridine reinitiation (days)*	1.2±0.3	3.2±0.7
Outcomes		
Stent thrombosis proven by coronary angiography, n (%)	2 (3.9%)	0
Probable stent thrombosis, n (%)	0	1 (6%)
Mean blood loss (mL)*	132±56	716±109
Mean decrease in haemoglobin level (gr/dL)*	0.4±0.1	1.7±0.3
Major bleeding using the GUSTO criteria, n (%)	2 (4%)	0
In-hospital mortality, n (%)	2 (4%)	1 (6%)
Mean time to hospital discharge (days)*	2.0±0.3	8.9±0.8

acute stent thrombosis in the immediate postoperative period compared to none in the cardiac surgery group (**Table 2**).

The first patient was a 64-year-old man who had received a sirolimus-eluting stent in the distal right coronary artery to treat restenosis of a bare metal stent 19 months prior to pancreatotomy and splenectomy for pancreatic adenocarcinoma. Both aspirin and clopidogrel were stopped and he received eptifibatide for 19 days until six hours before surgery. The long duration of eptifibatide infusion was required because the patient initially underwent endoscopic-guided pancreatic biopsy that delayed performance of open surgery. Six hours after surgery, he developed inferior ST-segment elevation acute myocardial infarction (STEMI). Emergency coronary angiography revealed thrombosis of the distal right coronary artery stent and this was managed with placement of a bare metal stent (**Figure 1**).

The second patient was a 62-year-old man who had received a zotarolimus-eluting stent in the proximal right coronary artery to treat restenosis of a sirolimus-eluting stent 13 months prior to transurethral prostate resection. The administration of both aspirin and clopidogrel was suspended and he was started on eptifibatide four days prior to surgery. Eptifibatide was discontinued six hours before surgery. Two hours after surgery he developed inferior STEMI. Emergency coronary angiography showed acute thrombosis of the proximal right coronary artery stent that was treated with placement of a bare metal stent (**Figure 2**).

Four patients (7.8%, 95% confidence intervals 2.2% to 18.8%) had bleeding complications (two moderate and two severe according to the GUSTO criteria). Two patients had epistaxis, one before lung

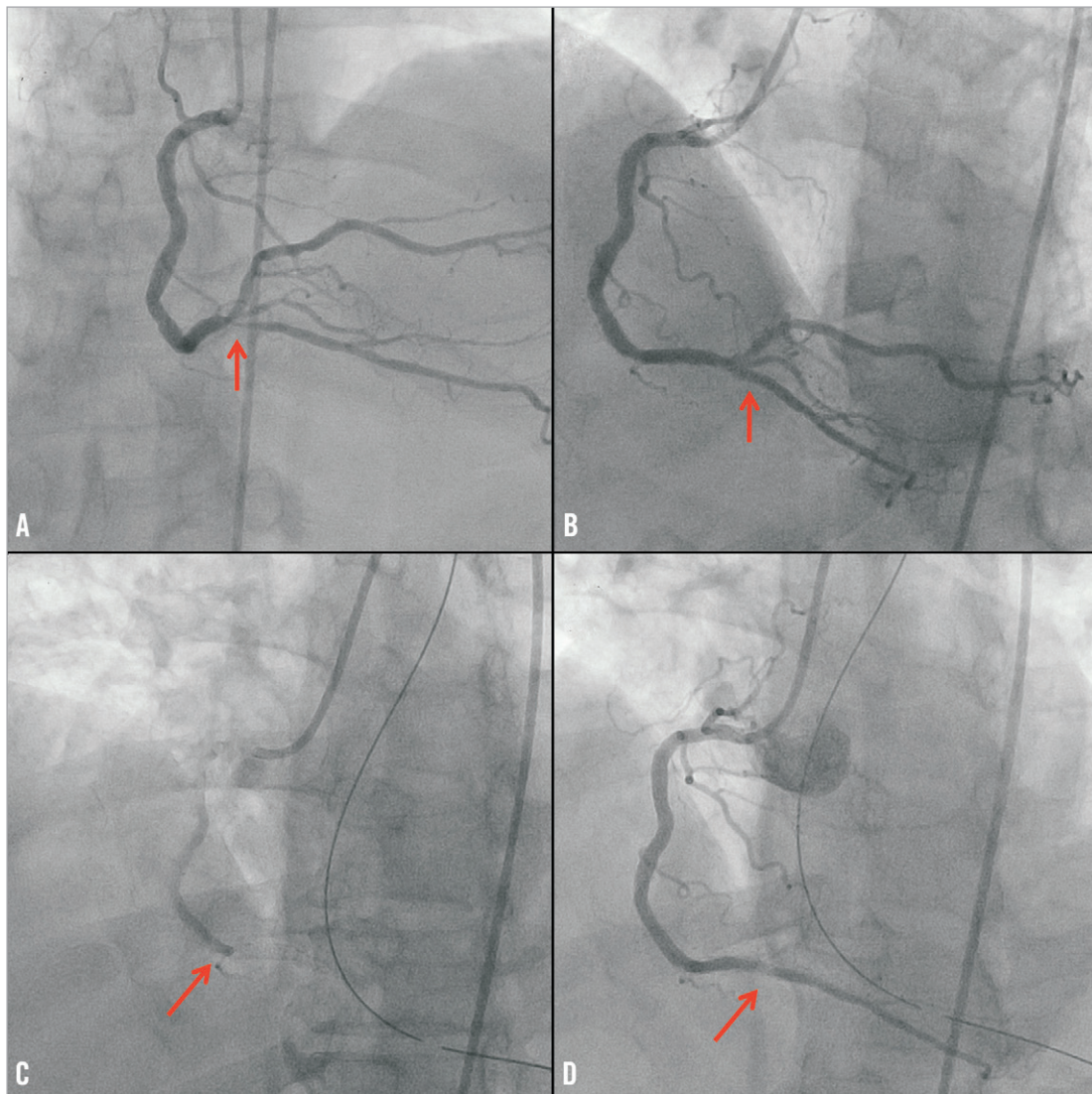


Figure 1. Coronary angiography demonstrating an in-stent restenotic lesion of the distal right coronary artery (arrow, panel A), that was successfully treated with implantation of a sirolimus-eluting stent (arrow, panel B). Acute thrombosis of the distal right coronary artery stent (arrow, panel C), that was successfully treated using a bare metal stent (arrow, panel D).

biopsy (did not require transfusion) and one following nasopharyngeal mass excision (required two units of red blood cells). Epistaxis was successfully treated with cautery in both patients. The third patient had haemoperitoneum following liver biopsy and was treated conservatively with transfusion of three units of red blood cells; he expired after a prolonged hospital course secondary to sepsis. The fourth patient had gastrointestinal bleeding following sigmoidectomy and was treated with transfusion of three units of red blood cells.

PERIOPERATIVE OUTCOMES IN THE CARDIAC SURGERY GROUP

One patient developed STEMI in the postoperative period. He was a 63-year-old man who had undergone sirolimus-eluting stent implantation in the proximal right coronary artery due to non-ST-segment elevation acute myocardial infarction. He underwent CABG and mitral valve repair 24 months after stenting. Aspirin and

clopidogrel were suspended for 17 days preoperatively (he was bridged with eptifibatid for five days but then developed thrombocytopenia and eptifibatid was stopped). He developed inferior STEMI one hour after surgery (although he had received a saphenous vein graft to the right posterior descending artery) that was medically managed (the patient did not undergo coronary angiography because of thrombocytopenia).

A second patient received a drug-eluting stent of unknown type to the mid left circumflex coronary artery after presenting with a STEMI at a different hospital, and was subsequently referred to our institution for CABG due to multivessel disease. Aspirin was continued during the perioperative period. He received eptifibatid for four days prior to surgery and died 12 hours after surgery. Pathology revealed that the patient had extension of his prior myocardial infarction but did not have stent thrombosis.

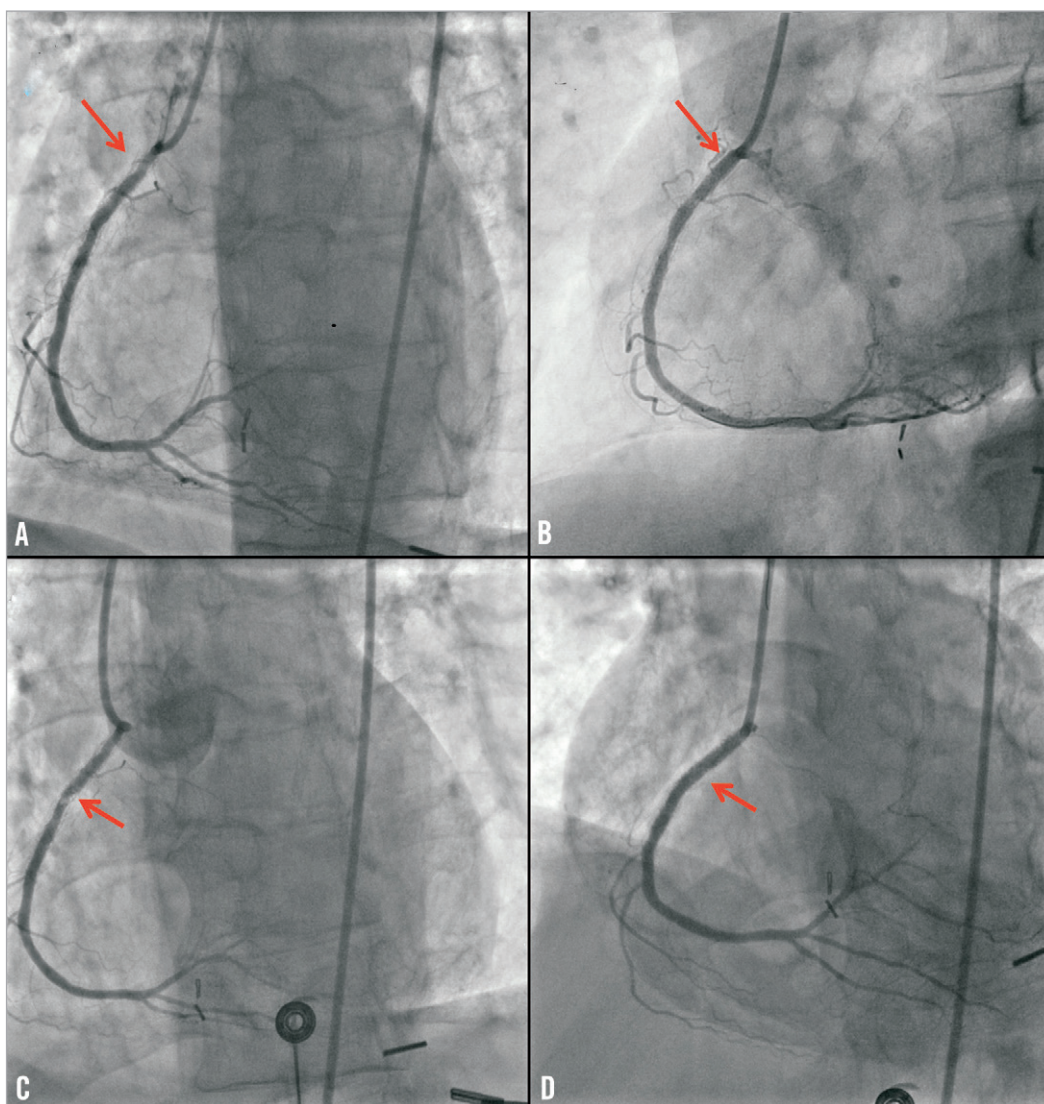


Figure 2. Coronary angiography demonstrating an in-stent restenotic lesion of the proximal right coronary artery (arrow, panel A), that was successfully treated with implantation of a zotarolimus-eluting stent (arrow, panel B). Acute thrombosis of the proximal right coronary artery stent (arrow, panel C), that was successfully treated using a bare metal stent (arrow, panel D).

A third patient developed thrombocytopenia during eptifibatid infusion. Four months prior to surgery he presented with non-ST-segment acute myocardial infarction and underwent unprotected left main stenting with an everolimus-eluting stent. He subsequently developed recurrent non-ST-segment acute myocardial infarction and was referred for CABG. Eptifibatid was started but the patient developed thrombocytopenia. The eptifibatid infusion was stopped and he did not receive any antiplatelet agent for 13 days until surgery, which was uneventful.

A fourth patient had haematuria while on eptifibatid and required transfusion of one unit of red blood cells.

Discussion

The main findings of our study are that, in patients undergoing major surgery after DES implantation requiring interruption of thienopyridine administration, preoperative administration of

a glycoprotein IIb/IIIa inhibitor (a) may not prevent postoperative stent thrombosis, and (b) may be associated with high risk for thrombocytopenia and bleeding.

Patients who undergo DES implantation frequently require subsequent surgery¹⁴⁻²¹. At our institution the incidence of major or minor non-cardiac surgery was 7% at one year, 18% at two years, and 22% at three years post DES implantation³. Although continuation of aspirin and a thienopyridine may minimise the risk for stent thrombosis, thienopyridine discontinuation is frequently requested by the surgeon to prevent severe perioperative bleeding.

In DES patients requiring thienopyridine interruption prior to surgery, a short-acting antiplatelet therapy has been proposed as a bridge to surgery. Eptifibatid and tirofiban have a short half-life and are theoretically attractive for this application. Tirofiban achieves maximal platelet inhibition after five minutes of infusion and platelet

function normalises three to eight hours after discontinuation. Similarly, eptifibatide has a half-life of two to three hours and reverses completely after four hours. No perioperative stent thrombosis occurred in two series of three⁸ and four⁷ DES patients bridged with tirofiban to surgery. In the largest published study to date, 30 patients underwent tirofiban “bridging” before non-cardiac surgery: no patient developed stent thrombosis or other adverse cardiac events during the index hospitalisation¹¹. The Maintenance of platelet inhibition with cangrelor after discontinuation of thienopyridines in patients undergoing surgery (BRIDGE) trial randomised 210 patients with acute coronary syndrome or percutaneous coronary intervention on thienopyridine undergoing CABG to cangrelor or placebo for at least 48 hours and up to seven days. This was discontinued one to six hours prior to CABG (cangrelor was not administered in the postoperative period)²². There was no difference in the incidence of ischaemic or bleeding events during the perioperative period between the two study groups²².

In our study two of 51 patients undergoing non-cardiac surgery after glycoprotein IIb/IIIa administration developed angiographically documented stent thrombosis (**Figure 1** and **Figure 2**). In both cases the stent thrombosis occurred only hours after surgery. Moreover, one patient developed probable stent thrombosis two hours after CABG. In all patients DES implantation had occurred >12 months (13, 19, and 24 months) prior to surgery.

The current guidelines for the perioperative management of patients who need surgery post DES implantation recommend postponing surgery for at least 12 months post stenting, if feasible. The 12-month cut-off is based on expert opinion and on the currently recommended duration for dual antiplatelet therapy post DES implantation, which is based on the duration of therapy used in DES approval clinical trials^{4,5}. Our cases demonstrate that postponing surgery for >12 months post stenting is not necessarily safe, as all stent thrombosis cases in our series occurred with surgery performed >12 months post stenting, in spite of using preoperative glycoprotein IIb/IIIa “bridging”. Patients with prior DES implantation should therefore undergo surgery at centres able to perform primary percutaneous coronary intervention, in order to treat perioperative stent thrombosis promptly, should it occur^{1,23}. Repeat stent implantation should in general be avoided if a good angiographic result can be obtained with balloon angioplasty alone; however, if repeat stenting is needed to treat the thrombosed stent, bare metal stent implantation is preferable to repeat drug-eluting stent implantation to minimise the risk for recurrent stent thrombosis, as was done in two patients in our series.

The three stent thrombosis cases in our series highlight the main limitation of preoperative bridging with any short-acting agent, namely the lack of platelet inhibition postoperatively, when the stent thrombosis risk is highest due to activation of the sympathetic nervous system, the platelets and the coagulation system^{1,3}. Occasionally patient care needs dictate delay of the surgery for >5-7 days from discontinuation of oral antiplatelet therapy, resulting in the need for prolonged glycoprotein IIb/IIIa inhibitor administration, which carries high cost and risk for thrombocytopenia (occurred in 3% of patients in our cohort) and bleeding.

However, a recent report by Rassi et al²⁴ suggested that there was no increased risk of bleeding in patients who underwent eptifibatide bridging before cardiac surgery, utilising bleeding events and transfusion rates without standard bleeding score. Only intravenous short-acting antiplatelet agents are currently available (glycoprotein IIb/IIIa inhibitors), and their administration requires prolonged hospitalisation, is costly and exposes the patients to additional risks, such as nosocomial infections.

Given the limitations of glycoprotein IIb/IIIa administration for prevention of perioperative stent thrombosis, what other strategies are available? Continuation of both aspirin and a thienopyridine (or aspirin alone if dual therapy is not considered safe) during the perioperative period may significantly reduce the risk for stent thrombosis, but may also increase the risk of bleeding. If continuation is decided, clopidogrel should be utilised rather than more potent oral platelet ADP P2Y₁₂ receptor antagonists, such as prasugrel and ticagrelor. Although ticagrelor is shorter-acting than clopidogrel, three to five days are still required for its antiplatelet effect to dissipate; therefore, it would not be a good alternative to clopidogrel and would also be subject to the same limitations of glycoprotein IIb/IIIa administration, i.e., lack of antiplatelet effect during the immediate postoperative period when the stent thrombosis risk is highest. Additional strategies are needed to allow better prediction and treatment of perioperative stent thrombosis. For minor surgical procedures, the risk of bleeding is low and continuing dual antiplatelet therapy is preferred²⁵. However, this is not a good option for high-risk surgical procedures, such as neurosurgery. An ongoing study, the “Bridging Therapy in Patients at High Risk for Stent Thrombosis Undergoing Surgery” (NCT00653601) is evaluating preoperative “bridging” with a glycoprotein IIb/IIIa inhibitor. Small molecule glycoprotein IIb/IIIa inhibitors cannot be administered to patients with severe renal failure or on dialysis; unfractionated heparin could provide some protection against stent thrombosis in such patients, although stent thrombosis is a platelet-mediated event and antiplatelet therapies may be preferable¹. The same considerations apply when low molecular weight heparin is utilised to prevent stent thrombosis²⁶.

Limitations

Our study has several limitations. The most important limitation is that it does not include a control group, hence it cannot address whether preoperative “bridging” with a glycoprotein IIb/IIIa inhibitor can prevent perioperative stent thrombosis compared to a strategy of antiplatelet therapy discontinuation without “bridging”. It included a relatively small number of patients, although it is the largest study of its kind reported to date. As is common among the veteran population, all study patients were men and our results may not be extrapolated to women, although it is unlikely that gender-based differences exist in the risk of perioperative stent thrombosis.

In summary, patients undergoing surgery post DES implantation have a high risk for postoperative stent thrombosis that may occur even after preoperative administration of a glycoprotein IIb/IIIa inhibitor. Novel strategies for predicting, preventing and treating perioperative DES thrombosis are needed.

Funding

Funding was provided by the Department of Veterans Affairs, United States.

Conflict of interest statement

S. Banerjee has received research grants from Gilead and the Medicines Company; has received consultant/speaker honoraria from Covidien and Medtronic; and has ownership in MDCARE Global (spouse) and intellectual property in HygeiaTel. E. Brilakis has received speaker honoraria from St. Jude Medical, Terumo, and Bridgepoint Medical and a research grant from Guerbet; his spouse is an employee of Medtronic. The other authors have no conflicts of interest to declare.

References

1. Brilakis ES, Banerjee S, Berger PB. Perioperative management of patients with coronary stents. *J Am Coll Cardiol.* 2007;49:2145-50.
2. Alshawabkeh LI, Banerjee S, Brilakis ES. Systematic review of the frequency and outcomes of non-cardiac surgery after drug-eluting stent implantation. *Hellenic J Cardiol.* 2011;52:141-8.
3. Gandhi NK, Abdel-Karim AR, Banerjee S, Brilakis ES. Frequency and risk of noncardiac surgery after drug-eluting stent implantation. *Catheter Cardiovasc Interv.* 2011;77:972-6.
4. Grines CL, Bonow RO, Casey DE Jr, Gardner TJ, Lockhart PB, Moliterno DJ, O'Gara P, Whitlow P. Prevention of premature discontinuation of dual antiplatelet therapy in patients with coronary artery stents: a science advisory from the American Heart Association, American College of Cardiology, Society for Cardiovascular Angiography and Interventions, American College of Surgeons, and American Dental Association, with representation from the American College of Physicians. *J Am Coll Cardiol.* 2007;49:734-9.
5. Fleisher LA, Beckman JA, Brown KA, Calkins H, Chaikof E, Fleischmann KE, Freeman WK, Froehlich JB, Kasper EK, Kersten JR, Riegel B, Robb JF, Smith SC Jr, Jacobs AK, Adams CD, Anderson JL, Antman EM, Buller CE, Creager MA, Ettinger SM, Faxon DP, Fuster V, Halperin JL, Hiratzka LF, Hunt SA, Lytle BW, Nishimura R, Ornato JP, Page RL, Riegel B, Tarkington LG, Yancy CW. ACC/AHA 2007 guidelines on perioperative cardiovascular evaluation and care for noncardiac surgery: a report of the American College of Cardiology/American Heart Association Task Force on Practice Guidelines (Writing Committee to Revise the 2002 Guidelines on Perioperative Cardiovascular Evaluation for Noncardiac Surgery) developed in collaboration with the American Society of Echocardiography, American Society of Nuclear Cardiology, Heart Rhythm Society, Society of Cardiovascular Anesthesiologists, Society for Cardiovascular Angiography and Interventions, Society for Vascular Medicine and Biology, and Society for Vascular Surgery. *J Am Coll Cardiol.* 2007;50:e159-241.
6. Layland J, Jellis C, Whitbourn R. Extremely late drug-eluting stent thrombosis: 2037 days after deployment. *Cardiovasc Revasc Med.* 2009;10:55-7.
7. D'Urbano M, Barlocco F, Poli A, Fetiveau R, Vandoni P, Savonitto S, De Servi S. Unplanned surgery after drug eluting stent implantation: a strategy for safe temporary withdrawal of dual oral antiplatelet therapy. *J Cardiovasc Med.* 2008;9:737-41.
8. Broad L, Lee T, Conroy M, Bolsin S, Orford N, Black A, Birdsey G. Successful management of patients with a drug-eluting coronary stent presenting for elective, non-cardiac surgery. *Br J Anaesth.* 2007;98:19-22.
9. Jaffe R, Halon DA, Carmeli J, Lewis BS. Prolonged intravenous eptifibatid infusion for prevention of coronary stent thrombosis. *Int J Cardiol.* 2007;114:409-11.
10. Augoustides JG. Perioperative thrombotic risk of coronary artery stents: possible role for intravenous platelet blockade. *Anesthesiology.* 2007;107:516.
11. Savonitto S, D'Urbano M, Caracciolo M, Barlocco F, Mariani G, Nichelatti M, Klugmann S, De Servi S. Urgent surgery in patients with a recently implanted coronary drug-eluting stent: a phase II study of 'bridging' antiplatelet therapy with tirofiban during temporary withdrawal of clopidogrel. *Br J Anaesth.* 2010;104:285-91.
12. Cutlip DE, Windecker S, Mehran R, Boam A, Cohen DJ, van Es GA, Steg PG, Morel MA, Mauri L, Vranckx P, McFadden E, Lansky A, Hamon M, Krucoff MW, Serruys PW; Academic Research Consortium. Clinical end points in coronary stent trials: a case for standardized definitions. *Circulation.* 2007;115:2344-51.
13. An international randomized trial comparing four thrombolytic strategies for acute myocardial infarction. The GUSTO investigators. *N Engl J Med.* 1993;329:673-82.
14. Applegate RJ, Sacrinty MT, Kutcher MA, Santos RM, Gandhi SK, Little WC. 3-year comparison of drug-eluting versus bare-metal stents. *JACC Cardiovasc Interv.* 2009;2:231-9.
15. Compton PA, Zankar AA, Adesanya AO, Banerjee S, Brilakis ES. Risk of noncardiac surgery after coronary drug-eluting stent implantation. *Am J Cardiol.* 2006;98:1212-3.
16. Schouten O, van Domburg RT, Bax JJ, de Jaegere PJ, Dunkelgrun M, Feringa HH, Hoeks SE, Poldermans D. Noncardiac surgery after coronary stenting: early surgery and interruption of antiplatelet therapy are associated with an increase in major adverse cardiac events. *J Am Coll Cardiol.* 2007;49:122-4.
17. Brotman DJ, Bakhru M, Saber W, Aneja A, Bhatt DL, Tillan-Martinez K, Jaffer AK. Discontinuation of antiplatelet therapy prior to low-risk noncardiac surgery in patients with drug-eluting stents: a retrospective cohort study. *J Hosp Med.* 2007;2:378-84.
18. Kim HL, Park KW, Kwak JJ, Kim YS, Sir JJ, Lee SJ, Lee HY, Chang HJ, Kang HJ, Cho YS, Chung WY, Chae IH, Choi DJ, Kim HS, Oh BH, Park YB, Koo BK. Stent-related cardiac events after non-cardiac surgery: drug-eluting stent vs. bare metal stent. *Int J Cardiol.* 2008;123:353-4.
19. Godet G, Le Manach Y, Lesache F, Perbet S, Coriat P. Drug-eluting stent thrombosis in patients undergoing non-cardiac surgery: is it always a problem? *Br J Anaesth.* 2008;100:472-7.
20. Rhee SJ, Yun KH, Lee SR, Chae JK, Nam CW, Jun DH, Jeong JW. Drug-eluting stent thrombosis during perioperative period. *Int Heart J.* 2008;49:135-42.
21. Rabbitts JA, Nuttall GA, Brown MJ, Hanson AC, Oliver WC, Holmes DR, Rihal CS. Cardiac risk of noncardiac surgery after

percutaneous coronary intervention with drug-eluting stents. *Anesthesiology*. 2008;109:596-604.

22. Angiolillo DJ, Firstenberg MS, Price MJ, Tummala PE, Hutyra M, Welsby IJ, Voeltz MD, Chandna H, Ramaiah C, Brtko M, Cannon L, Dyke C, Liu T, Montalescot G, Manoukian SV, Prats J, Topol EJ; BRIDGE Investigators. Bridging antiplatelet therapy with cangrelor in patients undergoing cardiac surgery: a randomized controlled trial. *JAMA*. 2012;307:265-74.

23. Khair T, Garcia B, Banerjee S, Brilakis ES. Contemporary approaches to perioperative management of coronary stents and to preoperative coronary revascularization: a survey of 374 interventional cardiologists. *Cardiovasc Revasc Med*. 2011;12:99-104.

24. Rassi AN, Blackstone E, Militello MA, Theodos G, Cavender MA, Sun Z, Ellis SG, Cho LI. Safety of “bridging” with eptifibatid for patients with coronary stents before cardiac and non-cardiac surgery. *Am J Cardiol*. 2012;110:485-90.

25. Brilakis ES, Cohen DJ, Kleiman NS, Pencina M, Nassif D, Saucedo J, Piana RN, Banerjee S, Keyes MJ, Yen CH, Berger PB. Incidence and clinical outcome of minor surgery in the year after drug-eluting stent implantation: results from the Evaluation of Drug-Eluting Stents and Ischemic Events Registry. *Am Heart J*. 2011;161:360-6.

26. Daoulah A, Segev A, Leblanc K, Chisholm RJ, Strauss BH. Postprocedural low molecular weight heparin in patients at high risk of subacute stent thrombosis. *Cardiovasc Radiat Med*. 2003;4:182-5.