

Management of two major complications in the cardiac catheterisation laboratory: the no-reflow phenomenon and coronary perforations

Olivier Muller¹, MD PhD; Stephan Windecker², MD; Thomas Cuisset³, MD; Jean Fajadet⁴, MD; Mark Mason⁵, MD; Andrea Zuffi⁶, MD; Alexander Doganov⁷, MD; Eric Eeckhout⁶, MD PhD

1. Cardiovascular Center Aalst, OLV Clinic, Aalst, Belgium; 2. Department of Cardiology, University Hospital Bern, Bern, Switzerland; 3. Department of Cardiology, University Hospital La Timone, Marseille, France; 4. Unité de Cardiologie Interventionnelle, Clinique Pasteur, Toulouse, France; 5. Harefield Hospital, Royal Brompton and Harefield NHS Trust, Middlesex, United Kingdom; 6. Service de Cardiologie, Centre Hospitalier Universitaire Vaudois, Lausanne, Switzerland; 7. National Heart Institute, Sofia, Bulgaria

The authors have no conflict of interest to declare.

The no-reflow phenomenon

The no-reflow phenomenon has been defined in 2001 by Eeckhout and Kern as inadequate myocardial perfusion through a given segment of the coronary circulation without angiographic evidence of mechanical vessel obstruction¹. Rates of cardiac death and non-fatal cardiac events are increased in patients with compared to those without no-reflow^{2,3}. The term “no reflow” encompasses the slow-flow, slow-reflow, no-flow and low-flow phenomenon. Its incidence depends on the clinical setting, ranging from as low as 2% in elective native coronary percutaneous coronary interventions (PCI) to 20% in saphenous venous graft (SVG) PCI and up to 26% in acute myocardial infarction (AMI) mechanical reperfusion⁴⁻⁶. Depending on the clinical setting, the mechanism of the no-reflow phenomenon differs. Distal embolisation and ischaemic-reperfusion cell injury prevail in patients with AMI, microvascular spasm and embolisation of aggregated platelets occur in native coronary PCI, whereas embolisation of degenerated plaque elements, including thrombotic and atherosclerotic debris are encountered during SVG PCI⁷. The no-reflow phenomenon is classified according to its pathophysiology with potential implications for its treatment in the categories provided in Table 1.

Table 1. Classification of the no-reflow phenomenon.

- | |
|------------------------------------|
| 1. Myocardial infarction no-reflow |
| 2. Interventional no-reflow |
| 2a. Native coronary PCI no-reflow |
| 2b. SVG PCI no-reflow |
| 3. Experimental no-reflow |

Diagnosis of no-reflow

The no-reflow phenomenon should be suspected in any situation of impaired TIMI flow. The adequate assessment of no-reflow necessitates to rule out several potential complications that can mimic this phenomenon. First, spasm of the epicardial coronary arteries should be excluded by the administration of i.c. nitroglycerin boluses preferably followed by a sub-selective contrast injection through a microcatheter applying a pull back. This manoeuvre enables to unmask an epicardial coronary dissection and/or other macrovascular obstruction. Although improved epicardial blood flow has been shown to reduce mortality in AMI, TIMI flow 3 does not exclude a no-reflow phenomenon. Continuous chest pain, haemodynamic compromise, new ST-segment changes during elective PCI or lack of ST-segment resolution in the setting of acute myocardial infarction should remind the operator to assess the quality of myocardial perfusion. The myocardial perfusion grade (blush) is the most convenient method to quantify the no-reflow phenomenon in the catheterisation laboratory and represents an independent predictor of mortality⁸. Myocardial contrast echocardiography, contrast enhanced MRI or CT are excellent additional diagnostic tools to investigate myocardial perfusion, although not readily available in the catheterisation laboratory.

Prevention of no-reflow

Due to the adverse impact of the no-reflow phenomenon on prognosis, effort should be performed in order to avoid its appearance. The first step to prevent the no-reflow phenomenon is to identify patients at risk prior to the procedure. Several predictors have been identified and are summarised in Table 2⁷. Moreover, the

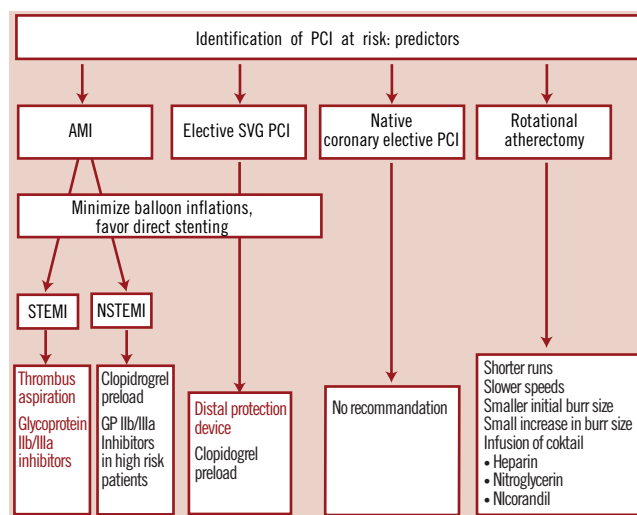
* Corresponding author: Cardiovascular Center Aalst, Moorselbaan, 164 B-9300 Aalst, Belgium

E-mail:olivier.muller@chuv.ch

Table 2. Predictors of no-reflow.

- Duration of preceding myocardial ischaemia
- Infarct size
- Procedural variables
◊ Rotational atherectomy
- Vessels
◊ Saphenous vein grafts
- Lesion characteristics
◊ Plaque size
◊ Eccentric or fissured plaque
- Patient characteristics
◊ Diabetes mellitus
◊ Absence of pre-infarction angina
◊ Advanced age

clinical setting of PCI is of primordial importance since preventive measures may vary. In the setting of a ST-segment elevation AMI, GP IIb/IIIa inhibitors and mechanical thrombus aspiration should be considered in order to prevent no-reflow. Both therapeutic modalities have been shown beneficial in terms of improving TIMI flow as well as clinical outcome^{6,9}. Preventive measure of no-reflow are less well established in patients with non-ST-segment elevation MI. Thus, GP IIb/IIIa inhibitors have shown only a modest impact on surrogate endpoints such as cardiac biomarker elevations¹⁰. Conversely, distal embolisation protection devices have been shown to significantly reduced the rate of no-reflow and improve clinical outcome in the setting of SVG PCI in the SAFER trial¹¹. In the setting of elective native coronary PCI, no universal preventive measure of no-reflow has been identified except for pre-loading with clopidogrel, which may be associated with a reduction in peri-interventional release of cardiac biomarkers. Furthermore, several recipes have been proposed to minimise no-reflow during rotational atherectomy^{12,13} (Figure 1).

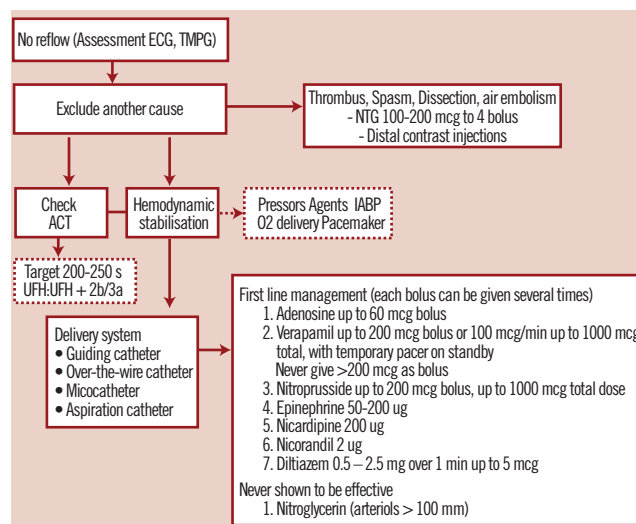
**Figure 1. Algorithm for the prevention of the no-reflow phenomenon.**

Treatment of no-reflow

Once the diagnosis of no-reflow has been established, initial treatment aims to restore a stable haemodynamic status by the use of fluid administration, vasopressor agents, oxygen delivery, and the use of an intra-aortic balloon pump in case of refractory hypotension. In parallel, the status of anticoagulation is assessed by measuring the ACT aiming at a target of >200-250 s. Despite lack of

objective evidence to improve clinical endpoints, vasodilators are widely used owing to their beneficial impact on myocardial perfusion in several studies¹⁴⁻¹⁶.

An algorithm for the treatment of no-reflow is depicted in Figure 2. Per consensus adenosine is considered as a first line drug owing to its strong vasoactive properties, ease of application and short half-life. Notwithstanding, the haemodynamic condition may favour the use of one drug over another. Thus, epinephrine may be preferred in cases of severe hypotension or haemodynamic compromise¹⁷.

**Figure 2. Algorithm for the treatment of no-reflow. The use of a microcatheter should be strongly considered for diagnosis and treatment.**

Introduction of coronary perforations

Coronary perforation is a very rare but feared complication due to the associated morbidity and mortality. The incidence ranges from 0.1% to 3%. Clinical predictors of coronary perforations encompass the elderly, female gender, tortuous, calcified and small arteries¹⁸. Procedural predictors are rotational atherectomy, the use of particular guide wires (stiff & hydrophilic wires), oversized balloons (ratio artery to balloon of >1.2-1.3) and balloon rupture (pin hole effect)¹⁹. Ellis and coworkers²⁰ introduced an angiographic classification of perforation distinguishing four types, a concept largely adopted in clinical practice. Distal perforations related to use of hydrophilic and/or rigid guide wires have not been accommodated in this classification, and we therefore propose to add a fifth type of perforation (type V) (Figure 3).

Treatment of coronary perforations

Management strategies depend on the severity of the perforation (i.e. class I to V). The first aim is to prevent cardiac tamponade, which can be achieved by immediate balloon inflation proximal to the perforation site. Type I perforations are generally without clinical sequelae and seal spontaneously. Type II perforations can usually be managed by balloon inflation and require only rarely additional pericardiocentesis. Repeated balloon inflations lasting up to five to 10 minutes will seal the perforation (using low pressure to promote haemostasis) in the majority of cases. In case of failure, reversal of anticoagulation should be considered and can be achieved by administration of intravenous protamine sulphate,

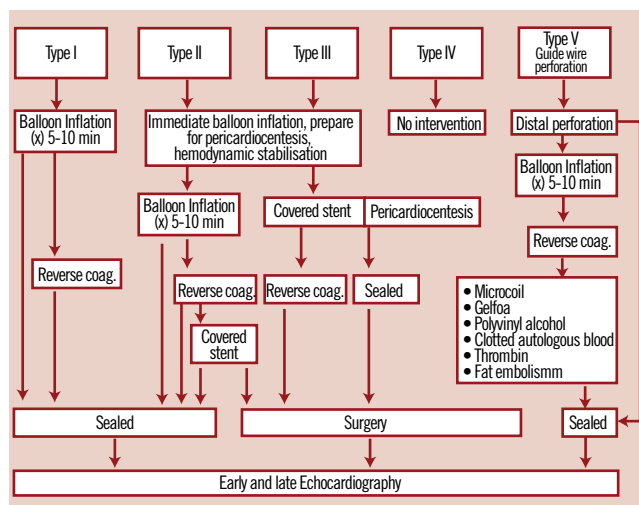


Figure 3. Algorithm for the management of coronary perforation. The traditional Ellis classification has been extended by a type V perforation, encompassing distal coronary perforations.

whereas patients treated with abciximab may require platelet transfusions. Type III perforations usually require emergency pericardiocentesis to prevent haemodynamic compromise. Moreover, the implantation of a covered stent should be immediately attempted whenever technically feasible²¹. Type V coronary perforations are inflicted by distal guidewire manipulation and should be treated first by balloon inflation. Alternatively and particularly in case of persistent leakage, embolisation of the artery may be considered to seal type V perforations. The use of microcoils²², gelfoam²³, clotted autologous blood²⁴, subcutaneous tissue²⁵ as well as polyvinyl alcohol²⁶ and thrombin²⁷ have been described to manage this complication. Once the perforation has been sealed, early echocardiography is advised to establish a baseline followed by late (24 hours) echocardiography in order to capture persistent leaks, which may complicate distal perforations and become clinically relevant only after several hours.

References

- Eckhout E, Kern MJ. The coronary no-reflow phenomenon: a review of mechanisms and therapies. *Eur Heart J*. 2001;22(9):729-739.
- Brosh D, Assali AR, Mager A, Porter A, Hasdai D, Teplitsky I, Rechavia E, Fuchs S, Battler A, Kornowski R. Effect of no-reflow during primary percutaneous coronary intervention for acute myocardial infarction on six-month mortality. *Am J Cardiol*. 2007;99(4):442-445.
- Morishima I, Sone T, Okumura K, Tsuboi H, Kondo J, Mukawa H, Matsui H, Toki Y, Ito T, Hayakawa T. Angiographic no-reflow phenomenon as a predictor of adverse long-term outcome in patients treated with percutaneous transluminal coronary angioplasty for first acute myocardial infarction. *J Am Coll Cardiol*. 2000;36(4):1202-1209.
- Piana RN, Paik GY, Moscucci M, Cohen DJ, Gibson CM, Kugelmass AD, Carrozza JP, Jr., Kuntz RE, Baim DS. Incidence and treatment of 'no-reflow' after percutaneous coronary intervention. *Circulation*. 1994;89(6):2514-2518.
- Resnic FS, Wainstein M, Lee MK, Behrendt D, Wainstein RV, Ohno-Machado L, Kirshenbaum JM, Rogers CD, Popma JJ, Piana R. No-reflow

is an independent predictor of death and myocardial infarction after percutaneous coronary intervention. *Am Heart J*. 2003;145(1):42-46.

6. Svilaas T, Vlaar PJ, van der Horst IC, Diercks GF, de Smet BJ, van den Heuvel AF, Anthonio RL, Jessurun GA, Tan ES, Suurmeijer AJ, Zijlstra F. Thrombus aspiration during primary percutaneous coronary intervention. *N Engl J Med*. 2008;358(6):557-567.

7. Jaffe R, Charron T, Puley G, Dick A, Strauss BH. Microvascular obstruction and the no-reflow phenomenon after percutaneous coronary intervention. *Circulation*. 2008;117(24):3152-3156.

8. Gibson CM, Cannon CP, Murphy SA, Ryan KA, Mesley R, Marble SJ, McCabe CH, Van De Werf F, Braunwald E. Relationship of TIMI myocardial perfusion grade to mortality after administration of thrombolytic drugs. *Circulation*. 2000;101(2):125-130.

9. Montalescot G, Barragan P, Wittenberg O, Ecollan P, Elhadad S, Villain P, Boulenc JM, Morice MC, Maillard L, Pansieri M, Choussat R, Pinton P. Platelet glycoprotein IIb/IIIa inhibition with coronary stenting for acute myocardial infarction. *N Engl J Med*. 2001;344(25):1895-1903.

10. Bassand JP, Hamm CW, Ardissino D, Boersma E, Budaj A, Fernandez-Aviles F, Fox KA, Hasdai D, Ohman EM, Wallentin L, Wijns W. Guidelines for the diagnosis and treatment of non-ST-segment elevation acute coronary syndromes. *Eur Heart J*. 2007;28(13):1598-1660.

11. Baim DS, Wahr D, George B, Leon MB, Greenberg J, Cutlip DE, Kaya U, Popma JJ, Ho KK, Kuntz RE. Randomized trial of a distal embolic protection device during percutaneous intervention of saphenous vein aorto-coronary bypass grafts. *Circulation*. 2002;105(11):1285-1290.

12. Matsuo H, Watanabe S, Watanabe T, Warita S, Kojima T, Hirose T, Iwama M, Ono K, Takahashi H, Segawa T, Minatoguchi S, Fujiwara H. Prevention of no-reflow/slow-flow phenomenon during rotational atherectomy—a prospective randomized study comparing intracoronary continuous infusion of verapamil and nicorandil. *Am Heart J*. 2007;154(5):994-996.

13. Klein LW, Kern MJ, Berger P, Sanborn T, Block P, Babb J, Tommaso C, Hodgson JM, Feldman T. Society of cardiac angiography and interventions: suggested management of the no-reflow phenomenon in the cardiac catheterization laboratory. *Catheter Cardiovasc Interv*. 2003;60(2):194-201.

14. Satler LF. The reversal of no reflow and its effect on clinical outcome. *Catheter Cardiovasc Interv*. 2008;71(3):290.

15. Grayburn PA, Choi JW. Advances in the assessment of no-reflow after successful primary percutaneous coronary intervention for acute ST-segment elevation myocardial infarction: now that we can diagnose it, what do we do about it? *J Am Coll Cardiol*. 2008;51(5):566-568.

16. Ross AM, Gibbons RJ, Stone GW, Kloner RA, Alexander RW. A randomized, double-blinded, placebo-controlled multicenter trial of adenosine as an adjunct to reperfusion in the treatment of acute myocardial infarction (AMISTAD-II). *J Am Coll Cardiol*. 2005;45(11):1775-1780.

17. Baim DS. Epinephrine: a new pharmacologic treatment for no-reflow? *Catheter Cardiovasc Interv*. 2002;57(3):310-311.

18. Gruberg L, Pinnow E, Flood R, Bonnet Y, Tebeica M, Waksman R, Satler LF, Pichard AD, Kent KM, Leon MB, Lindsay J, Jr. Incidence, management, and outcome of coronary artery perforation during percutaneous coronary intervention. *Am J Cardiol*. 2000;86(6):680-682, A688.

19. Witzke CF, Martin-Herrero F, Clarke SC, Pomerantzev E, Palacios IF. The changing pattern of coronary perforation during percutaneous coronary intervention in the new device era. *J Invasive Cardiol*. 2004;16(6):257-301.

20. Ellis SG, Ajluni S, Arnold AZ, Popma JJ, Bittl JA, Eigler NL, Cowley MJ, Raymond RE, Safian RD, Whitlow PL. Increased coronary perforation in the new device era. Incidence, classification, management, and outcome. *Circulation*. 1994;90(6):2725-2730.
21. Briguori C, Nishida T, Anzuini A, Di Mario C, Grube E, Colombo A. Emergency polytetrafluoroethylene-covered stent implantation to treat coronary ruptures. *Circulation*. 2000;102(25):3028-3031.
22. Aslam MS, Messersmith RN, Gilbert J, Lakier JB. Successful management of coronary artery perforation with helical platinum microcoil embolization. *Catheter Cardiovasc Interv*. 2000;51(3):320-322.
23. Dixon SR, Webster MW, Ormiston JA, Wattie WJ, Hammett CJ. Gelfoam embolization of a distal coronary artery guidewire perforation. *Catheter Cardiovasc Interv*. 2000;49(2):214-217.
24. Hadjimiltiades S, Paraskevaides S, Kazinakis G, Louridas G. Coronary vessel perforation during balloon angioplasty: a case report. *Cathet Cardiovasc Diagn*. 1998;45(4):417-420.
25. Oda H, Oda M, Makiyama Y, Kashimura T, Takahashi K, Miida T, Higuma N. Guidewire-induced coronary artery perforation treated with transcatheter delivery of subcutaneous tissue. *Catheter Cardiovasc Interv*. 2005;66(3):369-374.
26. Yoo BS, Yoon J, Lee SH, Kim JY, Lee HH, Ko JY, Lee BK, Hwang SO, Choe KH. Guidewire-induced coronary artery perforation treated with transcatheter injection of polyvinyl alcohol form. *Catheter Cardiovasc Interv*. 2001;52(2):231-234.
27. Fischell TA, Korban EH, Lauer MA. Successful treatment of distal coronary guidewire-induced perforation with balloon catheter delivery of intracoronary thrombin. *Catheter Cardiovasc Interv*. 2003;58(3):370-374.