

IVUS in bifurcation stenting: what have we learned?

Jacek Legutko^{1*}, MD, PhD; Masahiro Yamawaki², MD, PhD; Ricardo A. Costa³, MD, PhD; Marco A. Costa⁴, MD, PhD

1. Institute of Cardiology, Jagiellonian University Medical College, Krakow, Poland; 2. Saiseikai Yokohama City Eastern Hospital, Yokohama, Japan; 3. Instituto Dante Pazzanese de Cardiologia, Sao Paulo, Brazil; 4. Center for Research and Innovation, UH Harrington Heart and Vascular Institute, Case Western Reserve University, Cleveland, OH, USA

The references can be found in the online version of this paper at the following website: http://www.pcronline.com/eurointervention/V_issue/12

KEYWORDS

- coronary bifurcation lesions
- imaging
- intravascular ultrasound
- left main coronary artery
- stents

Abstract

Coronary angiography is unable to visualise the atherosclerotic involvement of the arterial wall. Bifurcation lesions are particularly difficult to assess by angiography because overlapping mother and daughter vessels often obscure the lesion and carina. On the contrary, IVUS imaging allows for precise, real-time, cross-sectional assessment of all bifurcation lesion segments, enabling measurements of luminal and vessel areas. Moreover, IVUS evaluation of stent expansion, apposition and edge problems is also superior to angiographic assessment. In spite of the lack of adequately powered randomised trials, there is growing evidence from large registries and meta-analyses showing better acute and long-term outcomes of DES implantation guided by IVUS, in comparison to angiography-guided procedures. In this review, we summarise current scientific evidence, the European Society of Cardiology recommendations and the European Bifurcation Club consensus for the use of IVUS in bifurcation stenting.

*Corresponding author: Institute of Cardiology, 2nd Department of Cardiology, Jagiellonian University Medical College, 17, Kopernika St, 31-501 Krakow, Poland. E-mail: jacek.legutko@uj.edu.pl

Introduction

Determining anatomic configuration, selecting strategy and assessing the final result are the key factors in bifurcation lesion treatment that may have a significant impact on both acute and long-term outcomes¹. In the bare metal stent (BMS) era, intravascular ultrasound (IVUS)-guided PCI was mainly associated with a lower risk of target vessel revascularisation (TVR). In the drug-eluting stent (DES) era, however, there is growing evidence for the reduction of death, stent thrombosis (ST), myocardial infarction (MI) and TVR by IVUS-guided DES implantation. The 2014 ESC/EACTS Guidelines on myocardial revascularisation recommend the use of IVUS: 1) in selected patients to optimise stent implantation, 2) to assess severity and optimise treatment of unprotected left main lesions, and 3) to assess mechanisms of stent failure².

Pre-procedural IVUS assessment of the bifurcation lesion

Pre-procedural IVUS imaging of the bifurcation lesion allows for precise: 1) measurement of a true lumen and vessel (external elastic membrane [EEM]) dimensions in the mother and daughter vessel, 2) analysis of atherosclerotic plaque burden (PB), morphology and longitudinal distribution, 3) stent landing zone and reference analysis, 4) stenosis severity and negative remodelling assessment (mainly at ostial location), 5) measurement of the lesion length (only during automatic pullback), and 6) detection of angiographically silent disease (LM stenosis, diffuse disease in reference segments).

Plaque distribution

A study which analysed LM bifurcation reported that plaques were continuously distributed from the left anterior descending artery (LAD) to the LM, and the carina was always spared³. In addition, studies which used greyscale or virtual histology IVUS reported plaque accumulation and vulnerability more frequently in the proximal main vessel (MV) than in the distal MV^{4,5}. These anatomic characteristics of coronary bifurcation appear to suggest that: 1) plaque rupture is more likely to occur in the proximal MV than in the other segments, 2) overinflating the hugging balloon during final kissing inflation (FKI) carries a risk of inducing longitudinal plaque redistribution (shift) and a risk of inducing distal embolism and no/slow flow, especially in an acute coronary syndrome, and 3) stent edge restenosis most likely occurs due to PB in the proximal stent landing zone. In the CROSS trial, angiographic restenosis was frequently observed eight months after PCI at the proximal stent edge in one stent strategy (FKI vs. non-FKI: 5.7% vs. 0.9%, $p=0.06$) (European Bifurcation Club 2014, unpublished data). In the previous study of IVUS for non-bifurcated lesions, a PB <50% was recommended as the appropriate landing zone to reduce stent edge restenosis after DES implantation⁶. Although no evidence is available regarding the MV-PB to avoid edge restenosis in coronary bifurcation, plaque observation on IVUS in the proximal MV provides us with valuable information before the procedure.

How to anticipate side branch compromise

Side branch (SB) ostial stenosis can be aggravated after crossover stent deployment in the MV. A recently published IVUS study which directly observed the jailed SB ostium reported that the main mechanism for the SB compromise was carina shift, and that pre-procedural PB and luminal expansion after stenting of the distal MV were associated with the carina shift⁷. In addition, a sub-analysis of the J-REVERSE registry revealed that negative remodelling in the distal MV was a predictor of SB residual stenosis after FKI (European Bifurcation Club 2014, unpublished data). These findings demonstrate that carina shift is enhanced by stretching of the distal MV and a shift in the flow divider outward towards the SB ostium. Therefore, selection of an appropriately sized stent (according to the precise lumen diameter at the MV reference and at the negative remodelling carina site) via pre-procedural IVUS is an important technical step for avoiding unnecessary SB occlusion after MV stenting. Subsequent proximal optimisation technique (POT) can correct any proximal stent malapposition that is due to the luminal discrepancy between the proximal and distal MV.

Plaque accumulation at the SB ostium can also be detected via pre-procedural IVUS, and this can predict SB occlusion or compromise that may induce physiological myocardial ischaemia^{8,9}. In the provisional SB approach after MV stenting, SB intervention (pre-dilatation or FKI) might be needed if plaque accumulation is found in the SB. Unfortunately, IVUS assessment of the SB ostium from the MV is not precise, and direct imaging is needed for an accurate evaluation of the SB ostium¹⁰.

Interestingly, previous greyscale IVUS studies with pullback from the SB demonstrated that negative remodelling is frequently encountered at the SB ostial location, even in SB with extensive and severe disease. Therefore, it may play a substantial role in lumen compromise as assessed by the angiographic “luminogram”¹¹. In general, negative remodelling is not associated with functional ischaemia, and such observation with IVUS may be helpful in decision making before approaching bifurcation PCI with more complex techniques.

With respect to the LM lesion, a pre-procedural minimal lumen area of <3.7 mm² and PB >56% at the left circumflex (LCX) ostium predicted a post-stenting FFR <0.80 after LM bifurcation stenting with the crossover technique¹². In LM bifurcation lesions with mild LCX ostial disease, the use of a single-stent technique rarely resulted in functional LCX compromise¹³.

Cut-off for minimum lumen area to predict myocardial ischaemia in LM bifurcation

Appropriate decision making for revascularisation in LM disease is a clinically important issue, as it can help avoid unnecessary stenting or surgery in patients with non-significant stenosis and under-treatment of patients with significant LM disease ambiguous by angiography. Fractional flow reserve (FFR) is the gold standard for identifying myocardial ischaemia (FFR ≤0.75-0.80) in the cath-lab¹⁴. To predict myocardial ischaemia in LM disease, the cut-off value for the IVUS-derived minimum lumen cross-sectional area

(IVUS-MLA) has been recognised as 4.5-6.0 mm² 15-17. The IVUS-MLA in LM seems to be population-dependent. The average IVUS-MLA in the patients included in two different studies was strikingly different (7.6 mm² in the US study and 4.8 mm² in the Korean study)¹⁸. Another recent study compared coronary LM lesions among 99 white North American and 99 Asian patients. Again, Asian patients had a significantly smaller LM-MLA (5.2±1.8 vs. 6.2±1.4 mm²; p<0.0001)¹⁹.

In a prospective multicentre LITRO study, investigators evaluated the safety of an IVUS-MLA threshold of 6 mm² to guide decision making on revascularisation in 354 patients with LM disease. In 179 patients with an LM segment IVUS-MLA of ≥6 mm² revascularisation was deferred, whereas the remaining 152 patients with an IVUS-MLA <6 mm² were revascularised. Importantly, the two-year event-free survival from cardiac death and MI was 97.7% in those patients who had no LM revascularisation, compared with 94.5% in the revascularised group (p=0.5)¹⁵. IVUS is potentially limited to identifying functional ischaemia (via the lumen area), as ischaemia also depends on myocardial territory, lesion length, collateral supply, and microvascular injury in the distal myocardium. Thus, McDaniel et al proposed that LM patients with an IVUS-MLA of <6 mm² should be evaluated via FFR or non-invasive testing, whereas an IVUS-MLA of ≥6 mm² should indicate deferred revascularisation¹⁴.

IVUS assessment of bifurcation during the procedure

Intravascular ultrasound imaging during the procedure allows for precise: 1) direct control of wire re-crossing through the jailed SB, 2) assessment and optimisation of stent apposition (stent strut adherence to the vessel wall), 3) measurement and optimisation of stent expansion (ratio between minimum stent area and lumen area in adjacent reference segment of the vessel), 4) assessment of full lesion coverage by the stent (especially at the SB ostial location when using some double-stenting techniques such as T-stenting), and 5) diagnosis and treatment of stent edge problems (geographic miss, secondary lesions, large plaque burden, dissection, etc.).

During the provisional SB approach for coronary bifurcation, coronary wire re-crossing through the jailed SB (at an appropriate point near to the carina) is an important step to perform FKI, as it can provide optimal SB scaffolding without stent malapposition at the carina²⁰. For this purpose, IVUS can manually and repeatedly track the SB wire between the SB and proximal MV, and proximal stent malapposition can be detected immediately after the MV stenting (**Figure 1**). This phenomenon is rarely associated with wire twisting outside of the strut when re-wiring is performed.

When a single-stent strategy is used, wiring of the jailed SB with imaging wires should be avoided due to the risk of distorting the stent. On the contrary, pullbacks in both SB and MV are recommended in evaluation of two-stent techniques if intracoronary imaging is used²¹.

Definitive guidelines for IVUS-guided stent optimisation are not available, and it is still performed at the operator's discretion. Small

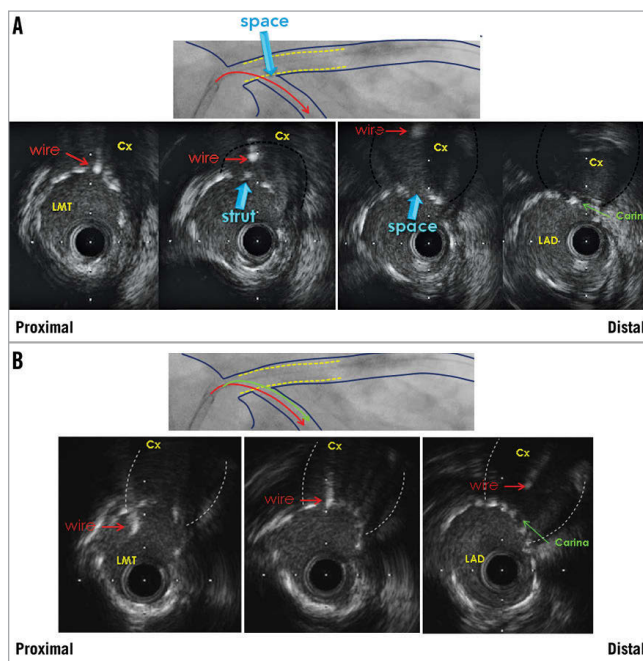


Figure 1. IVUS-guided left main (LMT) PCI with provisional side branch stenting. Wire re-crossing through the jailed left circumflex coronary artery (Cx) before final kissing inflation. A) Wire position is too proximal. B) Optimal wire position near carina. LAD: left anterior descending coronary artery

(<5.0-5.5 mm²) IVUS-derived minimum stent area (IVUS-MSA) or stent underexpansion and edge problems are the most important IVUS predictors of DES thrombosis and restenosis^{22,23}. Non-compliant (NC) balloon post-dilatation with a maximum balloon to EEM diameter ratio 0.9-1.0 and inflation pressure >16 atm is encouraged to achieve complete stent strut apposition to the vessel wall and IVUS-MSA >5.0-5.5 mm² or IVUS-MSA >90-100% of the lumen area at the adjacent reference segment^{24,25}. In LM lesions, optimal IVUS-MSA to prevent TVR was reported to be >8.7 mm² 26. Kang et al evaluated IVUS predictors of in-stent restenosis (ISR) after LM bifurcation stenting. Post-stenting IVUS-MSA cut-offs that best predicted ISR on a segmental basis were 5.0 mm² (ostial left circumflex [LCX] ISR), 6.3 mm² (ostial left anterior descending [LAD] ISR), 7.2 mm² (ISR within polygon of confluence [POC, confluence zone of LAD and LCX]), and 8.2 mm² (ISR within the LM above the POC) (**Figure 2**). A smaller IVUS-MSA within any one of these segments was responsible for a higher rate of angiographic ISR and clinical major adverse cardiovascular events (MACE)²⁷. Thus, correcting underexpansion with these optimal IVUS criteria may reduce cardiac events after DES treatment for unprotected LM disease.

Edge dissection, which is complicated by lumen narrowing <4.0 mm² or dissection angle ≥60° has been associated with an increased incidence of acute stent thrombosis²³. Thus, additional stent implantation should be considered in such situations to lower the risk of stent thrombosis.

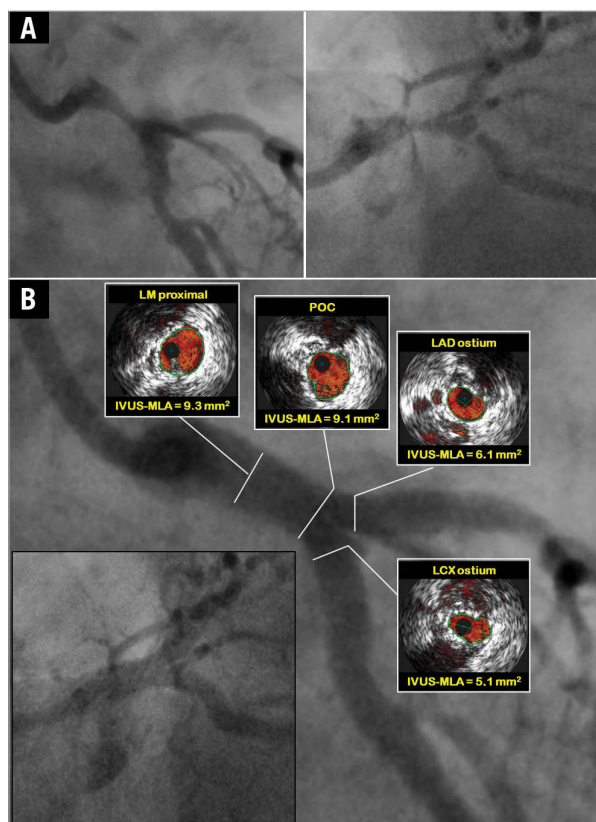


Figure 2. IVUS-guided left main (LM) PCI with DK crush technique. A) Baseline angiography. B) Final IVUS assessment of the mother and daughter vessel confirmed optimal stent apposition and expansion with minimum lumen areas (IVUS-MLA) above optimal cut-offs in all segments of LM bifurcation²⁷. LAD: left anterior descending coronary artery; LCX: left circumflex coronary artery; POC: polygon of confluence

Clinical outcome of IVUS-guided bifurcation PCI

NON-LM BIFURCATION STENTING

The long-term effect of IVUS-guided non-LM bifurcation stenting was assessed for the first time by Kim SH et al. In patients receiving DES, but not BMS, IVUS-guided bifurcation stenting significantly reduced four-year mortality compared to conventional angiographically guided stenting. In addition, IVUS guidance reduced the development of very late ST in patients receiving DES²⁸. Kim JS et al evaluated 1,668 patients with non-LM bifurcation lesions who underwent DES implantation with or without IVUS guidance. The two-stent technique and FKI were more frequently performed in the IVUS-guided group. Maximal stent diameters at both the MV and the SB were larger in the IVUS-guided group. Periprocedural creatine kinase-MB elevation (>3 times upper normal limits) was more frequently observed in the angiography-guided group. The incidence of death or MI was significantly lower in the IVUS-guided group compared to the angiography-guided group (3.8% vs. 7.8%; $p=0.04$)²⁹. Chen SL et al analysed the difference in one-year outcomes following two-stent techniques involving implantation of DES for coronary bifurcation lesions between IVUS-guided and

angiography-guided groups. The late ST at 12-month follow-up was 0% in the IVUS-guided group versus 4.9% in the angiography-guided group ($p=0.029$), resulting in significant differences in ST-elevation MI between the two groups (2.4% vs. 9.8%; $p=0.030$)³⁰.

LEFT MAIN BIFURCATION STENTING

In the MAIN-COMPARE registry, there was a tendency of lower risk of three-year mortality with IVUS guidance compared to angiography guidance (6.0% vs. 13.6%, $p=0.061$). In particular, in patients receiving DES, the three-year incidence of mortality was lower with IVUS guidance as compared to angiography guidance (4.7% vs. 16.0%; $p=0.055$). In contrast, the use of IVUS guidance did not reduce the risk of mortality of patients receiving BMS²⁶. However, data regarding total mortality favouring IVUS guidance are difficult to interpret in the absence of comparative data on cardiac mortality and stent thrombosis. In a recently published study, de la Torre Hernandez et al evaluated the clinical impact of IVUS guidance on DES implantation for unprotected LM disease based on patient-level pooled analysis of four registries³¹. Survival free of cardiac death, myocardial infarction, and target lesion revascularisation at three years was 88.7% in the IVUS group and 83.6% in the no-IVUS group ($p=0.04$) for the overall population, 90% and 80.7%, respectively ($p=0.03$), for the subgroup with distal LM lesions, and 83.3% and 59%, respectively ($p=0.02$), for the distal LM subgroup treated with two stents. The incidence of definite and probable ST was significantly lower in the IVUS group (0.6% vs. 2.2%; $p=0.04$). Finally, IVUS-guided revascularisation was identified as an independent predictor of major adverse events in the overall population (hazard ratio: 0.70, 95% CI: 0.52 to 0.99; $p=0.04$), and to a greater extent in the subgroup with distal lesions (hazard ratio: 0.54, 95% CI: 0.34 to 0.90; $p=0.02$).

META-ANALYSIS OF IVUS-GUIDED PCI

Notable limitations of all of the above-mentioned studies were the lack of randomisation and lack of pre-specified guidelines for stent optimisation by IVUS. Moreover, the sample size of those studies was not large enough to evaluate precisely the low incidence of MACE at follow-up. A recently published comprehensive meta-analysis evaluated the clinical impact of IVUS-guided PCI with DES compared with conventional angiography-guided PCI. This meta-analysis included 26,503 patients from three randomised and 14 observational studies (including two studies dedicated to LM stenosis and three studies dedicated to bifurcation stenosis). Intravascular ultrasound-guided PCI was significantly associated with more, longer and larger stents. Regarding clinical outcomes, IVUS-guided PCI was associated with a significantly lower risk of death, MI, ST and TLR³².

Conflict of interest statement

The authors have no conflicts of interest to declare.

References

The references can be found in the online version of the paper.

Online data supplement

References

1. Trabattoni D, Bartorelli AL. IVUS in bifurcation stenting: what have we learned? *EuroIntervention*. 2010;6 Suppl J:J88-93.
2. Windecker S, Kolh P, Alfonso F, Collet JP, Cremer J, Falk V, Filippatos G, Hamm C, Head SJ, Juni P, Kappetein AP, Kastrati A, Knuuti J, Landmesser U, Laufer G, Neumann FJ, Richter DJ, Schauerte P, Sousa Uva M, Stefanini GG, Taggart DP, Torracca L, Valgimigli M, Wijns W, Witkowski A. 2014 ESC/EACTS Guidelines on myocardial revascularization. *EuroIntervention*. 2015;10:1024-94.
3. Oviedo C, Maehara A, Mintz GS, Araki H, Choi SY, Tsujita K, Kubo T, Doi H, Templin B, Lansky AJ, Dangas G, Leon MB, Mehran R, Tahk SJ, Stone GW, Ochiai M, Moses JW. Intravascular ultrasound classification of plaque distribution in left main coronary artery bifurcations: where is the plaque really located? *Circ Cardiovasc Interv*. 2010;3:105-12.
4. Gonzalo N, Garcia-Garcia HM, Regar E, Barlis P, Wentzel J, Onuma Y, Ligthart J, Serruys PW. In vivo assessment of high-risk coronary plaques at bifurcations with combined intravascular ultrasound and optical coherence tomography. *JACC Cardiovasc Imaging*. 2009;2:473-82.
5. Badak O, Schoenhagen P, Tsunoda T, Magyar WA, Coughlin J, Kapadia S, Nissen SE, Tuzcu EM. Characteristics of atherosclerotic plaque distribution in coronary artery bifurcations: an intravascular ultrasound analysis. *Coron Artery Dis*. 2003;14:309-16.
6. Morino Y, Tamiya S, Masuda N, Kawamura Y, Nagaoka M, Matsukage T, Ogata N, Nakazawa G, Tanabe T, Ikari Y. Intravascular ultrasound criteria for determination of optimal longitudinal positioning of sirolimus-eluting stents. *Circ J*. 2010;74: 1609-16.
7. Xu J, Hahn JY, Song YB, Choi SH, Choi JH, Lu C, Lee SH, Hong KP, Park JE, Gwon HC. Carina shift versus plaque shift for aggravation of side branch ostial stenosis in bifurcation lesions: volumetric intravascular ultrasound analysis of both branches. *Circ Cardiovasc Interv*. 2012;5:657-62.
8. Kang SJ, Mintz GS, Kim WJ, Lee JY, Park DW, Lee SW, Kim YH, Lee CW, Park SW, Park SJ. Preintervention angiographic and intravascular ultrasound predictors for side branch compromise after a single-stent crossover technique. *Am J Cardiol*. 2011;107: 1787-93.
9. Furukawa E, Hibi K, Kosuge M, Nakatogawa T, Toda N, Takamura T, Tsukahara K, Okuda J, Ootsuka F, Tahara Y, Sugano T, Endo T, Kimura K, Umemura S. Intravascular ultrasound predictors of side branch occlusion in bifurcation lesions after percutaneous coronary intervention. *Circ J*. 2005;69:325-30.
10. Oviedo C, Maehara A, Mintz GS, Tsujita K, Kubo T, Doi H, Castellanos C, Lansky AJ, Mehran R, Dangas G, Leon MB, Stone GW, Templin B, Araki H, Ochiai M, Moses JW. Is accurate intravascular ultrasound evaluation of the left circumflex ostium from a left anterior descending to left main pullback possible? *Am J Cardiol*. 2010;105:948-54.
11. Costa RA, Feres F, Staico R, Abizaid A, Costa JR Jr, Siqueira D, Tanajura LF, Damiani LP, Sousa A, Sousa JE, Colombo A. Vessel remodeling and plaque distribution in side branch of complex coronary bifurcation lesions: a grayscale intravascular ultrasound study. *Int J Cardiovasc Imaging*. 2013;29: 1657-66.
12. Kang SJ, Ahn JM, Kim WJ, Lee JY, Park DW, Lee SW, Kim YH, Lee CW, Park SW, Park SJ. Functional and morphological assessment of side branch after left main coronary artery bifurcation stenting with cross-over technique. *Catheter Cardiovasc Interv*. 2014;83:545-52.
13. Kang SJ, Mintz GS, Kim WJ, Oh JH, Park DW, Lee SW, Kim YH, Lee CW, Park SW, Park SJ. Changes in left main bifurcation geometry after a single-stent crossover technique: an intravascular ultrasound study using direct imaging of both the left anterior descending and the left circumflex coronary arteries before and after intervention. *Circ Cardiovasc Interv*. 2011;4:355-61.
14. McDaniel MC, Eshthardi P, Sawaya FJ, Douglas JS Jr, Samady H. Contemporary clinical applications of coronary intravascular ultrasound. *JACC Cardiovasc Interv*. 2011;4:1155-67.
15. de la Torre Hernandez JM, Hernandez Hernandez F, Alfonso F, Rumoroso JR, Lopez-Palop R, Sadaba M, Carrillo P, Rondan J, Lozano I, Ruiz Nodar JM, Baz JA, Fernandez Nofrerias E, Pajin F, Garcia Camarero T, Gutierrez H; LITRO Study Group (Spanish Working Group on Interventional Cardiology). Prospective application of pre-defined intravascular ultrasound criteria for assessment of intermediate left main coronary artery lesions results from the multicenter LITRO study. *J Am Coll Cardiol*. 2011;58:351-8.
16. Jasti V, Ivan E, Yalamanchili V, Wongpraparut N, Leesar MA. Correlations between fractional flow reserve and intravascular ultrasound in patients with an ambiguous left main coronary artery stenosis. *Circulation*. 2004;110:2831-6.
17. Stankovic G, Darremont O, Ferenc M, Hildick-Smith D, Louvard Y, Albiero R, Pan M, Lassen JF, Lefevre T; European Bifurcation Club. Percutaneous coronary intervention for bifurcation lesions: 2008 consensus document from the fourth meeting of the European Bifurcation Club. *EuroIntervention*. 2009;5:39-49.
18. de la Torre Hernandez JM, Hernandez F, Alfonso F. The optimal cutoff value for left main minimal lumen area of 4.5 mm(2): a word of caution. *JACC Cardiovasc Interv*. 2015;8:122-3.
19. Rusinova RP, Mintz GS, Choi SY, Araki H, Hakim D, Sanidas E, Yakushiji T, Weisz G, Mehran R, Franklin-Bond T, Fahy M, Leon MB, Stone GW, Moses JW, Tahk SJ, Ochiai M, Maehara A. Intravascular ultrasound comparison of left main coronary artery disease between white and Asian patients. *Am J Cardiol*. 2013;111:979-84.
20. Sgueglia GA, Chevalier B. Kissing balloon inflation in percutaneous coronary interventions. *JACC Cardiovasc Interv*. 2012;5: 803-11.

21. Lassen JF, Holm NR, Stankovic G, Lefèvre T, Chieffo A, Hildick-Smith D, Pan M, Darremont O, Albiero R, Ferenc M, Louvard Y. Percutaneous coronary intervention for coronary bifurcation disease: consensus from the first 10 years of the European Bifurcation Club meetings. *EuroIntervention*. 2014;10:545-60.
22. Hong MK, Mintz GS, Lee CW, Park DW, Choi BR, Park KH, Kim YH, Cheong SS, Song JW, Kim JJ, Park SW, Park SJ. Intravascular ultrasound predictors of angiographic restenosis after sirolimus-eluting stent implantation. *Eur Heart J*. 2006;27:1305-10.
23. Choi SY, Witzenbichler B, Maehara A, Lansky AJ, Guagliumi G, Brodie B, Kellett MA Jr, Dressler O, Parise H, Mehran R, Dangas GD, Mintz GS, Stone GW. Intravascular ultrasound findings of early stent thrombosis after primary percutaneous intervention in acute myocardial infarction: a Harmonizing Outcomes with Revascularization and Stents in Acute Myocardial Infarction (HORIZONS-AMI) substudy. *Circ Cardiovasc Interv*. 2011;4:239-47.
24. Chen SL, Ye F, Zhang JJ, Tian NL, Liu ZZ, Santoso T, Zhou YJ, Jiang TM, Wen SY, Kwan TW. Intravascular ultrasound-guided systematic two-stent techniques for coronary bifurcation lesions and reduced late stent thrombosis. *Catheter Cardiovasc Interv*. 2013;81:456-63.
25. de Jaegere P, Mudra H, Figulla H, Almagor Y, Doucet S, Penn I, Colombo A, Hamm C, Bartorelli A, Rothman M, Nobuyoshi M, Yamaguchi T, Voudris V, DiMario C, Makovski S, Hausmann D, Rowe S, Rabinovich S, Sunamura M, van Es GA. Intravascular ultrasound-guided optimized stent deployment. Immediate and 6 months clinical and angiographic results from the Multicenter Ultrasound Stenting in Coronaries Study (MUSIC Study). *Eur Heart J*. 1998;19:1214-23.
26. Park SJ, Kim YH, Park DW, Lee SW, Kim WJ, Suh J, Yun SC, Lee CW, Hong MK, Lee JH, Park SW; MAIN-COMPARE Investigators. Impact of intravascular ultrasound guidance on long-term mortality in stenting for unprotected left main coronary artery stenosis. *Circ Cardiovasc Interv*. 2009;3:167-77.
27. Kang SJ, Ahn JM, Song H, Kim WJ, Lee JY, Park DW, Yun SC, Lee SW, Kim YH, Lee CW, Mintz GS, Park SW, Park SJ. Comprehensive intravascular ultrasound assessment of stent area and its impact on restenosis and adverse cardiac events in 403 patients with unprotected left main disease. *Circ Cardiovasc Interv*. 2011;4:562-9.
28. Kim SH, Kim YH, Kang SJ, Park DW, Lee SW, Lee CW, Hong MK, Cheong SS, Kim JJ, Park SW, Park SJ. Long-term outcomes of intravascular ultrasound-guided stenting in coronary bifurcation lesions. *Am J Cardiol*. 2010;106:612-8.
29. Kim JS, Hong MK, Ko YG, Choi D, Yoon JH, Choi SH, Hahn JY, Gwon HC, Jeong MH, Kim HS, Seong IW, Yang JY, Rha SW, Tahk SJ, Seung KB, Park SJ, Jang Y. Impact of intravascular ultrasound guidance on long-term clinical outcomes in patients treated with drug-eluting stent for bifurcation lesions: data from a Korean multicenter bifurcation registry. *Am Heart J*. 2011;161:180-7.
30. Chen SL, Ye F, Zhang JJ, Tian NL, Liu ZZ, Santoso T, Zhou YJ, Jiang TM, Wen SY, Kwan TW. Intravascular ultrasound-guided systematic two-stent techniques for coronary bifurcation lesions and reduced late stent thrombosis. *Catheter Cardiovasc Interv*. 2013;81:456-63.
31. de la Torre Hernandez JM, Baz JA, Gómez Hospital JA, Alfonso Manterola F, Garcia Camarero T, Gimeno de Carlos F, Roura Ferrer G, Recalde AS, Martínez-Luengas IL, Gomez Lara J, Hernandez Hernandez F, Pérez-Vizcayno MJ, Cequier Fillat A, Perez de Prado A, Gonzalez-Trevilla AA, Jimenez Navarro MF, Mauri Ferre J, Fernandez Diaz JA, Pinar Bermudez E, Zueco Gil J; IVUS-TRONCO-ICP Spanish study. Clinical impact of intravascular ultrasound guidance in drug-eluting stent implantation for unprotected left main coronary disease: patient level pooled analysis of 4 registries. *JACC Cardiovasc Interv*. 2014;7:244-54.
32. Ahn JM, Kang SJ, Yoon SH, Park HW, Kang SM, Lee JY, Lee SW, Kim YH, Lee CW, Park SW, Mintz GS, Park SJ. Meta-analysis of outcomes after intravascular ultrasound-guided versus angiography-guided drug-eluting stent implantation in 26,503 patients enrolled in three randomized trials and 14 observational studies. *Am J Cardiol*. 2014;113:1338-47.