

# Double atrial septum or redundant Eustachian valve: procedural management during atrial septal defect occlusion

Xavier Freixa<sup>1\*</sup>, MD; Ander Regueiro<sup>1</sup>, MD; Gustavo Neves de Araujo<sup>1</sup>, MD; Nelson Leal<sup>2</sup>, MD; Manel Sabaté<sup>1</sup>, MD, PhD

1. Cardiology Department, Thorax Institute, Hospital Clínic, IDIBAPS, University of Barcelona, Barcelona, Spain; 2. Cardiology Department, Hospital General de Catalunya, Barcelona, Spain

The presence of a redundant Eustachian valve (EV) might be difficult to distinguish from a double atrial septum (DAS)<sup>1</sup>. The EV is generally anterior, whereas a DAS tends to be located posterior and to the left of the inferior vena cava<sup>2</sup>. We describe the percutaneous closure of an atrial septal defect (ASD) in a patient in whom intraprocedural transoesophageal echocardiography (TEE) showed a possible DAS not detected on previous TEE. Since the operators were not sure if the image corresponded to a redundant EV or a DAS, a pigtail catheter was advanced into the right ventricle (RV). The pigtail deflected the prominent tissue, confirming the diagnosis of a redundant EV (**Figure 1**). During the ASD occlusion, the pigtail was left inside the RV to avoid any tissue interference with the ASD occluder (**Appendix Figure 1**). The utility of a pigtail catheter to deflect the EV during percutaneous ASD occlusion has been reported previously. However, our case demonstrates the usefulness of an RV catheter not only to avoid tissue interference

during ASD occlusion but also to distinguish between anatomical variations (**Figure 1**).

## Conflict of interest statement

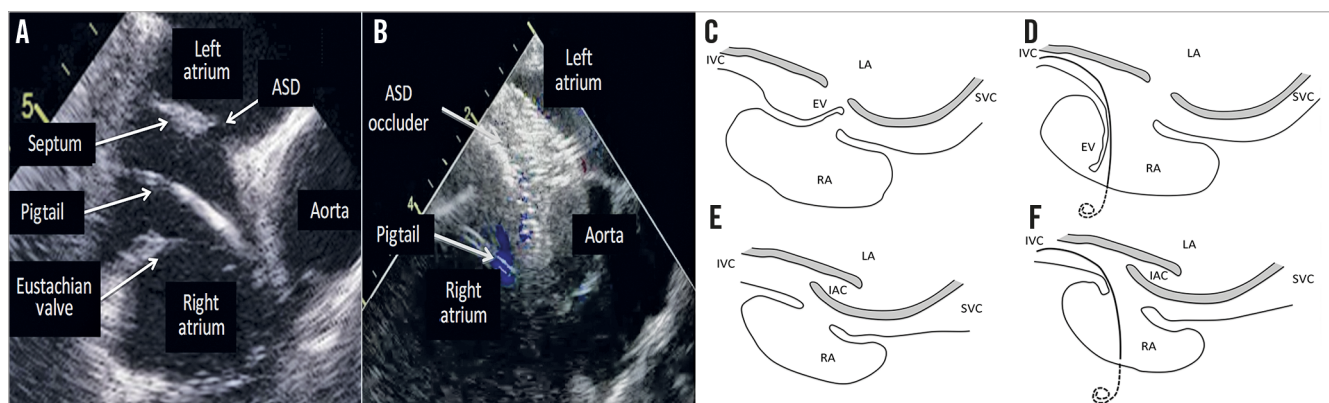
The authors have no conflicts of interest to declare.

## References

1. Lida R, Vonder Muhll L. A prominent Eustachian valve dividing the right atrium imaged by three-dimensional transoesophageal echocardiography. *J Clin Ultrasound*. 2013;41:514-6.
2. Roberson DA, Javois AJ, Cui W, Madronero LF, Cuneo BF, Muangmingsuk S. Double atrial septum with persistent interatrial space: echocardiographic features of a rare atrial septal malformation. *J Am Soc Echocardiogr*. 2006;19:1175-81.

## Supplementary data

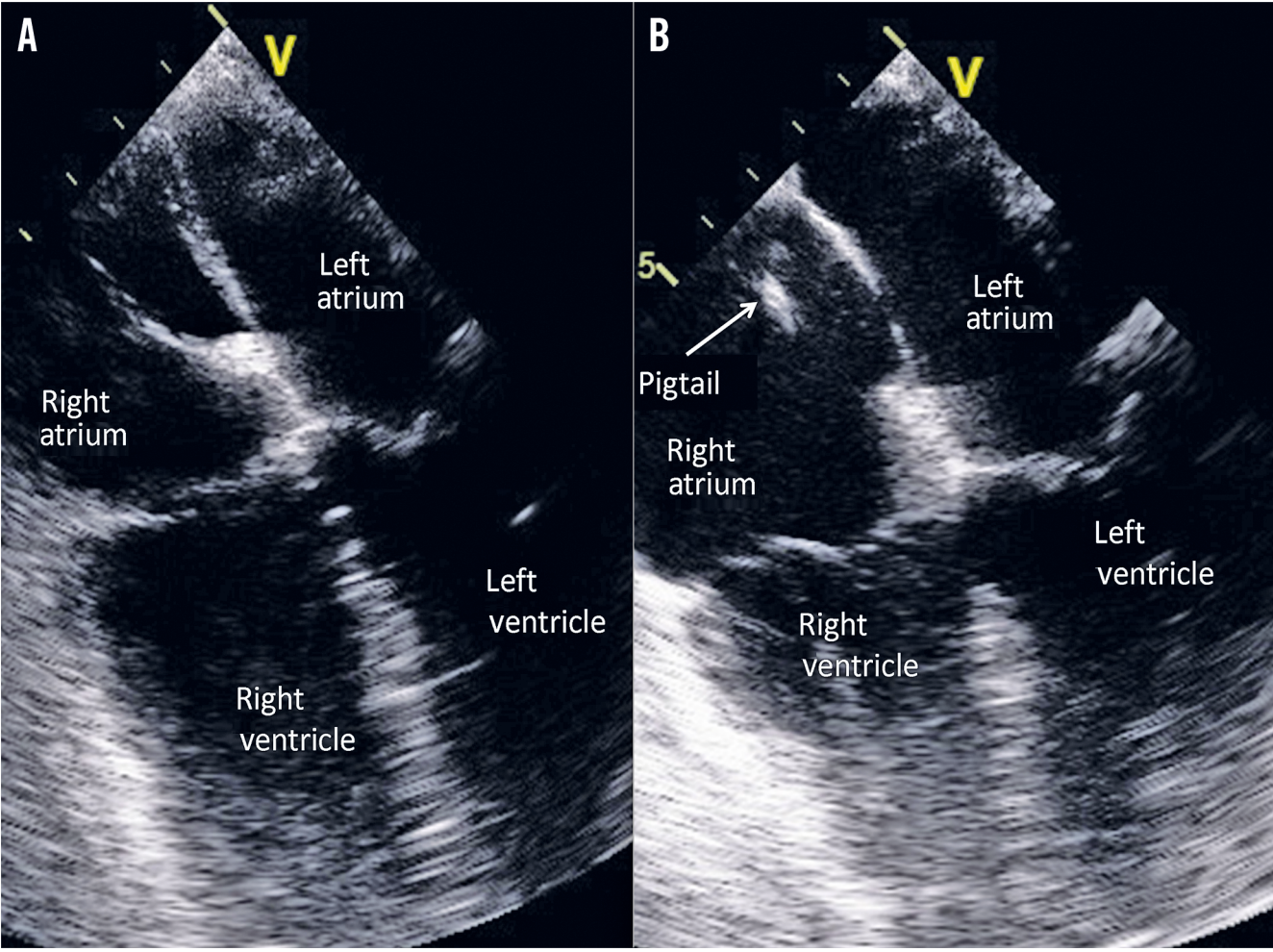
**Appendix Figure 1.** TEE image. The possible DAS was ruled out after deflecting a redundant EV with a pigtail catheter.



**Figure 1.** Differences between double atrial septum and redundant Eustachian valve. TEE image of the EV deflection with a pigtail (A) precluding any tissue interference with the ASD occluder (B). The insertion of a catheter into the RV changes the septum appearance in a redundant EV (C&D) but not in a DAS (E&F). EV: Eustachian valve; IAC: interatrial chamber; IVC: inferior vena cava; LA: left atrium; RA: right atrium; SVC: superior vena cava.

\*Corresponding author: Cardiology Department, Thorax Institute, Hospital Clínic, IDIBAPS, University of Barcelona, c/ Villarroel 170, 08036 Barcelona, Spain. E-mail: freixa@clinic.ub.es

# Supplementary data



**Appendix Figure 1.** TEE image. The possible DAS (A) was ruled out after deflecting a redundant EV with a pigtail catheter (B).