

# Contemporary practice and technical aspects in coronary intervention with bioresorbable scaffolds: a European perspective

Corrado Tamburino<sup>1</sup>, MD, PhD; Azeem Latib<sup>2</sup>, MD; Robert-Jan van Geuns<sup>3</sup>, MD; Manel Sabate<sup>4</sup>, MD; Julinda Mehilli<sup>5</sup>, MD; Tommaso Gori<sup>6</sup>, MD, PhD; Stephan Achenbach<sup>7</sup>, MD; Manuel Pan Alvarez<sup>8</sup>, MD; Holger Nef<sup>9</sup>, MD; Maciej Lesiak<sup>10</sup>, MD; Carlo Di Mario<sup>11</sup>, MD; Antonio Colombo<sup>2</sup>, MD; Christoph K. Naber<sup>12</sup>, MD; Giuseppe Caramanno<sup>13</sup>, MD; Piera Capranzano<sup>1</sup>, MD; Salvatore Brugaletta<sup>4</sup>, MD; Salvatore Geraci<sup>13</sup>, MD; Aleksander Araszkiwicz<sup>10</sup>, MD; Alessio Mattesini<sup>11</sup>, MD; Stylianos A. Pyxaras<sup>12</sup>, MD; Lukasz Rzeszutko<sup>14</sup>, MD; Rafalo Depukat<sup>14</sup>, MD; Roberto Diletti<sup>3</sup>, MD; Els Boone<sup>15</sup>, MSc; Davide Capodanno<sup>1\*</sup>, MD, PhD; Dariusz Dudek<sup>14</sup>, MD

1. Ferrarotto Hospital, University of Catania, Catania, Italy; 2. EMO-GVM Centro Cuore and San Raffaele Hospitals, Milan, Italy; 3. Department of Cardiology, Erasmus Medical Center, Rotterdam, The Netherlands; 4. Department of Cardiology, Thorax Institute, Hospital Clinic, IDIBAPS, University of Barcelona, Barcelona, Spain; 5. Department of Cardiology, Munich University Clinic, Ludwig-Maximilian University and Munich Heart Alliance at DZHK, Munich, Germany; 6. Medizinische Klinik und Poliklinik, Universitätsmedizin Mainz, University Medical Center, Mainz, Germany; 7. Department of Cardiology, University of Erlangen, Erlangen, Germany; 8. Servicio de Cardiología, Hospital Reina Sofía, Universidad de Córdoba (IMIBIC), Córdoba, Spain; 9. Department of Cardiology, University of Giessen, Giessen, Germany; 10. Department of Cardiology, University of Medical Sciences, Poznan, Poland; 11. National Institute of Health Research Cardiovascular BRU, Royal Brompton Hospital & Imperial College, London, United Kingdom; 12. Contilia Heart and Vascular Center, Elisabeth-Krankenhaus, Essen, Germany; 13. San Giovanni di Dio Hospital, Agrigento, Italy; 14. Department of Interventional Cardiology, Jagiellonian University Medical College, Krakow, Poland; 15. Abbott Vascular, Diegem, Belgium

## KEYWORDS

- bioresorbable vascular scaffold
- consensus document

## Abstract

**Aims:** Next to patient characteristics, the lack of a standardised approach for bioresorbable vascular scaffold (BVS) implantation is perceived as a potential explanation for the heterogeneous results reported so far. To provide some guidance, we sought to find a consensus on the best practices for BVS implantation and management across a broad array of patient and lesion scenarios.

**Methods and results:** Fourteen European centres with a high volume of BVS procedures combined their efforts in an informal collaboration. To get the most objective snapshot of different practices among the participating centres, a survey with 45 multiple choice questions was prepared and conducted. The results of the survey represented a basis for the technical advice provided in the document, whereas areas of controversy are highlighted.

**Conclusions:** Consensus criteria for patient and lesion selection, BVS implantation and optimisation, use of intravascular imaging guidance, approach to multiple patient and lesion scenarios, and management of complications, were identified.

\*Corresponding author: University of Catania, Cardiovascular Department, Ferrarotto Hospital, Via Citelli 6, 95124 Catania, Italy. E-mail: dcapodanno@gmail.com

## Introduction

Current-generation drug-eluting stents (DES) hold several advantages over previous-generation DES and bare metal stents<sup>1</sup>. However, permanent metallic caging of the coronary vessel by contemporary DES is still perceived as a limitation, in that it abrogates vasomotion, thereby preventing late expansive remodelling.

Bioresorbable scaffolds promise complete bioresorption after two to three years, vessel lumen enlargement, reduction of the plaque:media ratio, and restoration of vasomotion<sup>2</sup>. Most of the available experience and data regarding these devices have so far been generated with the everolimus-eluting Absorb bioresorbable vascular scaffold (BVS) (Abbott Vascular, Santa Clara, CA, USA). In the ABSORB II trial, BVS showed similar one-year composite secondary clinical results compared to everolimus-eluting DES in relatively simple lesions<sup>3</sup>. Conversely, heterogeneous outcomes have been reported from registries including more complex populations than those investigated in ABSORB II (**Online Table 1**)<sup>4,5</sup>.

Next to patient characteristics, the lack of a standardised approach when implanting BVS is perceived as a potential explanation for the varying outcomes reported so far<sup>6</sup>. To provide some guidance, a group of interventional cardiologists from high-volume centres across Europe, all with specific expertise and experience regarding PCI with BVS, sought to find a consensus on the best practices for BVS implantation and management across a broad array of patient and lesion scenarios (details on the objectives and methodology can be found in the **Online Appendix**).

## Device description

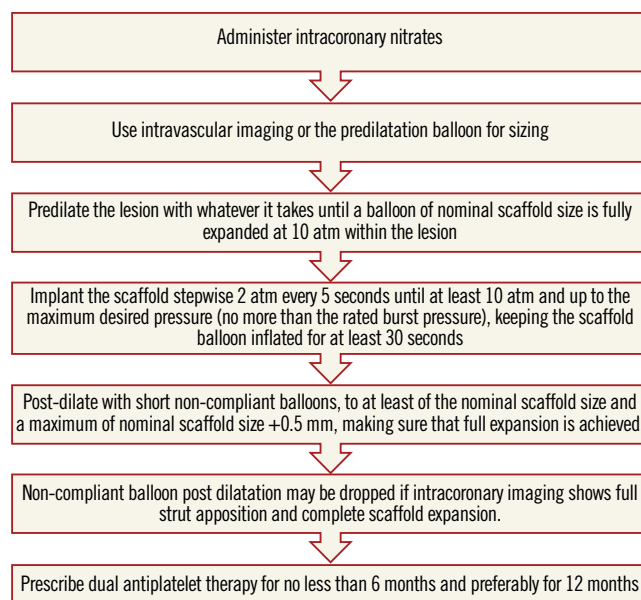
A full description of the device is given in the **Online Appendix**.

## General implantation rules

**Online Table 2-Online Table 9** illustrate the results of a survey conducted across the participating centres to facilitate reaching a consensus on the most accepted and advisable practices for BVS use. The results of this survey constitute the background for the advice provided in the present document, with areas of controversy highlighted where necessary. A standard operating protocol for BVS use is provided as a practical guide for new users of BVS (**Figure 1**).

## EVALUATION OF PATIENT AND LESION SUITABILITY

New users of BVS should ideally build up their experience gradually, starting with simple lesions, and, as experience is gained, more complex lesions can be treated. In the authors' opinion, patients who may particularly benefit from BVS implantation are typically young and/or present with long lesions, as long chains of metallic stents increase the risk for late failure. As a general rule, BVS should not be implanted into lesions that cannot be adequately prepared with balloon inflations, particularly when the balloon used for predilatation cannot be fully expanded or when the result of dilation is unsatisfactory (i.e., residual stenosis >40%). Indeed, due to the relatively thick struts, underexpansion of BVS represents a potential risk for scaffold thrombosis or restenosis. Considerations on lesion suitability should also include a careful evaluation of the



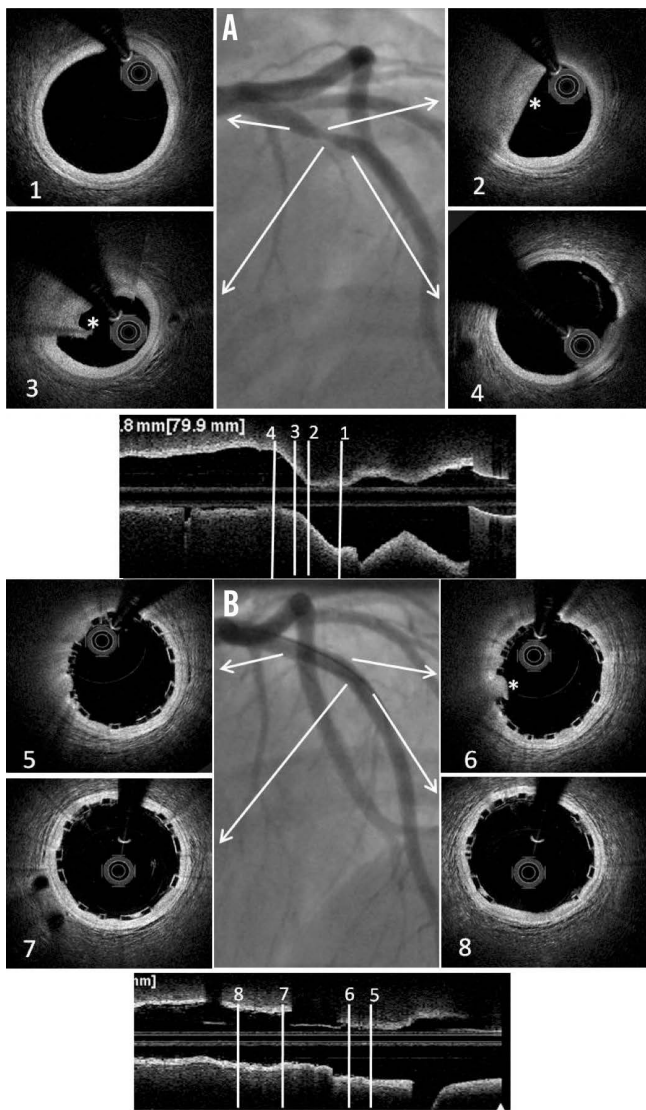
**Figure 1.** Practical operating protocol for new users of BVS.

vessel location (proximal versus distal), vessel size and plaque morphology. The ability to reach the target lesion with the device can be jeopardised by extreme vessel tortuosity before the stenosis, especially in the presence of heavy calcifications. Finally, it should be emphasised that the 3.5 mm BVS should not be expanded above 4.0 mm, a threshold above which the polymeric struts might break, which limits current use in coronary segments with a large diameter such as the left main coronary artery.

## VESSEL SIZING AND SCAFFOLD SELECTION

The polymeric nature of BVS leads to physical limitations that should be taken into account before deployment, since improper handling of their limited ability for overexpansion can lead to disruption of scaffold integrity within the vessel. Hence, meticulous vessel sizing before BVS implantation is crucial for procedural success.

Conventional practice is based on a careful review of the angiogram comparing the vessel lumen with the known dimensions of the guiding catheter after administration of an intracoronary bolus of nitroglycerine. If sufficiently large balloons are used for predilatation, which is advisable, they can also help sizing. In case of doubt regarding vessel size, it is advisable to upsize the scaffold (**Online Table 10**). As compared to visual estimation, quantitative coronary angiography provides information that is more objective, but it also tends to underestimate the lumen diameter, offering no information on the true vessel size (**Online Appendix**). Intravascular imaging with intravascular ultrasound (IVUS) or optical coherence tomography (OCT) is widely considered the gold standard for scaffold size selection, although in the authors' experience it is not routinely used and not absolutely required for this purpose (**Figure 2**). Pragmatically, except in case of extreme vessel tapering, scaffold selection should follow the proximal maximal vessel diameter or should be based on the interpolated method. Sequential



**Figure 2.** Sizing and post-implant OCT evaluation. Case example. A) Baseline angiogram showing a severe stenosis at the proximal LAD. Boxes 1 and 4: OCT proximal and distal references (proximal mean diameter=3.21 mm, distal mean diameter=3.12 mm). Boxes 2 and 3: OCT lipid rich plaque (\*). B) Angiogram showing the final result after deployment of a 3.5×12 mm BVS post-dilated with a 3.5 mm NC balloon at 12 atm. Boxes 5 and 8: proximal and distal edges with well apposed struts. Box 6: limited tissue prolapse (\*) not affecting the lumen area significantly. Box 7: Mid portion of the BVS with well apposed struts.

implantation of scaffolds with different diameters can also help to accommodate different vessel reference diameters at the proximal and distal ends of the lesion when required.

### LESION PREPARATION

Lesion preparation before deployment is an essential step of any stent implantation procedure. This is particularly crucial for patients receiving BVS, where the goal of lesion preparation is to facilitate scaffold delivery, reduce plaque shift, and, most importantly, to allow optimal scaffold expansion (**Online Table 11**). Effective

plaque cracking, especially in patients with long tapered lesions, ostial lesions, chronic total occlusions, bifurcations, and calcified lesions, is essential to avoid underexpansion. For this reason, direct BVS placement is typically not recommended, even in acute coronary syndromes.

For lesion preparation, it is generally advisable to use semi- or non-compliant balloons with a diameter equal to or only minimally undersized compared to the diameter of the selected BVS delivery system. Short (6 to 10 mm long) high-pressure balloons should be used after predilation of the segments when lesions show focal residual underexpansion due to the presence of highly calcific atherosclerotic plaques. Although no supporting data are available, the use of plaque modification devices (i.e., cutting/scoring balloons, rotational atherectomy) is encouraged when necessary to enable the BVS to cross and better expand calcified stenoses, but in the authors' experience this is rarely required. In the event that one cannot achieve full opening of the (last) predilatation balloon with no indentation, it is advisable not to implant a BVS.

### SCAFFOLD IMPLANTATION AND OPTIMISATION

When difficulties are anticipated during crossing of the lesion, an extra back-up support guiding catheter or a guide extension (i.e., GuideLiner<sup>®</sup>; Vascular Solutions, Inc., Minneapolis, MN, USA, or Guidezilla<sup>®</sup>; Boston Scientific, Marlborough, MA, USA), a more supportive guidewire or a buddy wire may be considered. All sizes of BVS can be delivered through a 7 Fr guide extension (i.e., 6 in 7 Fr). 6 Fr guide extension systems (i.e., 5 in 6 Fr) can accommodate 2.5 mm and 3.0 mm BVS, but require preloading into the extension tube outside the patient's body. A 3.5 mm BVS cannot be used with a 5-in-6 Fr guide extension.

The scaffold should cover  $\geq 2$  mm of the healthy vessel at either edge of the lesion. Since overlapping of struts should be minimised, too short BVS should be avoided, and the BVS size should allow sufficient margins for post-expansion to optimise apposition proximally. Deployment must occur gradually, pressurising the delivery system in 2 atm increments every five seconds until complete expansion of the scaffold. Some operators prefer to increase the inflation pressure beyond nominal (10 atm) and up to the rated burst pressure (16 atm) to achieve full scaffold expansion. Upon device deployment, target pressure should be maintained for at least 30 seconds. Due to the polymeric material, the BVS has a maximum scaffold expansion limit of 0.5 mm above its nominal diameter, which should be respected strictly during implantation. Upon scaffold deployment, one should aim to obtain <10% residual stenosis, full scaffold expansion and optimal wall apposition. Therefore, routine post-dilatation for 10-30 seconds using a high-pressure non-compliant balloon is advisable unless intracoronary imaging confirms full expansion and apposition.

### INTRAVASCULAR IMAGING

Anecdotal cases of BVS thrombosis following inadequate expansion and apposition of the BVS have indirectly supported an extensive application of intravascular imaging techniques<sup>7</sup>. In the



absence of clear evidence of benefit from large controlled trials, there is agreement among the authors that new users of BVS especially should have a low threshold for the use of imaging before and after BVS implantation.

IVUS has the advantage of visualising the total vessel diameter and area, which allows optimisation of scaffold size while reducing the risk of disruption with oversized balloons. OCT has higher resolution, so that scaffold integrity, apposition to the underlying wall, presence of thrombus, edge dissections, and changes in strut characteristics over time can be easily studied (**Figure 2, Online Figure 1**). Subintimal calcifications detected with OCT may call for pre-intervention rotational atherectomy or the use of scoring devices. Incomplete scaffold expansion detected either by OCT or by IVUS suggests that further steps should be taken for lesion optimisation with higher pressure or balloons of larger diameter (preferably with short lengths). Small edge dissections identified by OCT at the scaffold edges can often be left untreated in the absence of severe plaque burden or vessel recoil.

## Specific subsets and technical limitations

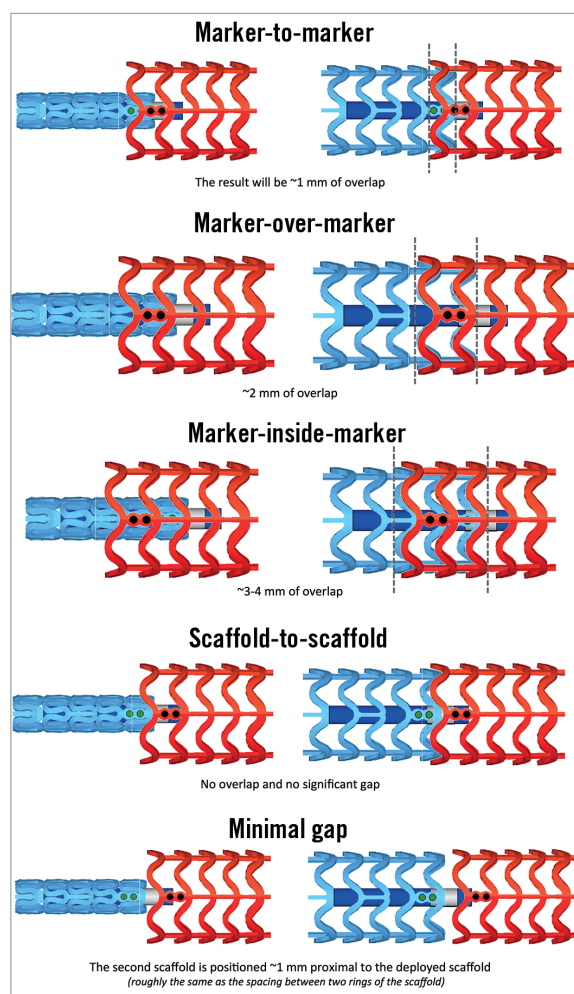
### BIFURCATIONS

When treatment of bifurcation lesions is desired with BVS, the provisional stenting technique seems to be a logical approach. However, the BVS is a breakable device, thus the proximal optimisation technique, side branch (SB) fenestration, and kissing balloon inflation should be performed with caution. For one-stent approaches, two very simple strategies could be considered: i) one BVS across the bifurcation and nothing else (preferred by most of the authors), and ii) SB predilation and one BVS across the bifurcation. These strategies have the advantage of avoiding scaffold deformation, but they cannot always be used, and lateral dilation of SB through the BVS struts may be desired. Two issues should be borne in mind when this manoeuvre is considered: i) the maximum tolerated balloon diameter and inflation pressure used to dilate the SB, and ii) the maximum tolerated balloon diameter used to correct the induced BVS deformation at the main vessel. In a recent *in vitro* study, the authors observed no fractures when the balloon used for fenestration towards the side branch was  $\leq 2.0$  mm, but 16% of fractures were noted when a 3.0 mm BVS had side dilation with 2.5 or 3.0 mm balloons<sup>8</sup>. This fracture rate was reduced to 6% when a 3.5 mm BVS was evaluated with the same technique. In case of fracture, prolonged balloon inflation of the main vessel could partially restore the geometry of the BVS, with uncertain outcomes. With respect to the correction of BVS deformation, the classic kissing balloon inflation is not recommended due to the possibility of proximal strut fracture. Several alternatives to the classic kissing can be used: i) single balloon post-dilation at the nominal value of the BVS; ii) sequential balloon inflations; iii) undersized kissing with the proximal theoretical mean hugging balloon diameter (calculated by the Mitsudo formula<sup>9</sup>) smaller than the BVS nominal value +0.5 mm; iv) kissing with minimal balloon overlap (“snuggle or mini-kissing”). Benchtop data suggest that the fracture threshold for mini-kissing balloon inflation is 5 atm<sup>8</sup>. When a second stent is required in the

SB, a second BVS or a metallic stent can be advanced and implanted through the main vessel BVS, although the latter might be easier as crossing profiles are generally smaller. Techniques with least strut layering should be preferred (i.e., T, T and small protrusion) when a second stent or scaffold is needed. Complex bifurcation scaffolding procedures should ideally be avoided with BVS or even undertaken under intravascular imaging guidance to detect and correct possible scaffold fractures or deformations.

### LONG LESIONS

Since the longest scaffold length currently available is 28 mm, stenting longer segments requires overlapping of two or more scaffolds. The relatively thick struts of BVS mandate keeping the overlap to a minimum to avoid delays in healing<sup>10</sup>. For an optimal overlap technique, it should be noted that the scaffold marker beads are not located at the edges of the scaffold. The scaffold edges fall within the 1 mm balloon markers on each end and the scaffold marker beads are placed approximately 1 mm from the scaffold end. Therefore, if the balloon marker lines up with the scaffold marker, the result will be  $\sim 1$  mm of overlap. Against this background, there are many possible overlap techniques (**Figure 3**). The two most



**Figure 3.** BVS overlapping techniques.

advised by the authors are the “marker-to-marker” (~1 mm of overlap) and “scaffold-to-scaffold” (no overlap) techniques. In the marker-to-marker configuration, which appears to be the best one to avoid gap restenosis, the second scaffold is advanced until the distal balloon markers line up with the proximal marker beads of the implanted scaffold. As such, the markers of the second scaffold will be adjacent to the markers of the deployed scaffold. Attention should be paid to scaffold size selection and placement order (i.e., starting with the distal scaffold is preferred) to avoid damage at the overlap site. Working in orthogonal views helps to avoid markers on the second device appearing closer than they actually are due to foreshortening.

### THROMBOTIC LESIONS

Recent reports have shown that BVS may be safely implanted in the context of thrombotic lesions in acute coronary syndromes<sup>11-13</sup>. A theoretical advantage of BVS implantation in thrombotic lesions could be the reduction in distal embolisation due to the larger strut width, with a possible increased capacity of the BVS to entrap thrombotic material between the scaffold and the vessel wall. In addition, device undersizing facilitated by acute phase vasoconstriction, while being permanent when using metal stents, could be counterbalanced by bioresorption and positive vessel remodelling in the BVS scenario. In ST-elevation myocardial infarction, predilation is sometimes perceived as more risky than in stable lesions, and accurate evaluation of lumen diameter is hampered by vasospasm and the thrombotic nature of the lesion. In this setting, thrombectomy and intracoronary nitrates administration may represent two important steps before deciding whether a BVS can be implanted. The use of thrombectomy devices prior to scaffold implantation may also help to foresee the crossability of the lesion and potential difficulties to be encountered during implantation.

### CALCIFIED LESIONS

In pivotal trials of BVS, severely calcified lesions were excluded. While the positive effect of BVS on vasomotion may not materialise in these lesions, other effects such as conformability, late lumen enlargement, disappearance of late uncovered struts and late inflammatory processes might still apply. However, with the larger crossing profile of BVS, lesion preparation, as well as sufficient guide catheter and guidewire support, is even more essential. With proper lesion preparation, if necessary using debulking strategies, lumen gain similar to the gain achieved in other non-calcified lesions can be achieved. Full dilatation of the lesions with non-compliant balloons or cutting balloons is a prerequisite for success.

### CHRONIC TOTAL OCCLUSIONS

Data on the performance of BVS in chronic total occlusion (CTO) lesions are sparse. However, the biomechanical properties of BVS make these platforms suitable for recanalised CTO lesions, with the following considerations. First, the chain of scaffolds required to cover these long lesions fully could chronically influence the vessel

rheological properties and increase the risk of restenosis. Second, particularly the use of dissection/re-entry techniques to achieve successful guidewire passage is associated with higher probability of SB occlusion and subintimal haematomas, which can lead to reduced outflow and aneurysm formation. These result in higher risk of late stent malapposition leading to stent thrombosis and restenosis<sup>14</sup>. On the other hand, later disappearance of the scaffold struts, allowing early recovery of vessel motility and late liberation of caged SB, promises longer-term benefits.

The frequent presence of calcifications as well as the hypoplastic transformation of the distal bed of the occluded artery due to the chronic low flow state makes implantation of BVS in these lesions a challenge<sup>15</sup>. As a result, optimal lesion preparation and BVS selection become even more necessary for CTO PCI. Due to the lack of long-term data, the authors do not recommend covering long subintimal channels with multiple scaffolds.

### IN-STENT RESTENOSIS

Currently, PCI using DES or drug-coated balloons is the most accepted approach for treating in-stent restenosis. From a theoretical standpoint and despite currently representing an off-label indication, BVS might be of potential advantage in this setting for two reasons. First, when compared with a drug-coated balloon, a BVS provides a more prolonged drug delivery capability. Most drug-coated balloons are coated with paclitaxel; however, the superiority of sirolimus and everolimus has been reported in several clinical trials, which might be an additional advantage of everolimus-eluting BVS for this specific indication. In addition, the scaffold struts provide vessel scaffolding at the edge of the former stent, which is also not provided by drug-coated balloons. Second, disappearance of the BVS may avoid long-term strut layering (“onion skin”), although caging of the vessel persists and late luminal enlargement is prevented. If the reason for restenosis is neoatherosclerosis, debulking devices should be considered.

### POST-TREATMENT MANAGEMENT

Considerations on post-treatment management of BVS are provided in the **Online Appendix**.

## How to prevent and manage BVS complications

### SCAFFOLD DISRUPTION

*In vivo* disruption of a BVS is a rare complication when the recommendations of the manufacturer are followed strictly (**Online Figure 2**). The exact incidence of scaffold disruption is unknown but appears to be associated with post-dilatation above the recommended limit, kissing balloon inflation, strut opening towards the side branch with balloons larger than 2.0 mm, and implantation in areas of excessive torsion or flexion.

### SCAFFOLD MALAPPOSITION, RESTENOSIS, MULTIPLE INTERSTRUT HOLLOWES

Data on the incidence of acute, persistent, and late acquired malapposition of BVS are still very limited<sup>16,17</sup>. The malapposition rate

seems to drop over time due to physiological healing phenomena (i.e., endothelialisation). The incidence of late acquired malapposition, possibly due to overstretching at implantation, is unknown. The presence of fibrocalcific plaques, lack of adequate lesion preparation (i.e., insufficient predilatation), and post-dilatation with excessively short balloons may all be associated with BVS malapposition<sup>16,17</sup>. Importantly, malapposition has been reported to be associated with the presence of uncovered struts.

Current knowledge regarding BVS restenosis is also at an early stage. Small retrospective studies suggest restenosis rates of 6% at three years of clinical follow-up<sup>18</sup>, mostly associated with incomplete scaffold expansion. Optimal management of BVS restenosis, including the chance for different strategies based on the predicated integrity of the scaffold in relation to the time to restenosis, is undefined and warrants dedicated studies. Most of the authors agree that metallic stent implantation should be considered in case of BVS restenosis.

In a minority of cases, peri-stent contrast staining (defined as contrast staining outside the stent contour extending to >20% of the stent diameter measured by quantitative coronary angiography) and multiple interstrut hollows (defined as multiple hollows with maximum depth >0.5 mm existing between and outside well-apposed stent struts), which have previously been associated with abnormal vascular reactions to the eluted drug and/or the polymer, have also been observed<sup>19</sup>.

Illustrative case examples of scaffold malapposition, restenosis and multiple interstrut hollows are provided in **Online Figure 3**.

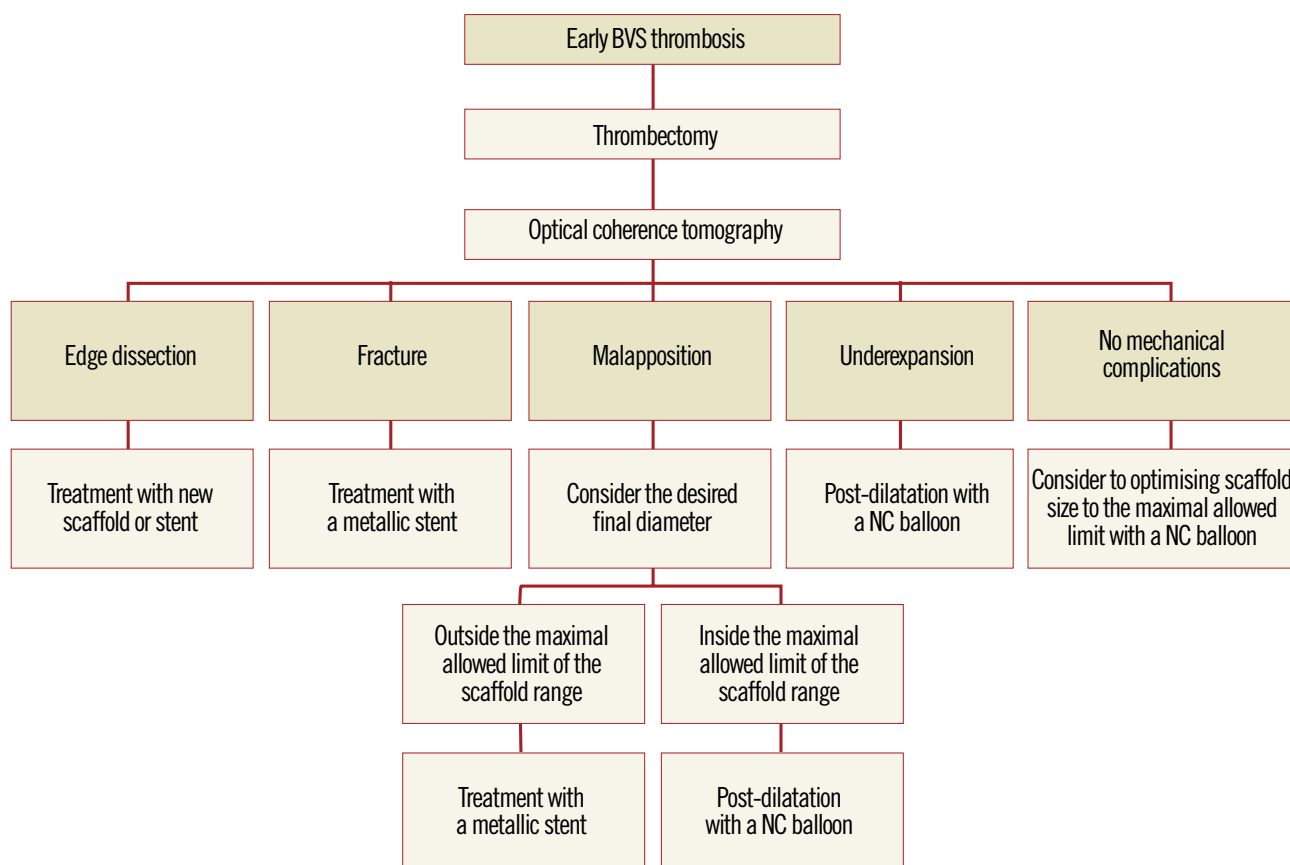
### EARLY SCAFFOLD THROMBOSIS

Early thrombotic events following BVS implantation have been reported in some series<sup>4,20</sup>. This may reflect the high complexity of the lesions treated and/or reasons linked to suboptimal implantation. As a general rule, one should exclude two potential causes of early scaffold thrombosis: mechanical issues or suboptimal antithrombotic therapy. Whenever thrombosis occurs, use of intravascular guidance is recommended to rule out and guide correction of any mechanical causes.

Another important point is whether scaffold thrombosis should be treated with metallic stent implantation or not<sup>21</sup>. Treatment by metallic stent implantation should be reserved for cases of documented fracture or when the operator wants to achieve a final diameter beyond the maximum permitted ranges of the BVS<sup>22</sup>. Metallic stent implantation should aim to cover at least the fractured or malapposed struts. A proposed algorithm for management of early scaffold thrombosis is displayed in **Figure 4**.

### Limitations

BVS therapy is not free from limitations. Apart from some considerations outlined above, such as the challenges in bifurcation and



**Figure 4.** Proposed algorithm for the treatment of early scaffold thrombosis.

calcified lesions, some further limitations exist that may warrant careful consideration as to whether or not to use a BVS in a specific patient or lesion (**Online Table 12**).

## Conclusions

Within a short time, BVS have become an accepted therapy for selected patients undergoing PCI. Current BVS devices differ significantly from DES and require special procedural considerations to achieve optimal short- and long-term results.

### Impact on daily practice

Despite the lack of compelling long-term data from large randomised clinical trials, BVS implantation is now frequently undertaken in many European and non-European catheterisation laboratories. Appraising the knowns and unknowns of a new technology is critical, particularly in the earlier phases of its introduction and implementation in daily practice. The present document aims to disseminate harmonised criteria for BVS use, and to provide education and practical advice in a field where evidence is rapidly accumulating. The impact of a standardised approach for BVS use on clinical outcomes remains unknown, but optimal implantation techniques may have an impact on blunting the rates of early and late scaffold failure.

### Conflict of interest statement

C. Tamburino, R-J. van Geuns, J. Mehilli, T. Gori and H. Nef have received speaker's honoraria from Abbott Vascular. R-J. van Geuns, S. Achenbach and H. Nef have received research grants (institutional) from Abbott Vascular. E. Boone is an employee at Abbott Vascular. D. Capodanno has received consulting honoraria from Abbott Vascular. The other authors have no conflicts of interest to declare.

## References

1. Stefanini GG, Holmes DR Jr. Drug-eluting coronary-artery stents. *N Engl J Med*. 2013;368:254-65.
2. Iqbal J, Onuma Y, Ormiston J, Abizaid A, Waksman R, Serruys P. Bioresorbable scaffolds: rationale, current status, challenges, and future. *Eur Heart J*. 2014;35:765-76.
3. Serruys PW, Chevalier B, Dudek D, Cequier A, Carrié D, Iniguez A, Dominici M, van der Schaaf RJ, Haude M, Wasungu L, Veldhof S, Peng L, Staehr P, Grundeken MJ, Ishibashi Y, Garcia-Garcia HM, Onuma Y. A bioresorbable everolimus-eluting scaffold versus a metallic everolimus-eluting stent for ischaemic heart disease caused by de-novo native coronary artery lesions (ABSORB II): an interim 1-year analysis of clinical and procedural secondary outcomes from a randomised controlled trial. *Lancet*. 2014 Sep 12. [Epub ahead of print].
4. Capodanno D, Gori T, Nef H, Latib A, Mehilli J, Lesiak M, Caramanno G, Naber C, Di Mario C, Colombo A, Capranzano P, Wiebe J, Araszkievicz A, Geraci S, Pyxaras S, Mattesini A, Naganuma T, Münzel T, Tamburino C. Percutaneous coronary intervention with everolimus-eluting bioresorbable vascular scaffolds in routine clinical practice: early and midterm outcomes from the European multicentre GHOST-EU registry. *EuroIntervention*. 2014 Jul 18. [Epub ahead of print].
5. Abizaid A, Costa JR Jr, Bartorelli AL, Whitbourn R, van Geuns RJ, Chevalier B, Patel T, Seth A, Stuteville M, Dorange C, Cheong WF, Sudhir K, Serruys PW. The ABSORB EXTEND study: preliminary report of the twelve-month clinical outcomes in the first 512 patients enrolled. *EuroIntervention*. 2014 Apr 29. [Epub ahead of print].
6. Ishibashi Y, Nakatani S, Onuma Y. Definite and probable bioresorbable scaffold thrombosis in stable and ACS patients. *EuroIntervention*. 2014 Sep 22. [Epub ahead of print].
7. Gori T, Schulz E, Münzel T. Immediate, acute, and subacute thrombosis due to incomplete expansion of bioresorbable scaffolds. *JACC Cardiovasc Interv*. 2014;7:1194-5.
8. Ormiston JA, Webber B, Ubod B, Webster MW, White J. Absorb everolimus-eluting bioresorbable scaffolds in coronary bifurcations: a bench study of deployment, side branch dilatation and post-dilatation strategies. *EuroIntervention*. 2014 May 20. [Epub ahead of print].
9. Morino Y, Yamamoto H, Mitsudo K, Nagaoka M, Takeuchi H, Okamoto N, Kozuma K, Matsuzaki A, Tanabe K, Hara K, Tanabe T, Ikari Y. Functional formula to determine adequate balloon diameter of simultaneous kissing balloon technique for treatment of bifurcated coronary lesions: clinical validation by volumetric intravascular ultrasound analysis. *Circ J*. 2008;72:886-92.
10. Farooq V, Serruys PW, Heo JH, Gogas BD, Onuma Y, Perkins LE, Diletti R, Radu MD, Räber L, Bourantas CV, Zhang Y, van Remortel E, Pawar R, Rapoza RJ, Powers JC, van Beusekom HM, Garcia-Garcia HM, Virmani R. Intracoronary optical coherence tomography and histology of overlapping everolimus-eluting bioresorbable vascular scaffolds in a porcine coronary artery model: the potential implications for clinical practice. *JACC Cardiovasc Interv*. 2013;6:523-32.
11. Gori T, Schulz E, Hink U, Wenzel P, Post F, Jabs A, Münzel T. Early outcome after implantation of Absorb bioresorbable drug-eluting scaffolds in patients with acute coronary syndromes. *EuroIntervention*. 2014;9:1036-41.
12. Diletti R, Karanasos A, Muramatsu T, Nakatani S, Van Mieghem NM, Onuma Y, Nauta ST, Ishibashi Y, Lenzen MJ, Ligthart J, Schultz C, Regar E, de Jaegere PP, Serruys PW, Zijlstra F, van Geuns RJ. Everolimus-eluting bioresorbable vascular scaffolds for treatment of patients presenting with ST-segment elevation myocardial infarction: BVS STEMI first study. *Eur Heart J*. 2014;35:777-86.
13. Kocka V, Maly M, Tousek P, Buděšínský T, Lisa L, Prodanov P, Jarkovský J, Widimský P. Bioresorbable vascular scaffolds in acute ST-segment elevation myocardial infarction: a prospective multicentre study 'Prague 19'. *Eur Heart J*. 2014;35:787-94.
14. Valenti R, Vergara R, Migliorini A, Parodi G, Carrabba N, Cerisano G, Dovellini EV, Antoniucci D. Predictors of reocclusion after successful drug-eluting stent-supported percutaneous coronary

intervention of chronic total occlusion. *J Am Coll Cardiol*. 2013;61:545-50.

15. Morino Y, Abe M, Morimoto T, Kimura T, Hayashi Y, Muramatsu T, Ochiai M, Noguchi Y, Kato K, Shibata Y, Hiasa Y, Doi O, Yamashita T, Hinohara T, Tanaka H, Mitsudo K. Predicting successful guidewire crossing through chronic total occlusion of native coronary lesions within 30 minutes: the J-CTO score as a difficulty grading and time assessment tool. *JACC Cardiovasc Interv*. 2011;4:213-21.

16. Gomez-Lara J, Radu M, Brugaletta S, Bruining N, Radu MD, van Geuns RJ, Thuesen L, McClean D, Koolen J, Windecker S, Whitbourn R, Oberhauser J, Rapoza R, Ormiston JA, Garcia-Garcia HM, Serruys PW. Serial analysis of the malapposed and uncovered struts of the new generation of everolimus-eluting bioresorbable scaffold with optical coherence tomography. *JACC Cardiovasc Interv*. 2011;4:992-1001.

17. Brown AJ, McCormick LM, Braganza DM, Bennett MR, Hoole SP, West NE. Expansion and malapposition characteristics after bioresorbable vascular scaffold implantation. *Catheter Cardiovasc Interv*. 2014;84:37-45.

18. Nakatani S, Onuma Y, Ishibashi Y, Muramatsu T, Iqbal J, Zhang YJ, van Geuns RJ, Ormiston JA, Serruys PW. Early (before 6 months), late (6-12 months) and very late (after 12 months) angiographic scaffold restenosis in the ABSORB Cohort B trial. *EuroIntervention*. 2014 Feb 27. [Epub ahead of print].

19. Tada T, Kadota K, Hosogi S, Kubo S, Ozaki M, Yoshino M, Miyake K, Eguchi H, Ohashi N, Hayakawa Y, Saito N, Otsuru S, Hasegawa D, Shigemoto Y, Habara S, Imai M, Tanaka H, Fuku Y, Oka N, Kato H, Yamamoto H, Fujii S, Goto T, Mitsudo K. Optical coherence tomography findings in lesions after sirolimus-eluting stent implantation with peri-stent contrast staining. *Circ Cardiovasc Interv*. 2012;5:649-56.

20. Kraak RP, Hassell ME, Grundeken MJ, Koch KT, Henriques JP, Piek JJ, Baan J Jr, Vis MM, Arkenbout EK, Tijssen JG, de Winter RJ, Wykrzykowska JJ. Initial experience and clinical evaluation of the Absorb bioresorbable vascular scaffold (BVS) in real-world practice: the AMC Single Centre Real World PCI Registry. *EuroIntervention*. 2014 Aug 20. [Epub ahead of print].

21. Fernández-Rodríguez D, Brugaletta S, Otsuki S, Sabaté M. Acute Absorb bioresorbable vascular scaffold thrombosis in ST-segment elevation myocardial infarction: to stent or not to stent? *EuroIntervention*. 2014;10:600.

22. Gomez-Lara J, Diletti R, Brugaletta S, Onuma Y, Farooq V, Thuesen L, McClean D, Koolen J, Ormiston JA, Windecker S, Whitbourn R, Dudek D, Dorange C, Veldhof S, Rapoza R, Regar E, Garcia-Garcia HM, Serruys PW. Angiographic maximal luminal diameter and appropriate deployment of the everolimus-eluting bioresorbable vascular scaffold as assessed by optical coherence tomography: an ABSORB cohort B trial sub-study. *EuroIntervention*. 2012;8:214-24.

## Online data supplement

**Online Appendix.** Consensus methodology, device description, quantitative coronary angiography, and post-treatment management.

**Online Table 1.** Summary of key BVS studies.

**Online Table 2.** Survey results – Patient selection.

**Online Table 3.** Survey results – Vessel sizing and scaffold size selection.

**Online Table 4.** Survey results – Lesion preparation.

**Online Table 5.** Survey results – Crossing the lesion.

**Online Table 6.** Survey results – Scaffold implantation.

**Online Table 7.** Survey results – Scaffold optimisation.

**Online Table 8.** Survey results – Adjunctive antithrombotic therapy.

**Online Table 9.** Survey results – Follow-up and complications management.

**Online Table 10.** Scaffold selection based on vessel sizing by quantitative coronary angiography.

**Online Table 11.** Step-by-step guidance on lesion preparation.

**Online Table 12.** Current limitations of the Absorb bioresorbable vascular scaffold.

**Online Figure 1.** Scaffold optimisation with optical coherence tomography.

**Online Figure 2.** Scaffold disruption. Case example.

**Online Figure 3.** Illustrative case examples of malapposition, restenosis and multiple interstrut hollows by optical coherence tomography cross-sections.



# Online data supplement

## Appendix

### CONSENSUS METHODOLOGY

Fourteen European centres with a high volume of PCI procedures with BVS combined efforts in an informal collaboration with the following objectives: i) to explore different contemporary practices for the use of BVS; ii) to build a consensus on accepted technical approaches for BVS implantation; iii) to prepare a document summarising the results of this joint effort. One meeting which also included representatives of the device manufacturer was held in Frankfurt, Germany, in March 2014. To get the most objective snapshot of different practices among the participating centres, a survey with 45 multiple choice questions was prepared and conducted in October 2014, the results of which are summarised below. The results of the survey are illustrated in **Online Table 2-Online Table 9**, which represent a basis for the technical advice provided in the document, whereas areas of controversy are highlighted. Phone conferences and e-mail exchanges followed, as necessary, to finalise the manuscript. The manufacturer supported the organisation of the face-to-face meeting and participated in the revision of the final document, but was not involved in the conduct of the survey and the elaboration of the consensus. The charge for the consortium was to identify and disseminate appropriate criteria for patient and lesion selection, scaffold implantation and optimisation, use of intravascular imaging guidance, approach to multiple patient and lesion scenarios, and management of complications. Importantly, the mission was not to provide formal recommendations in a field where the evidence basis is at an early stage, but to provide education and practical advice to those who want to accrue more experience with the BVS device.

### DEVICE DESCRIPTION

The Absorb BVS (Abbott Vascular, Santa Clara, CA, USA) consists of four components: the polymer scaffold, the polymer drug reservoir, the antiproliferative drug everolimus, and the XIENCE RX delivery system (Abbott Vascular). The scaffold is based on a semi-crystalline poly (L-lactide) acid (PLLA) backbone having a corrugated ring pattern similar to that of the MULTI-LINK<sup>®</sup> BMS (Abbott Vascular), coated with an amorphous matrix composed of everolimus and polymer poly-DL-lactide (PDLLA) in a 1:1 ratio. As the scaffold itself is radiotransparent, there are two radiopaque platinum markers at either end of the scaffold. Both PLLA and PDLLA are fully bioresorbable, with complete bioreabsorption expected by approximately 24 to 36 months. The degradation process happens gradually with minimal inflammation<sup>23</sup>. The polymer (matrix) breaks down via hydrolysis ultimately leading to CO<sub>2</sub> and H<sub>2</sub>O. The Absorb BVS has the same drug dose density and release rate as the metallic counterpart XIENCE V<sup>®</sup> (Abbott Vascular), i.e., 100 µl/cm<sup>2</sup>, with 80% of the drug eluting in the first 30 days, and the remainder eluting over 120 days. The larger size of the Absorb struts, however, results in a larger eluting surface per unit of wall surface. The currently available size matrix includes

lengths of 8, 12, 18, 23 and 28 mm at diameters of 2.5, 3.0 and 3.5 mm. Nominal strut thickness is 157 µm and the 3.0 mm scaffold has a crossing profile of 0.056 inches. The use of 6 Fr guiding catheters is recommended but BVS can also be implanted via 5 Fr guiding catheters.

### QUANTITATIVE CORONARY ANGIOGRAPHY

As compared to visual estimate, quantitative coronary angiography (QCA) provides information which is more accurate, but it also tends to underestimate the lumen diameter, offering no information on the true vessel size. Taking this limitation into account, three different parameters should be used for vessel diameter sizing with two-dimensional QCA: i)  $D_{max}$  (proximal/distal), defined as the largest vessel diameter at the level of intended implantation zone, representing the landing zone in the peri-lesion segment within 5 mm of the segment to be scaffolded; ii) the interpolated reference vessel diameter (RVD), defined as a virtual diameter at the level of minimal lumen diameter, representing an average of many vessel diameters between the two healthy segments at the lesion edges; and iii) lesion length. The interpolated RVD could be influenced by the presence of side branches and, especially in tapering vessels and for long lesions, it underestimates the maximal lumen diameter within the scaffolded region. Conversely,  $D_{max}$  is a real measurement which helps to select the appropriate BVS diameter to match the lumen diameter in the “landing zone”. In general, except in case of extreme vessel tapering, the scaffold selection should match the proximal  $D_{max}$ . When expanded at 6-8 atm it is unlikely that a BVS creates major vessel disruption at the distal end, and the size used offers a buffer proximally to avoid critical underexpansion. The relatively small length of the available BVS devices (28 mm at most) can also help when dealing with different vessel sizes proximally and distally, if needed. The considerations above are supported by a substudy of the ABSORB cohort B and ABSORB EXTEND trials, which showed that visual vessel estimation led to sizing error in over half the cases, while QCA measurements led to a significant increase in correct vessel sizing, when compared to the interpolated RVD or visual estimation<sup>24</sup>. In another substudy of the ABSORB cohort B trial,  $D_{max}$  would seem to have a bearing on the appropriate deployment of the Absorb BVS as assessed by optical coherence tomography criteria<sup>22</sup>.

### POST-TREATMENT MANAGEMENT

In current clinical practice, dual antiplatelet treatment after BVS implantation is recommended for at least 12 months in patients with acute coronary syndromes or six to 12 months in elective patients based on the guidelines for antiplatelet therapy after permanent metallic DES implantation<sup>25,26</sup>. Of note, while a minimum dual antiplatelet therapy of six months was recommended in both the ABSORB A and B cohorts, the effective duration was left to the operators' discretion and thus the mean DAPT duration in cohort B of the ABSORB trial was 403 days<sup>27</sup>. However, OCT at six months

suggests that scaffold coverage occurs in 98.9% of struts<sup>16</sup>. This phenomenon is significantly delayed in cases of scaffold overlap, due to increased shear stress and subsequent enhanced platelet aggregation<sup>28,29</sup>. As a result, some authors suggest longer dual anti-platelet therapy duration regimes (i.e., 18-24 months) and/or more potent agents (e.g., ticagrelor or prasugrel), particularly in the first months after BVS implantation because of their thicker struts<sup>30</sup>.

Current guideline recommendations on follow-up management and strategies after permanent DES implantation also apply to BVS patients and there appear to be no specific precautions. As for permanent metallic DES, the type and timing of anatomical/functional assessments after BVS implantation should be based on overall clinical risk evaluation, symptom status, stent diameter and length, treated lesions, results of previous procedure, residual stenosis and overall burden of coronary artery disease. Routine follow-up at six to 12 months with non-invasive coronary computed tomography angiography or with invasive angiography is not recommended and should be restricted to individual cases (i.e., bifurcations, CTO, multiple overlaps).

### Supplementary references

23. Otsuka F, Pacheco E, Perkins LE, Lane JP, Wang Q, Kamberi M, Frie M, Wang J, Sakakura K, Yahagi K, Ladich E, Rapoza RJ, Kolodgie FD, Virmani R. Long-term safety of an everolimus-eluting bioresorbable vascular scaffold and the cobalt-chromium XIENCE V stent in a porcine coronary artery model. *Circ Cardiovasc Interv.* 2014;7:330-42.
24. Farooq V, Gomez-Lara J, Brugaletta S, Gogas BD, Garcia-Garcia HM, Onuma Y, van Geuns RJ, Bartorelli A, Whitbourn R, Abizaid A, Serruys PW. Proximal and distal maximal luminal diameters as a guide to appropriate deployment of the ABSORB everolimus-eluting bioresorbable vascular scaffold: a sub-study of the ABSORB Cohort B and the on-going ABSORB EXTEND Single Arm Study. *Catheter Cardiovasc Interv.* 2012;79:880-8.
25. Konstantinides SV, Torbicki A, Agnelli G, Danchin N, Fitzmaurice D, Galiè N, Gibbs JS, Huisman MV, Humbert M, Kucher N, Lang I, Lankeit M, Lekakis J, Maack C, Mayer E, Meneveau N, Perrier A, Pruszczyk P, Rasmussen LH, Schindler TH, Svitil P, Vonk Noordegraaf A, Zamorano JL, Zompatori M; Task Force for the Diagnosis and Management of Acute Pulmonary Embolism of the European Society of Cardiology. 2014 ESC guidelines on the diagnosis and management of acute pulmonary embolism. *Eur Heart J.* 2014;35:3033-69.
26. King SB 3rd, Smith SC Jr, Hirshfeld JW Jr, Jacobs AK, Morrison DA, Williams DO, Feldman TE, Kern MJ, O'Neill WW, Schaff HV, Whitlow PL; ACC/AHA/SCAI, Adams CD, Anderson JL, Buller CE, Creager MA, Ettinger SM, Halperin JL, Hunt SA, Krumholz HM, Kushner FG, Lytle BW, Nishimura R, Page RL, Riegel B, Tarkington LG, Yancy CW. 2007 focused update of the ACC/AHA/SCAI 2005 guideline update for percutaneous coronary intervention: a report of the American College of Cardiology/American Heart Association Task Force on Practice Guidelines. *J Am Coll Cardiol.* 2008;51:172-209.
27. Gogas BD, Serruys PW, Diletti R, Farooq V, Brugaletta S, Radu MD, Heo JH, Onuma Y, van Geuns RJ, Regar E, De Bruyne B, Chevalier B, Thuesen L, Smits PC, Dudek D, Koolen J, Windecker S, Whitbourn R, Miquel-Hebert K, Dorange C, Rapoza R, Garcia-Garcia HM, McClean D, Ormiston JA. Vascular response of the segments adjacent to the proximal and distal edges of the ABSORB everolimus-eluting bioresorbable vascular scaffold: 6-month and 1-year follow-up assessment: a virtual histology intravascular ultrasound study from the first-in-man ABSORB cohort B trial. *JACC Cardiovasc Interv.* 2012;5:656-65.
28. Farooq V, Onuma Y, Radu M, Okamura T, Gomez-Lara J, Brugaletta S, Gogas BD, van Geuns RJ, Regar E, Schultz C, Windecker S, Lefèvre T, Brueren BR, Powers J, Perkins LL, Rapoza RJ, Virmani R, Garcia-Garcia HM, Serruys PW. Optical coherence tomography (OCT) of overlapping bioresorbable scaffolds: from benchwork to clinical application. *EuroIntervention.* 2011;7:386-99.
29. Onuma Y, Serruys PW. Bioresorbable scaffold: the advent of a new era in percutaneous coronary and peripheral revascularization? *Circulation.* 2011;123:779-97.
30. Ishibashi Y, Onuma Y, Muramatsu T, Nakatani S, Iqbal J, Garcia-Garcia HM, Bartorelli AL, Whitbourn R, Abizaid A, Serruys PW; ABSORB EXTEND Investigators. Lessons learned from acute and late scaffold failures in the ABSORB EXTEND trial. *EuroIntervention.* 2014;10:449-57.
31. Onuma Y, Dudek D, Thuesen L, Webster M, Nieman K, Garcia-Garcia HM, Ormiston JA, Serruys PW. Five-year clinical and functional multislice computed tomography angiographic results after coronary implantation of the fully resorbable polymeric everolimus-eluting scaffold in patients with de novo coronary artery disease: the ABSORB cohort A trial. *JACC Cardiovasc Interv.* 2013;6:999-1009.
32. Serruys PW, Ormiston JA, Onuma Y, Regar E, Gonzalo N, Garcia-Garcia HM, Nieman K, Bruining N, Dorange C, Miquel-Hébert K, Veldhof S, Webster M, Thuesen L, Dudek D. A bioabsorbable everolimus-eluting coronary stent system (ABSORB): 2-year outcomes and results from multiple imaging methods. *Lancet.* 2009;373:897-910.
33. Ielasi A, Cortese B, Varricchio A, Tespili M, Sesana M, Pisano F, Loi B, Granata F, Moscarella E, Silva Orrego P, La Vecchia L, Steffenino G. Immediate and midterm outcomes following primary PCI with bioresorbable vascular scaffold implantation in patients with ST-segment myocardial infarction: insights from the multicentre "Registro ABSORB Italiano" (RAI registry). *EuroIntervention.* 2014 Oct 30. [Epub ahead of print].
34. Wöhrle J, Naber C, Schmitz T, Schwencke C, Frey N, Butter C, Brachmann J, Ingwersen M, Drabik A, Markovic S, Mathey DG. Beyond the early stages: insights from the ASSURE registry on bioresorbable vascular scaffolds. *EuroIntervention.* 2014 Dec 16. [Epub ahead of print].
35. Kocka V, Lisa L, Tousek P, Buděšínský T, Lisa L, Prodanov P, Jarkovský J, Widimský P. ST elevation myocardial infarction treated with bioresorbable vascular scaffold: rationale and first cases. *Eur Heart J.* 2013;34:2073.

Online Table 1. Summary of key BVS studies.

| Study title                        | Study type/design   | Number of subjects enrolled (n) | STEMI (%) | Lesion selection  | Follow-up length (months) | Cardiac death (%) | Non-cardiac death (%) | Any MI (%) | Definite or Probable ST (%) | Any TVR (%) | Any TLR (%) |
|------------------------------------|---|---------------------------------|-----------|---|---------------------------|-------------------|-----------------------|------------|-----------------------------|-------------|-------------|
| ABSORB cohort A <sup>31</sup>      | Single-arm, open-label, prospective study with safety and imaging endpoints             | 30                              | 0         | Single <i>de novo</i> lesions; length <14 mm                        | 60                        | 0                 | 6.9                   | 3.0        | 0                           | 10.3        | 3.4         |
| ABSORB cohort B <sup>32</sup>      | Single-arm, open-label, prospective multicentre study with safety and imaging endpoints | 29                              | 0         | Single <i>de novo</i> lesions; length <14 mm                        | 24                        | 0                 | 0                     | 0          | 0                           | --          | --          |
| ABSORB II (BVS group) <sup>3</sup> | Randomised 2:1 (BVS vs. XIENCE)   | 335                             | 0         | Up to 2 <i>de novo</i> lesions; lesion length ≤48 mm                | 12                        | 0                 | 0                     | 1.2        | 0.3                         | NA          | 1.2         |
| ABSORB EXTEND <sup>5</sup>         | Prospective, multicentre, continued access trial  | 512                             | 0         | Up to 2 <i>de novo</i> lesions; lesion length ≤28 mm                | 12                        | 0.4               | --                    | 2.9        | 0.8                         | 4.9         | 4.3         |
| AMC PCI registry <sup>20</sup>     | Single-centre real-world registry   | 134                             | 13.0      | Lesion selection at operator's discretion                           | 6                         | 0.8               | --                    | 3.0        | 3.0                         | 8.5         | 6.3         |
| GHOST EU registry <sup>4</sup>     | Retrospective multicentre registry  | 1,189                           | 16.1      | Lesion selection at operator's discretion                           | 6                         | 1.0               | 0.3                   | 2.0        | 2.1                         | 4.0         | 2.5         |
| RAI registry <sup>33</sup>         | Ongoing, multicentre prospective registry   | 74                              | 100       | Lesion selection at operator's discretion                           | 6                         | 0                 | 0                     | 2.7        | 1.3                         | 0           | 4.1         |
| ASSURE registry <sup>34</sup>      | Prospective, observational registry   | 183                             | 27        | Lesion length <28 mm; vessel diameter ≥2 mm and ≤3.3 mm             | 12                        | 0                 | 0.1                   | 1.6        | --                          | --          | 2.8         |
| EXPAND (PCR 2014)                  | Prospective, real-world, single-centre registry   | 200                             | 0         | Lesion selection at operator's discretion                           | 6                         | 1.5               | 0.5                   | 1.7        | 2.2                         | 2.2         | 2.2         |
| BVS STEMI First <sup>12</sup>      | Prospective, single-arm, single-centre, intention-to-treat study                        | 49                              | 100       | Lesion selection at operator's discretion                           | 1                         | 0                 | 0                     | 2.0        | 0                           | 0           | 0           |
| Prague 19 <sup>35</sup>            | Prospective, multicentre, open-label study  | 41                              | 100       | Lesion length <24 mm; infarct-related reference diameter 2.3-3.7 mm | 9                         | 0                 | 0                     | 2.4        | 2.4                         | --          | --          |
| Gori et al <sup>11</sup>           | Prospective, single-centre Consecutive ACS patients                                     | 150                             | 44        | Lesion selection at operator's discretion                           | 1                         | 1.4               | 0                     | 4.0        | 2.6                         | --          | --          |

ST: stent thrombosis; STEMI: ST-elevation myocardial infarction; TLR: target lesion revascularisation; TVR: target vessel revascularisation

**Online Table 2. Survey results - Patient selection.**

| Question  |                  | Percentage |
|---|------------------|------------|
| In your BVS series, what is the proportion of patients with STEMI?  | 1) <30           | 79%        |
|   | 2) 30-60         | 21%        |
|   | 3) >60           | 0%         |
| In your BVS series, what is the proportion of patients with NSTEMI-ACS?   | 1) <30           | 64%        |
|   | 2) 30-60         | 29%        |
|   | 3) >60           | 7%         |
| In your BVS series, what is the proportion of patients with stable angina?  | 1) <30           | 36%        |
|   | 2) 30-60         | 36%        |
|   | 3) >60           | 29%        |
| In your BVS series, what is the proportion of patients with single-vessel coronary artery disease?                | 1) <30           | 21%        |
|   | 2) 30-60         | 71%        |
|   | 3) >60           | 9%         |
| In your BVS series, what is the proportion of patients with more than one BVS implanted during the index PCI?     | 1) <60           | 86%        |
|   | 2) 60-80         | 14%        |
|   | 3) >80           | 0%         |
| In your BVS series, what is the proportion of patients with DES implanted additional to BVS during the index PCI? | 1) <60           | 93%        |
|   | 2) 60-80         | 7%         |
|   | 3) >80           | 0%         |
| Which is the most frequent reason for choosing BVS in your centre? (multiple answers allowed)                     | 1) Young patient | 86%        |
|   | 2) Distal lesion | 21%        |
|   | 3) CTO lesion    | 14%        |
|   | 4) Diabetes      | 14%        |
|   | 5) Long lesions  | 50%        |
|   | 6) Others        | 7%         |

**Online Table 3. Survey results - Vessel sizing and scaffold size selection.**

| Question  |                              | Percentage |
|---|------------------------------|------------|
| Do you routinely use intracoronary nitroglycerine before sizing?          | 1) Yes                       | 93%        |
|   | 2) No                        | 7%         |
| Do you routinely size your vessel with balloons?                          | 1) Yes                       | 71%        |
|   | 2) No                        | 29%        |
| Do you routinely use quantitative coronary angiography for vessel sizing? | 1) Yes                       | 14%        |
|   | 2) No                        | 86%        |
| Do you routinely use intravascular imaging for sizing?                    | 1) Yes, IVUS                 | 0%         |
|   | 2) Yes, OCT                  | 14%        |
|   | 3) Yes, both                 | 0%         |
|   | 4) No                        | 86%        |
| Which vessel reference do you use? (multiple answers allowed)             | 1) Proximal D <sub>max</sub> | 64%        |
|   | 2) Distal D <sub>max</sub>   | 9%         |
|   | 3) Interpolated              | 36%        |

**Online Table 4. Survey results - Lesion preparation.**

| Question   |  | Percentage |
|--|--|------------|
| How frequently do you perform predilatation before BVS implantation?                           | 1) <30% of the cases   | 0%         |
|  | 2) 30%-60% of the cases  | 14%        |
|  | 3) 60%-90% of the cases  | 14%        |
|  | 4) >90% of the cases   | 71%        |
| How frequently do you perform direct BVS implantation in acute coronary syndromes?             | 1) <30% of the cases   | 86%        |
|  | 2) 30%-60% of the cases  | 0%         |
|  | 3) 60%-90% of the cases  | 14%        |
|  | 4) >90% of the cases   | 0%         |
| What is your first choice balloon for predilatation before BVS implantation?                   | 1) semi-compliant  | 50%        |
|  | 2) non-compliant   | 50%        |
|  | 3) scoring balloon   | 0%         |
| How frequently do you use scoring or cutting balloons before BVS implantation?                 | 1) <30% of the cases   | 93%        |
|  | 2) 30%-60% of the cases  | 7%         |
|  | 3) 60%-90% of the cases  | 0%         |
|  | 4) >90% of the cases   | 0%         |
| How frequently do you use rotational atherectomy before BVS implantation?                      | 1) <30% of the cases   | 100%       |
|  | 2) 30%-60% of the cases  | 0%         |
|  | 3) 60%-90% of the cases  | 0%         |
|  | 4) >90% of the cases   | 0%         |
| What is your goal after predilatation?   | 1) <20% residual stenosis  | 14%        |
|  | 2) <40% residual stenosis  | 14%        |
|  | 3) No goal as long as the predilatation balloon fully open with no indentation | 71%        |
| Do you routinely use intravascular imaging to decide whether specific preparation is required? | 1) Yes   | 7%         |
|  | 2) No  | 93%        |

**Online Table 5. Survey results - Crossing the lesion.**

| Question  |           | Percentage |
|---|-----------|------------|
| How frequently have you used buddy wires to implant BVS?                            | 1) <10%   | 71%        |
|   | 2) 11-30% | 21%        |
|   | 3) 31-60% | 7%         |
|   | 4) >60%   | 0%         |
| How frequently have you used mother-and-child catheters or similar to implant BVS?  | 1) <10%   | 100%       |
|   | 2) 11-30% | 0%         |
|   | 3) 31-60% | 0%         |
|   | 4) >60%   | 0%         |
| How frequently have you implanted a BVS at a second attempt, after initial failure? | 5) 0%     | 0%         |
|   | 6) <5%    | 50%        |
|   | 7) 6-10%  | 29%        |
|   | 8) 11-30% | 21%        |
|   | 9) >30%   | 0%         |
| How frequently have you discarded a BVS due to failure in crossing the lesion?      | 1) 0%     | 14%        |
|   | 2) <5%    | 64%        |
|   | 3) 6-10%  | 14%        |
|   | 4) 11-30% | 7%         |
|   | 5) >30%   | 0%         |



**Online Table 6. Survey results - Scaffold implantation.**

| Question   |  | Percentage |
|--|--|------------|
| Do you follow the general rule of inflating 2 atm every 5 seconds?   | 1) Yes   | 93%        |
|  | 2) No  | 7%         |
| Do you generally stay within the nominal size?   | 1) Yes   | 57%        |
|  | 2) No  | 43%        |
| How long do you keep the balloon inflated?   | 1) <30 seconds   | 21%        |
|  | 2) 30 seconds  | 50%        |
|  | 3) 60 seconds  | 29%        |
| What is your typical BVS balloon implantation pressure?  | 1) <10 atm   | 14%        |
|  | 2) 11-12 atm   | 21%        |
|  | 3) 13-14 atm   | 21%        |
|  | 4) 15-16 atm   | 29%        |
|  | 5) >16 atm   | 14%        |
| What is your overlap technique?  | 1) Marker-to-marker  | 43%        |
|  | 2) Marker-over-marker  | 14%        |
|  | 3) Scaffold-to-scaffold  | 43%        |
| What is your approach to bifurcations with BVS in 1,1,0 or 1,0,0 or 0,1,0 lesions? (multiple answers allowed)  | 1) One BVS in the MV and nothing more                                  | 79%        |
|  | 2) One BVS in the MV and fenestrate towards SB                         | 14%        |
|  | 3) One BVS in the MV, fenestrate only when SB TIMI flow <3, or DS >75% | 7%         |
| What is your approach to bifurcations with BVS in 1,1,1 or 1,0,1 or 0,1,1 lesions? (multiple answers allowed)  | 1) One BVS in the MV and a DES in the SB                               | 29%        |
|  | 2) One BVS in the MV and a BVS in the SB with T or TAP                 | 50%        |
|  | 3) One BVS in the MV and a BVS in the SB with mini-crush or culotte    | 0%         |
|  | 4) One BVS in the MV and balloon dilation in the SB                    | 14%        |
|  | 5) No BVS  | 21%        |
| In a long lesion involving bifurcation, how frequently do you use hybrid stenting (DES in the bifurcation, BVS distal or proximal)? (multiple answers allowed) | 1) <30% of the cases   | 79%        |
|  | 2) 30%-60% of the cases  | 14%        |
|  | 3) 60%-90% of the cases  | 0%         |
|  | 4) >90% of the cases   | 7%         |

**Online Table 7. Survey results - Scaffold optimisation.**

| Question   |                            | Percentage |
|--|----------------------------|------------|
| How frequently do you post-dilate the scaffold?          | 1) <30% of the cases       | 0%         |
|  | 2) 30%-60% of the cases    | 14%        |
|  | 3) 60%-90% of the cases    | 21%        |
|  | 4) >90% of the cases       | 64%        |
| Which is the size of the post-dilatation balloon?        | 1) Same size as BVS        | 29%        |
|  | 2) 0.25 mm larger than BVS | 14%        |
|  | 3) 0.5 mm larger than BVS  | 57%        |
|  | 4) 1 mm larger than BVS    | 0%         |
| What is the typical post-dilation balloon pressure?      | 1) <10 atm                 | 0%         |
|  | 2) 11-12 atm               | 0%         |
|  | 3) 13-14 atm               | 21%        |
|  | 4) 15-16 atm               | 29%        |
|  | 5) >16 atm                 | 50%        |
| How long do you keep the post-dilation balloon inflated? | 1) <15 seconds             | 29%        |
|  | 2) 10-30 seconds           | 71%        |
|  | 3) 31-60 seconds           | 0%         |
| What is your goal after scaffold implantation?           | 1) <10% residual stenosis  | 86%        |
|  | 2) <30% residual stenosis  | 14%        |
|  | 3) <50% residual stenosis  | 0%         |

**Online Table 8. Survey results - Adjunctive antithrombotic therapy.**

| Question   |   | Percentage |
|--|---|------------|
| During BVS implantation, how frequently do you use glycoprotein IIb/IIIa inhibitors?                   | 1) as frequently as with DES  | 93%        |
|  | 2) more frequently than with DES  | 7%         |
| Do you perform platelet function testing after BVS implantation?                                       | 1) No   | 79%        |
|  | 2) Yes, routinely in patients on clopidogrel                                  | 21%        |
|  | 3) Yes, selectively in case of demanding BVS implantation                     | 0%         |
| How long do you recommend dual antiplatelet therapy in stable angina patients treated with BVS?        | 1) 6 months   | 14%        |
|  | 2) 12 months  | 79%        |
|  | 3) >12 months   | 7%         |
| How long do you recommend dual antiplatelet therapy in NSTEMI-ACS and STEMI patients treated with BVS? | 1) 6 months   | 0%         |
|  | 2) 12 months  | 86%        |
|  | 3) >12 months   | 14%        |
| Which drug do you recommend in patients treated with BVS?  | 1) Always clopidogrel   | 0%         |
|  | 2) Prasugrel or ticagrelor only if NSTEMI-ACS or STEMI, otherwise clopidogrel | 50%        |
|  | 3) Prasugrel or ticagrelor regardless of clinical presentation                | 50%        |

**Online Table 9. Survey results – Follow-up and complications management.**

| Question  | Percentage   |     |
|---|--|-----|
| Do you perform routine follow-up coronary angiography after BVS implantation?   | 1) no  | 91% |
|   | 2) at 6-8 months   | 9%  |
|   | 3) at 1 year   | 0%  |
|   | 4) at 2 years  | 0%  |
| Do you perform routine intracoronary imaging at follow-up coronary angiography? | 1) No  | 27% |
|   | 2) Yes   | 18% |
|   | 3) Only in selected cases                                  | 55% |
| How do you treat scaffold thrombosis? (multiple answers allowed)                | 1) Plain balloon angioplasty with or without thrombectomy  | 55% |
|   | 2) Preferential DES implantation                           | 73% |
|   | 3) DES implantation in case of OCT-determined BVS fracture | 36% |
|   | 4) New BVS implantation                                    | 9%  |
| How do you treat scaffold restenosis? (multiple answers allowed)                | 1) Plain balloon angioplasty                               | 9%  |
|   | 2) Drug-coated balloon                                     | 18% |
|   | 3) Preferential DES implantation                           | 91% |
|   | 4) DES implantation in case of OCT-determined BVS fracture | 27% |
|   | 5) New BVS implantation                                    | 9%  |

**Online Table 10. Scaffold selection based on vessel sizing by quantitative coronary angiography.**

| Target vessel diameter | BVS size to be used |
|------------------------|---------------------|
| ≥2.0 mm and ≤3.0 mm    | 2.5 mm              |
| ≥2.5 mm and ≤3.3* mm   | 3.0 mm              |
| ≥3.0 mm and ≤3.8* mm   | 3.5 mm              |

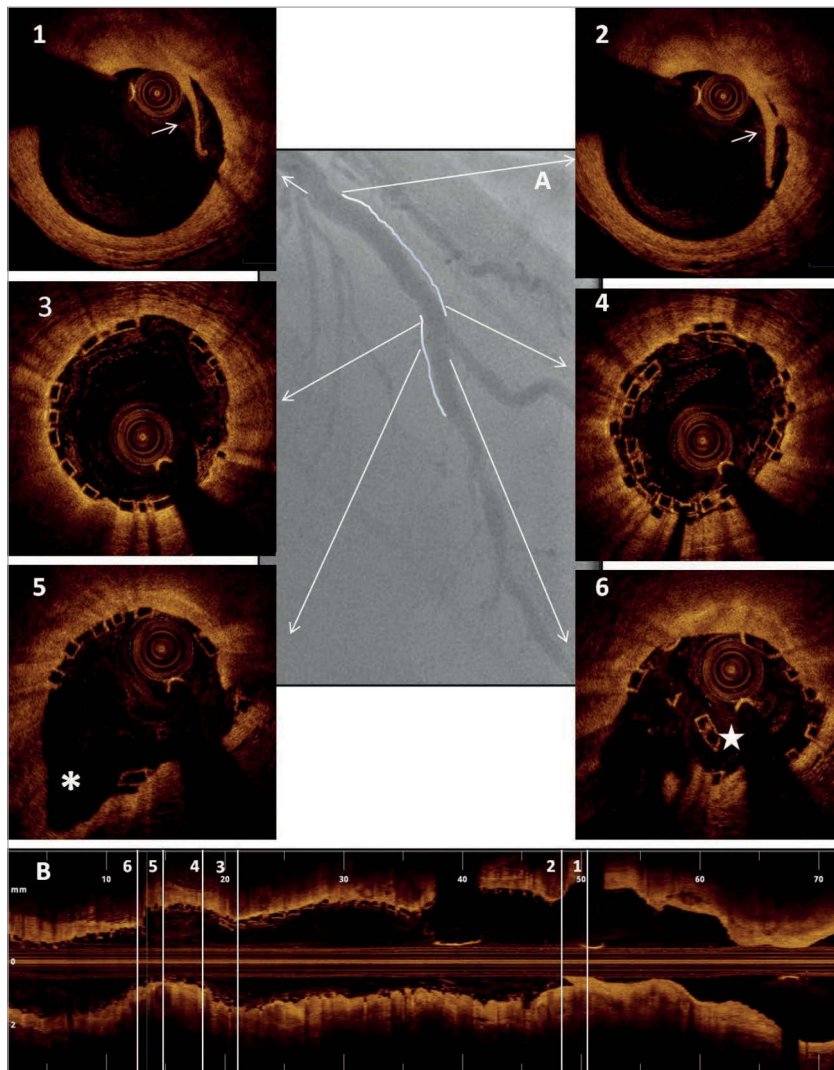
\*Allows for 1.1:1 scaffold:artery sizing without exceeding expansion limit.

**Online Table 11. Step-by-step guidance on lesion preparation.**

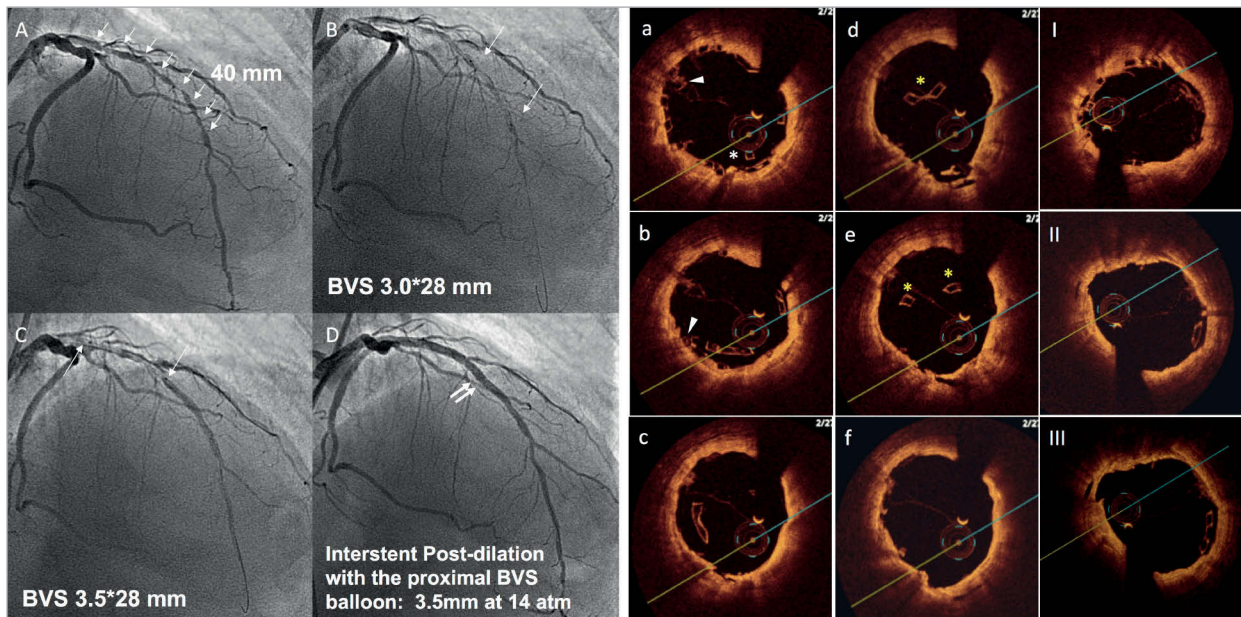
- Start dilating the lesion with a semi- or non-compliant balloon of the same diameter or no more than 0.5 mm smaller than the selected scaffold. The aim of lesion preparation is to obtain visible expansion of the balloon matching the size of the reference vessel with no indentations in two orthogonal angiographic planes.
- In case of focal balloon underexpansion, short (6-12 mm length) high-pressure non-compliant balloons with the same diameter should be selected (max 1.1:1 for non-compliant allowed).
- In case of unsatisfactory result after the steps above, intravascular imaging should be considered to guide further specific preparation with cutting balloons, scoring balloons or rotational atherectomy.
- In the event that the full expansion of the predilatation balloon is not possible after lesion preparation, it is advised not to implant a BVS.

**Online Table 12. Current limitations of the Absorb bioresorbable vascular scaffold.**

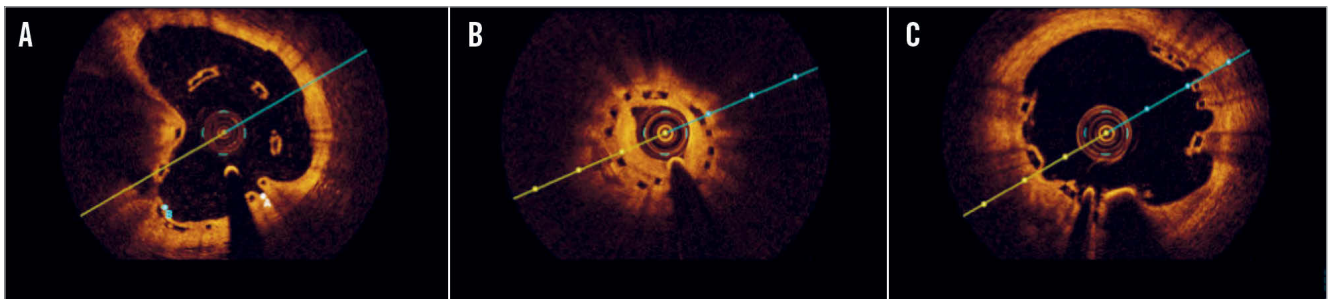
- Limitations in the current spectrum of available diameters.
- Less flexibility to be adapted to a wide range of diameters by aggressive post-dilatation than a typical metal stent.
- The limited radial strength may limit the use in severely calcified stenoses and ostial lesions.
- Restrictions in terms of positioning in aorto-ostial lesions (i.e., it is not possible to “flare” the scaffold by strong overexpansion of the short segment that extends into the aortic lumen).
- Neither two scaffolds, nor a scaffold and a balloon can be simultaneously advanced through a 6 Fr guiding catheter.
- The use of mother-and-child catheters is more complex.
- Difficulties to advance the scaffold and the strict need for lesion preparation and post-dilatation may prolong procedural as well as fluoroscopy time, effort, and, to some extent, the volume of required contrast agent.
- Lack of strut visibility on x-ray imaging may make it difficult to visualise the scaffold in very obese patients and to verify correct expansion, so that additional intravascular imaging or stent enhancement can become necessary.
- In a very small number of patients, haemodynamic compromise may result from the need for relatively long balloon inflation during implantation (i.e., patients in cardiogenic shock or interventions on a “last remaining vessel”).
- Recommendation for long-term dual antiplatelet therapy until specific data are available.



**Online Figure 1.** Scaffold optimisation with optical coherence tomography. Case example. *A) Final angiographic result following two BVS (3.0\*28 mm proximally and 2.5\*18 mm distally) implantation on the mid left anterior descending across the origin of a diagonal branch. B) Longitudinal optical coherence tomography image following optimisation with side branch dilatation with a 2.0 mm semi-compliant balloon (8 atm) and final post-dilatation with a 3.5 mm non-compliant balloon (16 atm) proximally to the bifurcation (sequential dilatation with final proximal optimisation technique). Panels 1 & 2: limited proximal edge dissection (arrows). Panel 3: optimal strut apposition immediately proximal to the overlap. Panel 4: short struts overlap. Panel 5: well-opened scaffold struts at the bifurcation site towards the side branch (\*). Panel 6: scaffold distortion distally to the carina (star).*



**Online Figure 2.** Scaffold disruption. Case example. A patient with a long diffuse lesion, treated with two long BVS and disruption of the proximal segment of the distal BVS. This complication occurred after dilation of the inter BVS coronary segment with a balloon size above that of the manufacturer's recommendations (panels A to D). The diagnosis of the complication was made with OCT criteria (panels a to f) based on the presence of struts protruding into the centre of the lumen (\*), overlapped struts (arrow), and struts not orientated perpendicular to the light source (yellow \*). Prolonged inflation with a non-compliant balloon of a diameter within the expansion limits of the device resolved the complication (panels I to III).



**Online Figure 3.** Illustrative case examples of malapposition, restenosis and multiple interstrut hollows by optical coherence tomography cross-sections. A) BVS malapposition at six-month control. The BVS was implanted and post-dilated at high pressure at the end of a complex procedure in a very calcific plaque. B) BVS restenosis 12 months after implantation. The lesion involved a small diagonal branch, and the scaffold appeared to be underexpanded (minimum lumen area 3 mm<sup>2</sup>). C) OCT performed 12 months after BVS implantation on the LAD during a STEMI demonstrating multiple interstrut hollows.