

Catheter-based therapies in acute pulmonary embolism



Jacob Schultz^{1*}, MD; Asger Andersen¹, MD, PhD; Christopher Kabrhel^{2,3}, MD, MPH; Jens Erik Nielsen-Kudsk¹, MD, DMSc

1. Department of Cardiology, Aarhus University Hospital, Aarhus, Denmark; 2. Center for Vascular Emergencies, Massachusetts General Hospital, Boston, MA, USA; 3. Harvard Medical School, Boston, MA, USA

The complete list of references is published online at: http://www.pcronline.com/eurointervention/129th_issue/277

KEYWORDS

- aspiration device
- balloon inflation
- pulmonary embolism
- thrombectomy

Abstract

Aims: We aimed to provide a systematic review of catheter-based therapies in acute pulmonary embolism (PE).

Methods and results: Studies published in peer-reviewed journals before February 2017 were included and categorised according to the mechanism of thrombus removal: fragmentation, rheolytic therapy, aspiration or catheter-directed thrombolysis. Strengths, challenges and the level of evidence of each device were evaluated. We found 16 different catheter-based therapies for acute PE, all but one being used off-label. The majority of procedures involve catheter-directed thrombolysis. Aspiration therapy shows promise, but limited data are available. Rheolytic therapy should be used with caution, if at all, due to the high number of associated complications.

Conclusions: Catheter-based therapies show promise as a treatment for acute PE, though evidence is lacking. Further research into the efficacy and safety of devices is needed.

*Corresponding author: Department of Cardiology, Aarhus University Hospital, Palle Juul-Jensens Boulevard 99, 8200 Aarhus, Denmark. E-mail: jacobgschultz@clin.au

Abbreviations

CDT	catheter-directed thrombolysis
PA	pulmonary artery
PAP	pulmonary arterial pressure
PE	pulmonary embolism
PVR	pulmonary vascular resistance
RV	right ventricle
UFH	unfractionated heparin
USAT	ultrasound-assisted catheter-directed thrombolysis

Introduction

Acute pulmonary embolism (PE) is a common disease with an estimated incidence of 95/100,000/year causing more than 500,000 deaths/year in Europe and a similar number in the USA¹. This makes acute PE the third most common cardiovascular cause of death after heart attack and stroke².

The presentation of acute PE may vary from subtle changes in functional capacity to haemodynamic collapse and death depending on the thromboembolic mass obstructing the pulmonary circulation, the associated vasoconstrictor response of the pulmonary arteries (PA), and the ability of the right ventricle (RV) to overcome the acute pressure overload.

Systemic thrombolysis provides a rapid decrease in thrombus burden, unloading of the RV and, theoretically, prevention of acute RV failure, circulatory collapse and death³⁻⁵. Treatment with systemic thrombolysis is associated with an increased risk of major bleeding (13%) and stroke (3%)⁴. In high-risk PE patients, the beneficial effects of thrombolysis surpass the risk of bleeding⁵. In intermediate-risk patients, however, the beneficial effects of thrombolysis do not balance the bleeding risk⁶. While 1/3 of PE patients have contraindications to thrombolysis, even in patients eligible for thrombolysis up to 2/3 do not receive the treatment³. Surgical embolectomy may be an option for a fraction of these patients. The poor preoperative state together with a high degree of comorbidity, however, make the majority poor candidates for surgery. This leaves a substantial proportion of PE patients undertreated.

Novel catheter-based approaches may provide effective thrombus removal without the risks associated with systemic thrombolytic or surgical treatment⁷. Numerous new techniques have been developed and refined during the last decade. Unfortunately, randomised clinical trials remain rare, so off-label use is common and case series dominate the literature. In this systematic review we provide an overview of all catheter-based therapies available to treat acute PE, outlining the strengths and challenges as well as the evidence behind each device.

Methods

We performed a systematic literature search of the scientific databases PubMed and Embase using both Mesh and free search with the following key words: “pulmonary embolism”, “catheter”, “device”, “catheter-directed”, “catheter-based”, “trans-catheter”. Abstracts were evaluated and studies included if they met the following criteria: (1) studied acute PE, (2) studied catheter-based

therapies. We included both clinical and experimental studies published in peer-reviewed journals before February 2017. No language restrictions were applied. References from review articles, not found by the initial search, were also included. A secondary search was performed combining device names with “pulmonary embolism”. We categorised studies according to the device investigated and the mechanism of thrombus removal: mechanical fragmentation, rheolytic therapy, catheter-directed thrombolysis (CDT) and aspiration (**Figure 1, Figure 2**). All studies were evaluated to determine the strengths and challenges of each device and the evidence supporting its use in acute PE (**Table 1**).

Results

MECHANICAL FRAGMENTATION

Mechanical fragmentation is based on the principle that haemodynamics can be improved by converting a large embolic mass into smaller emboli, which then travel distally to smaller pulmonary vessels (**Figure 1A**). Theoretically, this decreases mechanical obstruction and makes the emboli more accessible for endogenous fibrinolysis. A challenge is that distal embolisation may cause an acute, paradoxical elevation of pulmonary vascular resistance (PVR) and actually increase strain on the RV⁸.

ROTATIONAL PIGTAIL CATHETER®

The rotational pigtail catheter (Cook Medical, Bloomington, IN, USA) was modified by adding a side hole allowing the passage of a guidewire⁹. The guidewire serves as the central axis around

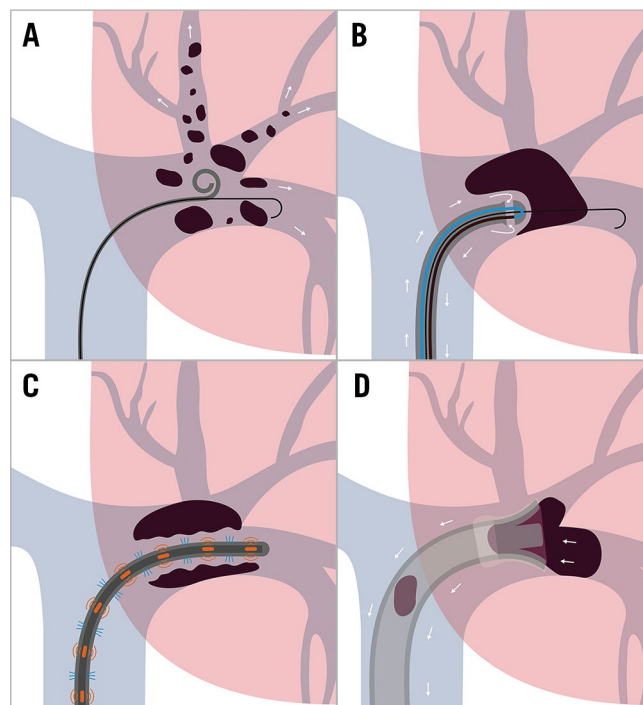


Figure 1. Mechanisms of catheter-based therapies for acute PE. Schematic illustration of the four mechanisms of catheter-directed therapy for acute PE. A) Fragmentation. B) Rheolytic therapy. C) Catheter-directed thrombolysis. D) Aspiration.

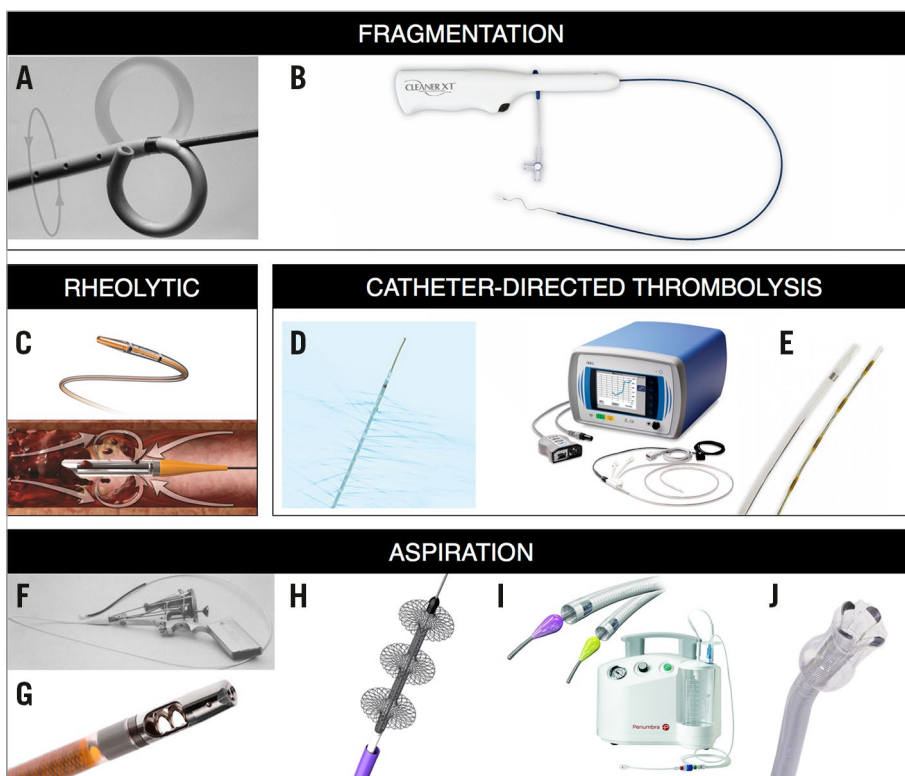


Figure 2. Images of catheter-based therapies for acute PE. A) Rotational pigtail catheter. B) CleanerXT. C) AngioJet. D) Uni*Fuse. E) EkoSonic. F) Greenfield. G) AspirexS. H) FlowTrievers. I) Indigo. J) AngioVac. The manufacturers and copyright holders of all devices mentioned in this article, except Edwards Lifesciences (Fogarty catheter), have given permission to reproduce the images of their devices.

which the pigtail catheter can be rotated manually thereby fragmenting the embolus. Studies have shown successful recanalisation and decreased pulmonary artery pressures (PAP) and shock index^{7,9-14}. The strategy is cost-effective, easy to insert and is readily available in most centres, making it one of the most commonly used catheter-based therapies for acute PE⁷.

FOGARTY ARTERIAL BALLOON EMBOLECTOMY CATHETER®

The Fogarty arterial balloon embolectomy catheter (Edwards Lifesciences, Irvine, CA, USA) is placed in the embolus and the balloon is inflated, leading to recanalisation of the PA^{15,16}. To minimise the risk of PA rupture, an undersized balloon is recommended. However, concerns regarding residual thrombus and distal embolisation remain, which is why balloon angioplasty should generally be combined with either aspiration or CDT.

CLEANER™

The Cleaner rotational thrombectomy system (Rex Medical, Conshohocken, PA, USA) is placed in the thrombus and the flexible sinusoid tip can be deployed and rotated by a battery-driven motor. The catheter is then slowly withdrawn and removed through the sheath. The design may, however, have a few challenges. Introducing without a guidewire could pose a risk of vessel perforation. Furthermore, it is uncertain whether aspiration of thrombus through the small sheath is effective as it causes a risk of distal fragmentation. Only one case has been reported using the Cleaner off-label in a patient with PE¹⁷.

RHEOLYTIC THERAPY

Rheolytic catheters have a small lumen that takes a hairpin loop at the tip of the catheter. Through this lumen, an agent, usually heparinised saline, is injected at a high flow rate into a larger exhaust lumen, creating a vortex. When passing the catheter through a thrombus, the vacuum created by the Venturi effect may disrupt and aspirate thrombus (**Figure 1B**).

ANGIOJET®

The AngioJet (Boston Scientific, Marlborough, MA, USA) is a rheolytic catheter designed for thrombus removal in peripheral vessels. Case reports describe decreased thrombus burden and shock index¹⁸⁻²³. Bradyarrhythmia, haemoglobinuria, renal insufficiency, haemoptysis, haemorrhages and procedure-related deaths have been reported^{24,25}. The FDA has therefore labelled the AngioJet with a black box warning for use in the pulmonary circulation. Despite this, it is still being used in some European centres²⁶. A temporary pacemaker and close monitoring of haemodynamics, renal function and electrolyte status are however pivotal.

CATHETER-DIRECTED THROMBOLYSIS

CDT involves direct delivery of a low-dose thrombolytic drug into the PA at the site of the thrombus (**Figure 1C**). Due to altered flow patterns, it is important that the thrombolytic agent is injected inside the thrombus or that the thrombus is fragmented before injection²⁷. The majority of published case

Table 1. Advantages and challenges of catheter-based therapies.

Device	Advantages	Challenges	Evidence
Thrombus fragmentation			
Pigtail catheter (Cook Medical Inc., Bloomington, IN, USA)	Cost-effective. Easy to insert. Fast recanalisation.	No aspiration. Risk of distal embolisation. Adjuvant thrombolysis and/or aspiration needed.	Successful thrombus fragmentation in case reports ⁷⁻¹⁴ . No RCT.
Fogarty balloon catheter (Edwards Lifesciences, Irvine, CA, USA)	Cost-effective. Easy to insert. Fast recanalisation.	No aspiration. Risk of distal embolisation. Adjuvant thrombolysis and/or aspiration may be needed. Risk of PA rupture.	Not widely used. Few case reports ^{15,16} . No RCT.
Cleaner (Rex Medical, LP, Conshohocken, PA, USA)	Small size. Single piece.	No guidewire. Risk of perforation. Risk of distal embolisation. Aspiration may be limited.	One successful case ¹⁷ . No RCT.
Helix clot buster (ev3/Covidien, Plymouth, MN, USA)	Effective thrombus fragmentation.	No guidewire. Risk of perforation. No aspiration. Risk of distal embolisation.	Case series report beneficial angiographic results, but no improvement in RV function ^{3,44-46} . No RCT.*
Rheolytic therapy			
AngioJet (Boston Scientific, Marlborough, MA, USA)	Easily inserted over the wire. Effective thrombus removal. Fragmentation and aspiration. No need for thrombolysis.	Risk of bradyarrhythmia, haemoglobinuria, renal insufficiency, haemoptysis, and haemorrhages.	Decreased thrombus burden and improved RV function in case reports ^{18-23,26} . Several complications ^{24,25} . No RCT. FDA black box label.
Hydrolyser (Cordis, Miami Lakes, FL, USA)	Small device. Easily inserted over the wire. Fragmentation and aspiration. No need for thrombolysis.	Insufficient data on safety.	Small case series reporting beneficial effect ⁴⁷⁻⁵⁰ . No RCT.*
Oasis (Boston Scientific, Marlborough, MA, USA)	Small device. Easily inserted over the wire. Fragmentation and aspiration. No need for thrombolysis.	Insufficient data on safety.	Few clinical data ⁴⁷ . Beneficial in experimental models ¹⁸ . No RCT.*
Catheter-directed thrombolysis			
Modern infusion catheters	Easy to place. Cost-effective. Effective thrombus removal. Low dosage of thrombolysis.	Adjuvant fragmentation may be needed ²⁷ . Optimal infusion regimen to be determined.	Improved RV function in case series and prospective registries ^{7,12,14,27-30} . Insufficient data on bleeding risks and no long-term follow-up. No RCT.
EkoSonic (BTG, Bothell, WA, USA)	Easy to place. Effective thrombus removal. Low dosage of thrombolysis.	Adjuvant fragmentation may be needed ²⁷ . Optimal infusion regimen to be determined.	Approved by the FDA. Superior to UFH with no increased bleeding in an RCT ³¹ . Total number of patients low. No long-term follow-up with clinical endpoints ^{32,43} . The additive effect of ultrasound has not been validated ^{14,33} .
Aspiration thrombectomy			
Greenfield catheter (Boston Scientific, Marlborough, MA, USA)	Removes thrombus en bloc. Minimal distal fragmentation. No thrombolysis needed.	Inserted via venotomy. No guidewire. Challenging manoeuvrability. Risk of blood loss.	First catheter for pulmonary embolectomy ³⁵ . Beneficial in patient series ³⁶ . No RCT.
AspirexS (Straub Medical, Wangs, Switzerland)	Easy to insert over the wire. Fragmentation and aspiration. No thrombolysis needed. Blunt tip minimises risk of perforation.	Possibly only effective in fresh thrombi. Risk of blood loss.	Case reports indicate safety and efficacy ³⁷ . No RCT.
RotarexS (Straub Medical, Wangs, Switzerland)	Easy to insert over the wire. Fragmentation and aspiration. No thrombolysis needed. A faceted rotating tip increases fragmentation.	Risk of haemolysis, perforation and blood loss.	Case reports indicate safety and efficacy ³⁸ . No RCT.
FlowTriever (Inari Medical, Irvine, CA, USA)	Aspiration of thrombus with minimal blood loss. No thrombolysis needed.	Large device. Challenging manoeuvrability. Aspiration may be limited. Adjuvant therapy may be needed.	Few cases report successful thrombus removal and improved RV function ^{39,40} . No RCT. A prospective, multicentre, single-arm study is enrolling 150 patients (FLARE, NCT02692586).
Indigo (Penumbra, Inc., Alameda, CA, USA)	Small device. Easy to insert over the wire. Aspiration of thrombus. No thrombolysis needed.	Aspiration may be limited. Possibly only effective in fresh thrombi. Risk of blood loss.	A single patient case report ⁴¹ . No RCT.
AngioVac (AngioDynamics, Latham, NY, USA)	Aspiration of large organised thrombus. No blood loss. No thrombolysis needed.	Large and bulky. Challenging manoeuvrability. A perfusionist is needed.	Few patient case reports. Challenging manoeuvring and risk of perforation have been reported ⁴² . No RCT.
* Not available for purchase at the time of publication. FDA: Food and Drug Administration; PA: pulmonary artery; RCT: randomised controlled trial; RV: right ventricle; UFH: unfractionated heparin			

reports describe CDT combined with some degree of fragmentation, most frequently using the pigtail catheter (69%)^{7,12,28,29}. Thrombolysis may be administered by standard infusion catheters, or by newly designed catheters such as the Uni*Fuse™ or Pulse*Spray® (both AngioDynamics, Latham, NY, USA) which have special side holes for optimal intra-thrombus drug delivery. Dosing regimens vary between centres and may involve infusion of 0.5-1.0 mg/h alteplase in one or both main PA for up to 24 hours. The total dosage is typically kept under 30 mg, significantly lower than the systemic dose of 100 mg.

A recent prospective multicentre registry of patients with intermediate- and high-risk PE found that CDT improved haemodynamics in most cases without major bleeding¹⁴, but the findings were not reproduced in a larger retrospective study³⁰.

ULTRASOUND-ASSISTED CATHETER-DIRECTED THROMBOLYSIS

Ultrasound-assisted catheter-directed thrombolysis (USAT) uses ultrasonic waves purportedly to disrupt the fibrin structure of the thrombus, allowing more binding sites for the thrombolytic agent.

The EkoSonic® Endovascular System (BTG, Bothell, WA, USA) is the only device evaluated in a randomised controlled trial. The ULTIMA trial randomised 59 patients with intermediate-risk PE to unfractionated heparin (UFH) plus a low-dose USAT infusion of alteplase for 15 hours or UFH alone³¹. This study found USAT to be superior to UFH alone in reducing RV/LV ratio after 24 hours with no increase in bleeding complications. However, at the 90-day follow-up, the RV/LV ratio was equalised between the two groups. These findings were supported by the SEATTLE II study³², a prospective, multicentre, single-arm trial of 150 intermediate- and high-risk patients. The study found that USAT was associated with decreased RV dilatation, PAP and Miller index and a low rate of bleeding complications. A randomised trial (SUNSET SPE, NCT02758574) will investigate whether ultrasound improves outcome compared to non-ultrasound-assisted CDT, which is currently unknown. In patients suffering from deep vein thrombosis, there are no additional beneficial effects of USAT³³.

The EkoSonic is currently the only device with an FDA approval for treatment of acute PE³⁴. A randomised trial aiming to determine the optimal dose and time of infusion has just been completed (OPTALYSE PE, NCT02396758). Results are pending, but presentations suggest improvement of RV function with as low as 4 mg infusion over 2 hrs.

ASPIRATION

The goal of aspiration thrombectomy is to decrease thrombus burden without distal embolisation (**Figure 1D**).

THE GREENFIELD SUCTION CATHETER®

Developed in 1969, the Greenfield suction catheter (Boston Scientific) has a plastic cup at its tip³⁵. By advancing the cup into the PA and manually applying suction with a syringe, the cup can attach to a centrally located thrombus and the thrombus can be removed *en bloc* with minimal distal embolisation. The device is inserted by a surgical venotomy as insertion is not

possible through conventional sheath access. The stiff cup with a 7 mm diameter is difficult to manoeuvre in the PA, especially as it is not compatible with a guidewire. Despite reports of a success rate of 76%³⁶, the catheter has not achieved broad use in clinical practice.

ASPIREX®S AND ROTAREX®S

The AspirexS and RotarexS (Straub Medical, Wangs, Switzerland) have a metal helix that can be rotated inside the catheter to create a vacuum at the tip of the catheter based on the principle of Archimedes' screw. Thrombus material is thus pulled towards the tip, fragmented and transported via side holes through the catheter. The tip of the AspirexS is fixed and blunt, so fragmentation is limited. The device is therefore only indicated for use with fresh thrombus. The tip of the RotarexS is faceted and rotates together with the helix which enables fragmentation of more rigid thrombus material, but with a risk of damaging the vessel. Both catheters have been used off-label for PE^{37,38}. A drawback of the devices is the potential for large-volume blood loss (130 ml/min with the largest catheter).

FLOWTRIEVER™

The FlowTrieve system (Inari Medical, Irvine, CA, USA) consists of an aspiration catheter and a flow restoration catheter. The aspiration catheter is advanced into the thrombus. The flow restoration catheter is then advanced through the aspiration catheter and three self-expanding nitinol wire discs are deployed into the thrombus. Thrombus is caught in and between the discs, allowing aspiration by retracting the catheter. Challenges may be limited thrombus removal and manoeuvrability. A few patient cases have demonstrated successful thrombus removal without adverse effects^{39,40}. A prospective, multicentre, single-arm study is now enrolling patients. The FlowTrieve Pulmonary Embolectomy Clinical Study (FLARE) aims to evaluate the safety and effectiveness of the FlowTrieve in 150 patients with acute PE from 20 sites in the USA (clinicaltrials.gov, NCT02692586).

INDIGO®

The Indigo mechanical thrombectomy system (Penumbra, Inc., Alameda, CA, USA) consists of an aspiration catheter, a pump providing suction and a separator wire. When the aspiration catheter is located at the thrombus, the pump creates a vacuum to aspirate thrombus. The catheter can be advanced through the thrombus repeatedly to allow more thrombus removal. A separator wire can be introduced into the aspiration catheter to clear it of obstructing material. The catheter is available with three different tips ranging from straight to angled to improve manoeuvrability. The small diameter, which makes the system easy to insert and manoeuvre, may also be its limitation as aspiration may be limited. To limit blood loss, it is critical that the pump is turned off when the catheter is outside the thrombus. Only a few cases of PE treatment have been reported with this device⁴¹.

ANGIOVAC®

The AngioVac (AngioDynamics) is a cannula designed for *en bloc* removal of venous thrombi during extracorporeal venous-venous bypass, allowing filtration of aspirated blood from thrombi before

re-introduction to the systemic circulation. The catheter has a tulip-shaped distal tip that can be expanded by a balloon when situated proximal to the thrombus. The size and shape of the catheter allow aspiration of larger thrombi without clotting the catheter. It has been used off-label in small case series of patients with PE with some success⁴². The bulkiness of the system does however make it difficult to manoeuvre and may increase the risk of perforation⁴².

Discussion and limitations

The use of catheter-based therapy for PE is increasing, but the exact number of acute PE patients receiving catheter-based therapy is unknown. In one recent longitudinal report, 9% of patients with acute PE received catheter-based therapy³⁴, but in the majority of hospitals anticoagulation and systemic thrombolysis are the only available treatment options.

We found 16 different catheter-based therapies used in acute PE (Table 1, Figure 2). Prior to 2008, 70% of catheter-based therapies involved mechanical fragmentation by a pigtail catheter⁷. However, with the FDA approval of the EkoSonic, USAT has surpassed mechanical fragmentation as the preferred catheter-based therapy^{34,43}. Rheolytic catheters were used in greater numbers, but with the black box warning from the FDA the current use is limited⁷. Aspiration therapy is promising, but devices are still in the early stages of development and data are lacking. It is worth noting that CDT typically requires more than 12 hours of therapy, which may be too long in high-risk patients, suggesting that aspiration therapy with faster thrombus removal may provide a valid treatment option. Assist devices such as the Impella RP® (Abiomed, Danvers, MA, USA) or ECMO may also have a place in the treatment of high-risk patients by serving as a bridge to other treatment options or endogenous thrombolysis.

European guidelines recommend catheter-based therapies as an alternative treatment in patients with high-risk PE and contraindications to or inadequate effect of systemic thrombolysis (Class IIa, level C). In intermediate-risk patients, catheter-based therapies are recommended in patients with a high bleeding risk (Class IIb, level B), with the ULTIMA trial as the only reference emphasising the lack of evidence.

The literature supporting catheter-based therapies in acute PE is mainly from case reports and retrospective patient series, yielding a risk of publication bias. Furthermore, the patient population in these reports may be highly selected. Therefore, the promising success rates and low complication rates reported should be interpreted with care⁷. The ULTIMA trial is the only randomised controlled trial investigating catheter-based therapies for acute PE³¹. Together with the uncontrolled SEATTLE II study and the prospective PERFECT registry, the totality of prospective data is limited to around 300 patients (Table 2). Furthermore, these studies all investigated the effects of CDT so, while the evidence supporting this approach is growing, evidence for other techniques is sparse.

The high bleeding risk of systemic thrombolysis limits the clinical use to patients at highest risk of early mortality. If large randomised clinical trials prove that novel catheter-directed therapies provide effective reduction in thrombus burden with a complication rate lower than systemic thrombolysis, it could cause a paradigm shift equal to that of acute myocardial infarction and, in time, render systemic thrombolysis obsolete in the treatment of acute PE. The potential of catheter-based therapies might even be greater in intermediate-risk patients. Currently, there is a gap between the high morbidity and mortality of intermediate-risk PE treated with anticoagulation alone, and the lack of overall benefit of systemic thrombolysis in this patient subgroup⁶.

Table 2. Prospective data on catheter-directed therapies in acute pulmonary embolism.

Trial	Therapy	Design	Risk group	Primary endpoints	Results	N
ULTIMA ³¹	USAT+UFH vs. UFH	Randomised controlled trial	Intermediate	Efficacy: Δ RV/LV, baseline to 24 hrs. (Echo)	Δ RV/LV: USAT+UFH: 0.30±0.20 vs. UFH: 0.03±0.16 ($p<0.001$)	59 (53)
				Safety: Death, major and minor bleeding, recurrent VTE at 90 days.	No recurrent VTE or major bleeding at 90 days. 1 death (cancer). 4 minor bleedings (USAT: 3 [10%], UFH: 1 [3%])	
SEATTLE II ³²	USAT	Prospective, single-arm trial	Intermediate + high	Efficacy: Δ RV/LV, baseline to 48 hrs. (CT)	Δ RV/LV: 0.42±0.36 ($p<0.0001$)	150 (115)
				Safety: Major bleeding at 72 hrs.	16 major bleedings (10%).	
PERFECT ¹⁴	CDT/USAT + fragmentation in high risk	Prospective registry	Intermediate + high	Efficacy: Clinical success: sBP >90 mmHg + reduced PAP or RV strain + survival to discharge.	Clinical success: high-risk: 85.7% [67.3-96.0] intermediate-risk: 97.3% [90.5-99.7]	101
				Safety: Major procedure-related complications, major bleeding.	No events.	
Total number of patients						310 (269)
Numbers in parentheses refer to patients with data available on primary efficacy endpoint. CDT: catheter-directed thrombolysis; CT: computed tomography; Δ RV/LV: difference in right/left ventricular ratio; sBP: systolic blood pressure; UFH: unfractionated heparin; USAT: ultrasound-assisted catheter-directed thrombolysis; VTE: venous thromboemboli						

We advocate a more systematic approach where clinicians and researchers take the leading role of driving this promising field forward using rigorous scientific inquiry. Ideally, thorough preclinical testing, preferably in large, *in vivo* animal models, will precede better-designed clinical safety trials, which will then be followed by randomised clinical trials with long follow-up and clinical endpoints.

Another concern is the cost of catheter-based therapies for PE. Pricing of devices varies greatly and can be very high. Due to the few efficacy data and lack of long-term follow-up, it is currently not possible to determine the cost-effectiveness of these novel catheter-directed therapies.

Conclusions

Catheter-based therapies are promising alternatives in patients suffering from acute PE. Currently, there is only one FDA-approved device for the catheter-based treatment of PE, while all other devices are used off-label. The majority of procedures are performed using CDT, either ultrasound-assisted or in combination with mechanical fragmentation. Aspiration therapy shows promise, but limited data are available. Rheolytic therapy should be used with caution, if at all, due to the high number of associated complications. Much more research into the efficacy, safety and cost-effectiveness of these devices is needed.

Impact on daily practice

We provide an overview of catheter-based therapies of acute PE categorised according to the mechanism of thrombus removal: fragmentation, rheolytic therapy, aspiration or catheter-directed thrombolysis. We found 16 different catheter-based therapies for acute PE, all but one being used off-label. Though catheter-based therapies show promise as a treatment for acute PE, further research into the efficacy, safety and cost-effectiveness of devices is needed.

Funding

Aarhus University Graduate School of Health.

Conflict of interest statement

The authors have no conflicts of interest to declare.

References

The references can be found in the online version of this article.

The supplementary data are published online at:
http://www.pronline.com/eurointervention/129th_issue/277



Supplementary data

References

1. Cohen AT, Agnelli G, Anderson FA, Arcelus JI, Bergqvist D, Brecht JG, Greer IA, Heit JA, Hutchinson JL, Kakkar AK, Mottier D, Oger E, Samama MM, Spannagl M; VTE Impact Assessment Group in Europe (VITAE). Venous thromboembolism (VTE) in Europe. The number of VTE events and associated morbidity and mortality. *Thromb Haemost.* 2007;98:756-64.
2. Goldhaber SZ, Bounameaux H. Pulmonary embolism and deep vein thrombosis. *Lancet.* 2012;379:1835-46.
3. Stein PD, Matta F. Thrombolytic therapy in unstable patients with acute pulmonary embolism: saves lives but underused. *Am J Med.* 2012;125:465-70.
4. Chatterjee S, Chakraborty A, Weinberg I, Kadakia M, Wilensky RL, Sardar P, Kumbhani DJ, Mukherjee D, Jaff MR, Giri J. Thrombolysis for pulmonary embolism and risk of all-cause mortality, major bleeding, and intracranial hemorrhage: a meta-analysis. *JAMA.* 2014;311:2414-21.
5. Goldhaber SZ, Haire WD, Feldstein ML, Miller M, Toltzis R, Smith JL, Taveira da Silva AM, Come PC, Lee RT, Parker JA, et al. Alteplase versus heparin in acute pulmonary embolism: randomised trial assessing right-ventricular function and pulmonary perfusion. *Lancet.* 1993;341:507-11.
6. Meyer G, Vicaut E, Danays T, Agnelli G, Becattini C, Beyer-Westendorf J, Bluhmki E, Bouvaist H, Brenner B, Couturaud F, Dellas C, Empen K, Franca A, Galiè N, Geibel A, Goldhaber SZ, Jimenez D, Kozak M, Kupatt C, Kucher N, Lang IM, Lankeit M, Meneveau N,

Pacouret G, Palazzini M, Petris A, Pruszczyk P, Rugolotto M, Salvi A, Schellong S, Sebbane M, Sobkowicz B, Stefanovic BS, Thiele H, Torbicki A, Verschuren F, Konstantinides SV; PEITHO Investigators. Fibrinolysis for patients with intermediate-risk pulmonary embolism. *N Engl J Med.* 2014;370:1402-11.

7. Kuo WT, Gould MK, Louie JD, Rosenberg JK, Sze DY, Hofmann LV. Catheter-directed therapy for the treatment of massive pulmonary embolism: systematic review and meta-analysis of modern techniques. *J Vasc Interv Radiol.* 2009;20:1431-40.
8. Nakazawa K, Tajima H, Murata S, Kumita SI, Yamamoto T, Tanaka K. Catheter fragmentation of acute massive pulmonary thromboembolism: distal embolisation and pulmonary arterial pressure elevation. *Br J Radiol.* 2008;81:848-54.
9. Schmitz-Rode T, Janssens U, Schild HH, Basche S, Hanrath P, Günther RW. Fragmentation of massive pulmonary embolism using a pigtail rotation catheter. *Chest.* 1998;114:1427-36.
10. Schmitz-Rode T, Janssens U, Duda SH, Erley CM, Günther RW. Massive pulmonary embolism: percutaneous emergency treatment by pigtail rotation catheter. *J Am Coll Cardiol.* 2000;36:375-80.
11. Yoshida M, Inoue I, Kawagoe T, Ishihara M, Shimatani Y, Kurisu S, Kusano KF, Ohe T. Novel percutaneous catheter thrombectomy in acute massive pulmonary embolism: rotational bidirectional thrombectomy (ROBOT). *Catheter Cardiovasc Interv.* 2006;68:112-7.
12. Mohan B, Aslam N, Kumar Mehra A, Takkar Chhabra S, Wander P, Tandon R, Singh Wander G. Impact of catheter fragmentation followed by local intrapulmonary thrombolysis in acute high risk pulmonary embolism as primary therapy. *Indian Heart J.* 2014;66:294-301.

13. Tajima H, Murata S, Kumazaki T, Nakazawa K, Abe Y, Komada Y, Niggemann P, Takayama M, Tanaka K, Takano T. Hybrid treatment of acute massive pulmonary thromboembolism: mechanical fragmentation with a modified rotating pigtail catheter, local fibrinolytic therapy, and clot aspiration followed by systemic fibrinolytic therapy. *Am J Roentgenol.* 2004;183:589-95.
14. Kuo WT, Banerjee A, Kim PS, DeMarco FJ Jr, Levy JR, Facchini FR, Unver K, Bertini MJ, Sista AK, Hall MJ, Rosenberg JK, De Gregorio MA. Pulmonary Embolism Response to Fragmentation, Embolectomy, and Catheter Thrombolysis (PERFECT): Initial Results From a Prospective Multicenter Registry. *Chest.* 2015;148:667-673.
15. Brady AJ, Crake T, Oakley CM. Percutaneous catheter fragmentation and distal dispersion of proximal pulmonary embolus. *Lancet.* 1991;338:1186-9.
16. Dobrow E, Kim P. Endovascular treatment of massive and submassive pulmonary embolism. *Tech Vasc Interv Radiol.* 2014;17:121-6.
17. Barjaktarevic I, Friedman O, Ishak C, Sista A. Catheter-directed clot fragmentation using the Cleaner™ device in a patient presenting with massive pulmonary embolism. *J Radiol Case Rep.* 2014;8:30-6.
18. Biederer J, Charalambous N, Paulsen F, Heller M, Müller-Hülsbeck S. Treatment of acute pulmonary embolism: local effects of three hydrodynamic thrombectomy devices in an ex vivo porcine model. *J Endovasc Ther.* 2006;13:549-60.
19. Chechi T, Vecchio S, Spaziani G, Giuliani G, Giannotti F, Arcangeli C, Rubboli A, Margheri M. Rheolytic thrombectomy in patients with massive and submassive acute pulmonary embolism. *Catheter Cardiovasc Interv.* 2009;73:506-13.

20. Vecchio S, Vittori G, Chechi T, Spaziani G, Lilli A, Giuliani G, Consoli L, Ambrosio G, Margheri M. [Percutaneous rheolytic thrombectomy with AngioJet for pulmonary embolism: methods and results in the experience of a high-volume center]. [Article in Italian]. *G Ital Cardiol (Rome)*. 2008;9:355-63.
21. Zeni PT, Blank BG, Peeler DW. Use of rheolytic thrombectomy in treatment of acute massive pulmonary embolism. *J Vasc Interv Radiol*. 2003;14:1511-5.
22. Nassiri N, Jain A, McPhee D, Mina B, Rosen RJ, Giangola G, Carroccio A, Green RM. Massive and submassive pulmonary embolism: experience with an algorithm for catheter-directed mechanical thrombectomy. *Ann Vasc Surg*. 2012;26:18-24.
23. Bonvini RF, Roffi M, Bounameaux H, Noble S, Müller H, Keller PF, Jolliet P, Sarasin FP, Rutschmann OT, Bendjelid K, Righini M. AngioJet rheolytic thrombectomy in patients presenting with high-risk pulmonary embolism and cardiogenic shock: a feasibility pilot study. *EuroIntervention*. 2013;8:1419-27.
24. Dwarka D, Schwartz SA, Smyth SH, O'Brien MJ. Bradyarrhythmias during use of the AngioJet system. *J Vasc Interv Radiol*. 2006;17:1693-5.
25. Dukkupati R, Yang EH, Adler S, Vintch J. Acute kidney injury caused by intravascular hemolysis after mechanical thrombectomy. *Nat Clin Pract Nephrol*. 2009;5:112-6.
26. Roncon L, Casazza F, Zuin M, Zonzin P, Galli M, Enea I. [Percutaneous treatment of pulmonary embolism: diffusion and use of the technique in Italian interventional cardiology centers. Results of the PETER survey]. [Article in Italian]. *G Ital Cardiol (Rome)*. 2016;17:268-72.

27. Schmitz-Rode T, Kilbinger M, Günther RW. Simulated flow pattern in massive pulmonary embolism: significance for selective intrapulmonary thrombolysis. *Cardiovasc Intervent Radiol.* 1998;21:199-204.
28. Ahmed K, Munawar M, Andina Munawar D, Hartono B. Simple mechanical thrombectomy with intrapulmonary arterial thrombolysis in pulmonary thromboembolism: a small case series. *J Geriatr Cardiol.* 2014;11:349-53.
29. Akin H, Al-Jubouri M, Assi Z, Acino R, Sepanski D, Comerota AJ. Catheter-directed thrombolytic intervention is effective for patients with massive and submassive pulmonary embolism. *Ann Vasc Surg.* 2014;28:1589-94.
30. George B, Wallace EL, Charnigo R, Wingerter KE, Kapadia P, Gurley JC, Smyth SS. A retrospective analysis of catheter-based thrombolytic therapy for acute submassive and massive pulmonary embolism. *Vasc Med.* 2015;20:122-30.
31. Kucher N, Boekstegers P, Müller OJ, Kupatt C, Beyer-Westendorf J, Heitzer T, Tebbe U, Horstkotte J, Muller R, Blessing E, Greif M, Lange P, Hoffmann RT, Werth S, Barmeyer A, Härtel D, Grünwald H, Empen K, Baumgartner I. Randomized, controlled trial of ultrasound-assisted catheter-directed thrombolysis for acute intermediate-risk pulmonary embolism. *Circulation.* 2014;129:479-86.
32. Piazza G, Hohlfelder B, Jaff MR, Ouriel K, Engelhardt TC, Sterling KM, Jones NJ, Gurley JC, Bhatheja R, Kennedy RJ, Goswami N, Natarajan K, Rundback J, Sadiq IR, Liu SK, Bhalla N, Raja LM, Weinstock BS, Cynamon J, Elmasri FF, Garcia MJ, Kumar M, Ayerdi J, Soukas P, Kuo W, Liu PY, Goldhaber SZ; SEATTLE II Investigators. A Prospective, Single-Arm, Multicenter Trial of Ultrasound-Facilitated, Catheter-Directed, Low-Dose Fibrinolysis for

Acute Massive and Submassive Pulmonary Embolism: The SEATTLE II Study. *JACC Cardiovasc Interv.* 2015;8:1382-92.

33. Engelberger RP, Spirk D, Willenberg T, Alatri A, Do DD, Baumgartner I, Kucher N. Ultrasound-assisted versus conventional catheter-directed thrombolysis for acute iliofemoral deep vein thrombosis. *Circ Cardiovasc Interv.* 2015 Jan;8(1).
34. Kabrhel C, Rosovsky R, Channick R, Jaff MR, Weinberg I, Sundt T, Dudzinski DM, Rodriguez-Lopez J, Parry BA, Harshbarger S, Chang Y, Rosenfield K. A Multidisciplinary Pulmonary Embolism Response Team: Initial 30-Month Experience With a Novel Approach to Delivery of Care to Patients With Submassive and Massive Pulmonary Embolism. *Chest.* 2016;150:384-93.
35. Greenfield LJ, Kimmell GO, McCurdy WC 3rd. Transvenous removal of pulmonary emboli by vacuum-cup catheter technique. *J Surg Res.* 1969;9:347-52.
36. Greenfield LJ, Proctor MC, Williams DM, Wakefield TW. Long-term experience with transvenous catheter pulmonary embolectomy. *J Vasc Surg.* 1993;18:450-7; discussion 457-8.
37. Dumantepe M, Teymen B, Akturk U, Seren M. Efficacy of rotational thrombectomy on the mortality of patients with massive and submassive pulmonary embolism. *J Card Surg.* 2015;30:324-32.
38. Liu S, Shi HB, Gu JP, Yang ZQ, Chen L, Lou WS, He X, Zhou WZ, Zhou CG, Zhao LB, Xia JG, Li LS. Massive pulmonary embolism: treatment with the rotarex thrombectomy system. *Cardiovasc Intervent Radiol.* 2010;34:106-13.
39. Mirakhur A, Moriarty J, Kee S. Early clinical experience with the FlowTrievery, a novel

mechanical thrombectomy device, in acute pulmonary thromboembolism. *Journal of Vascular and Interventional Radiology*. 2016;27:S293-S294.

40. Weinberg AS, Dohad S, Ramzy D, Madyoon H, Tapson VF. Clot Extraction With the FlowTriever Device in Acute Massive Pulmonary Embolism. *J Intensive Care Med*. 2016 Sep 6. [Epub ahead of print].
41. Young S, Pritzker M, Rosenberg M. Vacuum-Assisted Thrombectomy of Massive Pulmonary Embolism. *J Vasc Interv Radiol*. 2016;27:1094-6.
42. Al-Hakim R, Park J, Bansal A, Genshaft S, Moriarty JM. Early Experience with AngioVac Aspiration in the Pulmonary Arteries. *J Vasc Interv Radiol*. 2016;27:730-4.
43. Engelberger RP, Kucher N. Ultrasound-assisted thrombolysis for acute pulmonary embolism: a systematic review. *Eur Heart J*. 2014;35:758-64.
44. Müller-Hülsbeck S, Brossmann J, Jahnke T, Grimm J, Reuter M, Bewig B, Heller M. Mechanical thrombectomy of major and massive pulmonary embolism with use of the Amplatz thrombectomy device. *Invest Radiol*. 2001;36:317-22.
45. Stein PD, Alnas M, Beemath A, Patel NR. Outcome of pulmonary embolectomy. *Am J Cardiol*. 2007;99:421-3.
46. Uflacker R, Strange C, Vujic I. Massive pulmonary embolism: preliminary results of treatment with the Amplatz thrombectomy device. *J Vasc Interv Radiol*. 1996;7:519-28.
47. Fava M, Loyola S. Applications of percutaneous mechanical thrombectomy in pulmonary embolism. *Tech Vasc Interv Radiol*. 2003;6:53-8.

48. Fava M, Loyola S, Huete I. Massive pulmonary embolism: treatment with the hydrolyser thrombectomy catheter. *J Vasc Interv Radiol.* 2000;11:1159-64.
49. Michalis LK, Tsetis DK, Rees MR. Case report: percutaneous removal of pulmonary artery thrombus in a patient with massive pulmonary embolism using the hydrolyser catheter: the first human experience. *Clin Radiol.* 1997;52:158-61.
50. Reekers JA, Baarslag HJ, Koolen MG, Van Delden O, van Beek EJ. Mechanical thrombectomy for early treatment of massive pulmonary embolism. *Cardiovasc Intervent Radiol.* 2003;26:246-50.