

# Carotid artery stenting with a new-generation double-mesh stent in three high-volume Italian centres: 12-month follow-up results



Roberto Nerla<sup>1\*</sup>, MD; Antonio Micari<sup>1</sup>, MD, PhD; Fausto Castriota<sup>1</sup>, MD; Eligio Micciché<sup>1</sup>, MD; Maria Antonella Ruffino<sup>2</sup>, MD; Gianmarco de Donato<sup>3</sup>, MD; Carlo Setacci<sup>3</sup>, MD; Alberto Cremonesi<sup>1</sup>, MD

1. Cardiovascular Department, Humanitas Gavazzeni, Bergamo, Italy; 2. Vascular Radiology, Città della Salute e della Scienza, AOU San Giovanni Battista, Turin, Italy; 3. Vascular and Endovascular Surgery Unit, University of Siena, Siena, Italy

## Introduction

The Roadsaver<sup>®</sup> carotid artery stent (Terumo Corp., Tokyo, Japan) has been introduced into clinical practice to increase plaque coverage during carotid artery stenting (CAS) thanks to its dual-layer design. Preliminary results have shown a good short-term clinical outcome<sup>1-3</sup>. However, longer-term clinical follow-up data are currently lacking. In addition, although some concern has been raised about the presence of a larger quantity of foreign material (double mesh) inside the carotid artery, no data are available about the Roadsaver stent restenosis rate.

## Methods

Our study population comprised all consecutive patients who underwent CAS and received a Roadsaver stent between October 2014 and October 2015 in three high-volume Italian centres performing CAS.

Patients were scheduled to undergo clinical evaluations at baseline, at 24 hours from the procedure and at 30 days after CAS. Routine clinical follow-up was performed by telephone interviews

and, whenever the physician felt it necessary, the patient was seen at an outpatient clinic. Doppler ultrasound was scheduled to be performed at six and at 12 months by the referral doctors. Data and documents were collected through regular phone calls by the assigned physicians. All patients received dual antiplatelet therapy (aspirin+clopidogrel) for one month.

As to clinical endpoints, transient ischaemic attack (TIA) was defined as focal brain ischaemia with resolution of symptoms within 24 hours after onset. Stroke was defined as a new neurological deficit of sudden onset with focal symptoms and signs consistent with focal ischaemia lasting at least 24 hours in the absence of primary haemorrhage, which was not explained by other causes. Stroke was considered minor if the neurological deficit resolved completely within 30 days or did not lead to a functional impairment in daily activities.

Doppler evidence of restenosis was considered in the presence of peak systolic velocity (PSV) values above 250 cm/s. The decision about how to treat in-stent restenosis was left to the individual operators.

\*Corresponding author: Cardiovascular Department, Humanitas Gavazzeni, Via Mauro Gavazzeni, 21, 24125 Bergamo, Italy.  
E-mail: robertonerla83@gmail.com

## Results

The Roadsaver registry included 150 patients (age 74±8, 75% male) treated in the three institutions (**Table 1**). As previously reported, most treated patients were asymptomatic (n=107, 71%).

Data completeness at follow-up was 100%. In the whole population there were three deaths (2%) not related to the index procedure (**Table 2**). No major or minor cerebrovascular events were reported at 12-month follow-up.

**Table 1. Main clinical and angiographic characteristics of the study population.**

	Overall (n=150)
Age (years)	74±8
Male sex, n (%)	113 (75)
Symptomatic carotid artery disease, n (%)	43 (29)
Hypertension, n (%)	124 (83)
Diabetes mellitus, n (%)	41 (27)
Current or prior cigarette smoking, n (%)	83 (55)
Prior myocardial infarction, n (%)	27 (18)
Previous TEA, n (%)	15 (10)
Bilateral carotid artery disease, n (%)	47 (31)
Type III aortic arch, %	11%
Bovine arch, %	21%
Severe tortuosity, n (%)	16 (11)
Severe calcification, n (%)	13 (9)
TEA: thromboendarterectomy	

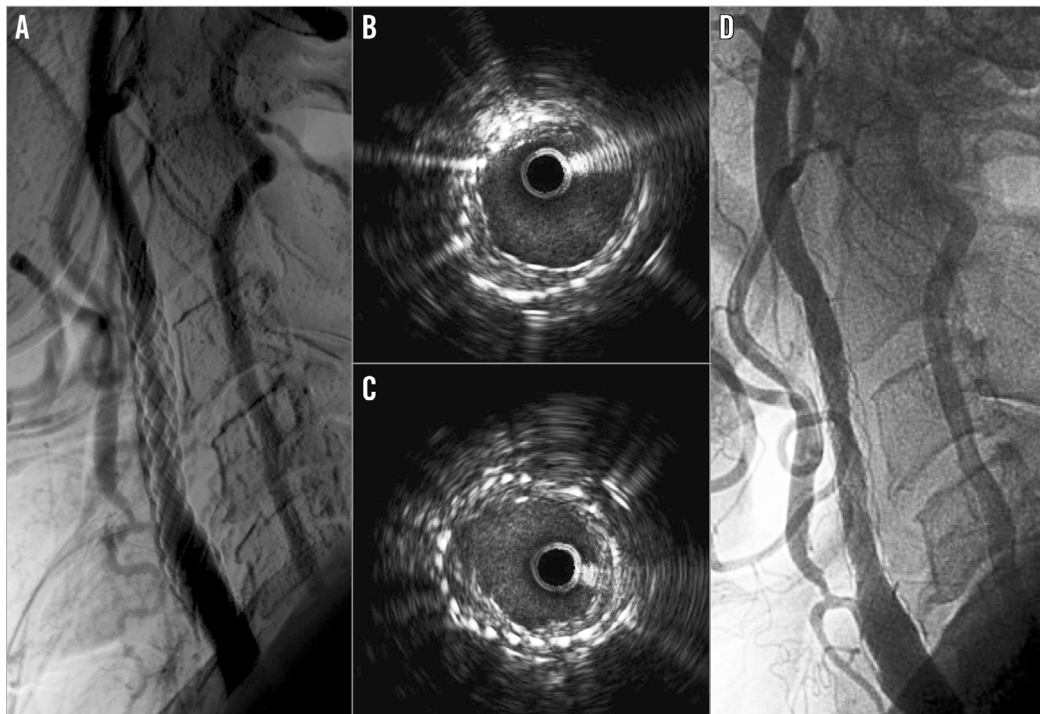
**Table 2. Clinical events and Doppler evidence of restenosis at 12-month follow-up in the study population.**

Patient	Clinical event	Restenosis at duplex	Description
# 19	Death	–	Complicated cardiac surgery (post-AVR bleeding)
# 31	–	Yes	Asymptomatic restenosis. Treated with DCB
# 49	Death	–	Cerebral haemorrhage
# 69	–	Yes	Asymptomatic restenosis. Treated with 2 <sup>nd</sup> stent
# 79	Death	–	AMI complicated by CS
# 141	–	Yes	Asymptomatic restenosis. Medical therapy

AMI: acute myocardial infarction; AVR: aortic valve replacement; CS: cardiogenic shock; DCB: drug-coated balloon

All patients underwent Doppler ultrasound follow-up after CAS. Of these, three patients showed significant increase of Doppler PSV values (i.e., >250 cm/sec). They underwent angiography confirming stent restenosis; two of them were treated with a second angioplasty procedure, and one with medical therapy (**Table 2**). Of note, in one case IVUS evaluation showed a significant plaque proliferation between the two layers of struts (**Figure 1**). The patient was treated with a drug-coated balloon angioplasty. His latest clinical and Doppler follow-up (24 months) confirmed a good result.

External carotid artery (ECA) patency was reported in all patients.



**Figure 1.** Follow-up of a patient previously treated with a Roadsaver carotid artery stent. Angiographic evidence of right internal carotid restenosis (A). IVUS evaluation depicted plaque neoproliferation between the two layers of struts (B, C). Finally, it was decided to treat the patient with a drug-coated balloon angioplasty after positioning a distal filter; the final result was good (D).

## Discussion

Double-mesh carotid stents have somewhat revolutionised CAS. Since their introduction into clinical practice, clinical results in the short term have been good<sup>2,3</sup>, with a low incidence of delayed embolic events and new ipsilateral magnetic resonance imaging ischaemic brain lesions<sup>4</sup>. The greatest part of its anti-embolic effect has been related to a higher capability of plaque containment, as confirmed by optical coherence tomography studies showing a relatively low rate of plaque prolapse<sup>3,5</sup>. Despite being used more and more in clinical practice, Roadsaver long-term results are still unknown.

In our multicentre and multidisciplinary case series of patients, we showed favourable long-term clinical outcomes: we reported no cerebrovascular events. All deaths were convincingly not related to the stenting procedures, thus reflecting the global higher cardiovascular risk of our study population. In addition, Doppler results showed a restenosis rate which does not seem different from other stents<sup>6</sup>, although no definite answer can be provided by our non-randomised observational study. Of interest, all restenosis cases were asymptomatic. The possible explanations for this are merely speculative. However, it is worth mentioning that in one case of restenosis we performed intravascular imaging, showing plaque growth between the two layers of struts. As is known, in-stent restenosis has been classically attributed to neointimal hyperplasia and vascular remodelling<sup>7</sup>. The use of a Roadsaver double-mesh stent could be associated with a novel pattern of restenosis, with plaque growth happening in the not negligible space between the two layers, but still trapped by the inner line of struts, which could be associated with a lower embolic risk. Future studies will have to assess this novel pattern better and clarify its relation with clinical outcome.

## Limitations

Many limitations of the present report should be acknowledged. First, it is an observational study reporting clinical practice and leaving the standard practice of single institutions (and operators) unchanged. Second, the lack of an external adjudication committee might be responsible for the lack of accuracy in detecting clinical events. However, the low number of patients and events could be related to the prevalence of asymptomatic disease in the original study population.

## Conclusions

The use of the Roadsaver stent in high-risk clinical or anatomical conditions is associated with good short and midterm results. Of note, this stent does not seem to be associated with a higher rate of in-stent restenosis at 12-month follow-up. However, prospective studies with an external adjudication committee aimed

at comparing its performance with traditional carotid stents are warranted in order to confirm this result.

## Impact on daily practice

The Roadsaver double-mesh carotid stent has shown good procedural and short-term results. Our data confirm the efficacy of this stent at 12-month follow-up and they do not suggest any concern about a higher risk of restenosis up to one year from the revascularisation procedure.

## Conflict of interest statement

F. Castriota, A. Micari and A. Cremonesi have previously received consultancy fees from Terumo but not in relation to the present article. The other authors have no conflicts of interest to declare.

## References

1. Hopf-Jensen S, Marques L, Preiß M, Müller-Hülsbeck S. Initial clinical experience with the micromesh Roadsaver carotid artery stent for the treatment of patients with symptomatic carotid artery disease. *J Endovasc Ther*. 2015;22:220-5.
2. Bosiers M, Deloose K, Torsello G, Scheinert D, Maene L, Peeters P, Müller-Hülsbeck S, Sievert H, Langhoff R, Bosiers M, Setacci C. The CLEAR-ROAD study: evaluation of a new dual layer micromesh stent system for the carotid artery. *EuroIntervention*. 2016;12:e671-6.
3. Nerla R, Castriota F, Micari A, Sbarzaglia P, Secco GG, Ruffino MA, de Donato G, Setacci C, Cremonesi A. Carotid artery stenting with a new-generation double-mesh stent in three high-volume Italian centres: clinical results of a multidisciplinary approach. *EuroIntervention*. 2016;12:e677-83.
4. Ruffino MA, Faletti R, Bergamasco L, Fonio P, Righi D. Incidence of New Ischaemic Brain Lesions After Carotid Artery Stenting with the Micromesh Roadsaver Carotid Artery Stent: A Prospective Single-Centre Study. *Cardiovasc Intervent Radiol*. 2016;39:1541-9.
5. Umamoto T, de Donato G, Pacchioni A, Reimers B, Ferrante G, Isobe M, Setacci C. Optical coherence tomography assessment of newgeneration mesh-covered stents after carotid stenting. *EuroIntervention*. 2017;13:1347-54.
6. Brott TG, Howard G, Roubin GS, Meschia JF, Mackey A, Brooks W, Moore WS, Hill MD, Mantese VA, Clark WM, Timaran CH, Heck D, Leimgruber PP, Sheffet AJ, Howard VJ, Chaturvedi S, Lal BK, Voeks JH, Hobson RW 2nd; CREST Investigators. Long-Term Results of Stenting versus Endarterectomy for Carotid Artery Stenosis. *N Engl J Med*. 2016;374:1021-31.
7. Goel SA, Guo LW, Liu B, Kent KC. Mechanisms of post-intervention arterial remodelling. *Cardiovasc Res*. 2012;96:363-71.