

AMPLATZER versus Figulla occluder for transcatheter patent foramen ovale closure



Daniela Trabattoni¹, MD, FESC; Achille Gaspardone^{2*}, MD, MPhil, FESC; Gregory A. Sgueglia², MD, PhD; Franco Fabbicchi¹, MD; Gaetano Gioffrè², MD; Piero Montorsi¹, MD; Giuseppe Calligaris¹, MD; Maria Iamele², MD; Antonella De Santis², MD; Antonio L. Bartorelli¹, MD, FESC

1. Centro Cardiologico "Monzino" IRCCS and Department of Cardiovascular Sciences, University of Milan, Milan, Italy;
2. U.O.C. di Cardiologia, Ospedale Sant'Eugenio, Rome, Italy

KEYWORDS

- closure devices
- patent foramen ovale
- percutaneous closure

Abstract

Aims: The aim of this observational study was to compare acute and 12-month results of percutaneous closure of patent foramen ovale (PFO) with two occluder devices.

Methods and results: Between June 2007 and October 2014, 406 consecutive patients (48.1±13.3 years, 243 women) underwent percutaneous PFO closure with either the AMPLATZER (n=179) or the Figulla (n=227) device after a stroke or a transient ischaemic attack ascribed to the PFO. A right-to-left shunt grade >1 was previously detected in all patients and atrial septal aneurysm was present in 111 (27.5%) patients. Patients were followed up with a contrast transthoracic echocardiogram and clinically at 24 hours, six months, and 12 months after the procedure. A high procedural success was observed in both groups. Despite a trend towards a higher incidence of acute residual shunt immediately after device deployment among Figulla occluder patients, a residual grade ≥2 right-to-left shunt was observed in 4.5% of patients, independently of the device used for PFO closure. The only difference reported after Figulla device implantation was a lower rate of supraventricular arrhythmias (9% vs. 17%, p=0.02).

Conclusions: According to this two-centre study, PFO closure appears safe and effective with the Figulla occluder as well as with the AMPLATZER device.

*Corresponding author: U.O.C. di Cardiologia, Sant'Eugenio Hospital, Piazzale dell'Umanesimo, 10, 00144 Rome, Italy.
E-mail: a_gaspardone@yahoo.com

Introduction

In patients with presumed paradoxical embolism through a patent foramen ovale (PFO) who are at increased risk of recurrent thromboembolic events, transcatheter closure of the atrial communication represents an alternative to lifelong medical treatment. Percutaneous PFO closure has been shown to be safe and feasible with several occluder devices implementing different technologies based on an umbrella, a disc or a bioabsorbable design¹⁻⁶. Several studies have previously compared the performance of PFO occluders based on markedly different fabric⁷⁻¹⁰. Whether slight differences in the structure and design of the occluder might have a significant impact on the outcomes related to the procedure is unknown. Therefore, the aim of this study was to compare procedural and clinical results up to one year of the two most diffuse nitinol PFO closure devices, which differ in their braiding techniques and by the quantity of the meshwork material present on the left atrial side.

Methods

An observational registry was run in two Italian centres (Milan and Rome) to recruit all consecutive patients treated with either the AMPLATZER™ PFO Occluder (n=179) (St. Jude Medical, St. Paul, MN, USA) or the Occlutech® Figulla® device (n=227) (Occlutech GmbH, Jena, Germany) between June 2007 and October 2014.

SCREENING PROTOCOL AND DEFINITIONS

A careful screening protocol including accurate clinical history, transthoracic echocardiography (TTE), coagulation analysis and a complete laboratory screening for thrombophilia (antithrombin III, anticardiolipin, antiphospholipid antibodies, lupus anticoagulant, protein C and S, homocysteine; genetic tests for factor V Leiden and factor II) was carried out in all enrolled patients. Thrombophilia was defined by ≥ 1 abnormal test result. A brain magnetic resonance (MR) or computed tomography (CT) scan was routinely performed in all patients. All patients underwent transoesophageal echocardiography (TEE) prior to the PFO closure procedure. Right-to-left-shunt (RLS) was semi-quantitatively graded according to the number of microbubbles detected in the left atrium after crossing the interatrial septum on a still frame during the first five cardiac cycles of contrast entering the right atrium. Grading was as follows: Grade 0: no bubbles; Grade 1 (trivial): < 10 scattered bubbles seen in the left heart; Grade 2 (moderate): obvious shunt with > 10 bubbles seen in the left heart; Grade 3 (large): > 20 bubbles with partial or complete opacification of the left heart¹¹. Maximal RLS severity was used for the analysis. Only patients with RLS > 1 were enrolled. All echocardiographic pre- and post-closure examinations were reviewed by two independent experts blinded to the device used. The criteria for atrial septal aneurysm were a diameter of the base ≥ 15 mm and a total excursion of the septum ≥ 10 mm¹². Moreover, according to our centres' protocol, all patients underwent arrhythmia screening with 24-hour Holter monitoring, before indication to PFO closure.

PFO CLOSURE DEVICES

The AMPLATZER PFO Occluder is a self-expanding double-disc device composed of a 0.005-inch nitinol wire with a polyester fabric patch sewn into both discs (**Figure 1**). The device has a flexible and stretchable 3 mm waist and one hub on each disc. The PFO Occluder is available in sizes (left atrial side) 18, 25, 30 and 35 mm.

The Occlutech Figulla device consists of a single layer nitinol wire mesh forming two flexible retention discs (2 mm diameter smaller on the left side) with a hub on the right side only (**Figure 1**). The discs are connected by a flexible and stretchable 3 mm waist in the centre. The left atrial disc is a single flat layer covered by an ultrathin polyethylene terephthalate patch. The size of the Figulla device is determined by the diameter of the two discs with the following available configurations: 16/18, 23/25, 27/30 and 31/35 mm.




Figure 1. Graphical representation of the AMPLATZER PFO Occluder and the Occlutech Figulla device, differing in terms of their braiding techniques and by the quantity of the meshwork material present on the left atrial side.

PROCEDURAL PROTOCOL

Transcatheter PFO closure was performed by standard technique according to the manufacturer's instructions. Under echocardiographic guidance, allowing a careful assessment of the fossa ovalis anatomy and the presence or absence of atrial septum aneurysm, a 0035" J-tipped guidewire was positioned through the atrial septum into the upper pulmonary vein. Intracardiac ultrasound guidance (Ultra ICE™; Boston Scientific, Marlborough, MA, USA), avoiding patient intubation, was the procedural guiding strategy used in Milan, while all PFO closures carried out in Rome were performed with patients in light sedation under fluoroscopic and TEE monitoring.

In all cases, an appropriately sized occluder was loaded into a long 8-10 Fr introducer sheath and advanced by pushing the delivery cable to the tip of the sheath positioned in the left atrium. The choice of occluder depended on the alternating availability of the devices and physician preference prior to the procedure. Owing to a policy ensuring a per patient availability of PFO occluders, the interventional cardiologist on duty for PFO closure had to request occluder availability for the day of the procedure. The selection was unrelated to the patient and it was never possible to choose another device type during the procedure. Under fluoroscopic guidance in a left anterior oblique projection and

echo guidance, the left atrial disc was deployed and pulled back gently against the atrial septum. Using gentle tension on the delivery cable, the sheath was pulled back and pushed forward and the right atrial disc was deployed. Ultrasound evaluation was performed after device deployment to check the adequate positioning of the device, possible obstruction to systemic or pulmonary venous return and impairment of the atrioventricular valves. The device was then released.

MEDICATION PROTOCOL

Patients received heparin 70 IU/kg at the beginning of the procedure followed by further boluses in order to maintain an activated clotting time >200 seconds. Aspirin (100 mg/day) was started at least 24 hours before the procedure and continued for six months after PFO closure, while clopidogrel was administered immediately after the procedure and continued for three months. Antibiotic prophylaxis was given before the procedure and then for five days.

FOLLOW-UP AND ENDPOINT DEFINITION

To assess possible differences in relatively early events, all patients were followed up clinically at one, six and 12 months after the procedure. Major adverse events, including death, cryptogenic stroke or transient ischaemic attack (TIA) were individually recorded. Cryptogenic stroke was defined as a clinical syndrome consisting of focal or global neurologic deficit, associated with a related lesion on a CT or MR scan, that had no known underlying cause despite a thorough evaluation with currently available diagnostic procedures. Cryptogenic TIA was defined as a clinical syndrome consisting of a transient episode of neurological dysfunction caused by focal brain, spinal cord, or

retinal ischaemia without acute infarction as assessed by CT or MR scan¹³. Electrocardiographically documented arrhythmias during a planned Holter monitoring at one-month follow-up were also prospectively registered. A contrast TTE was performed within 24 hours and at six-month follow-up, and blindly evaluated by two independent operators, to assess PFO occluder position and evaluate residual RLS (inter-observer difference <0.5%).

STATISTICAL ANALYSIS

Continuous data with a normal distribution, according to the Kolmogorov-Smirnov test, are reported as means with standard deviations and were compared with the Student's t-test. Data with a non-normal distribution are reported as median (interquartile range) and were compared with the Mann-Whitney U test. Categorical data were compared by Pearson's chi-square test or Fisher's exact test as appropriate, and are presented as frequencies and/or percentages. Inter-observer agreement was assessed by the Pearson's correlation test. A two-sided p-value ≤ 0.05 was required for statistical significance.

We have waived an *a priori* sample size calculation because of the difficulties of building up such an estimation owing to the similarity of the two devices and the generally low rate of adverse events after transcatheter PFO closure.

Results

BASELINE

A flow chart of the study is shown in **Figure 2**. Overall, 406 patients were enrolled (48±13.3 years, 243 women). An AMPLATZER occluder was implanted in 179 patients and a Figulla device was implanted in the remaining 227 patients (**Figure 3**). Their baseline characteristics are listed in **Table 1**. The groups were similar

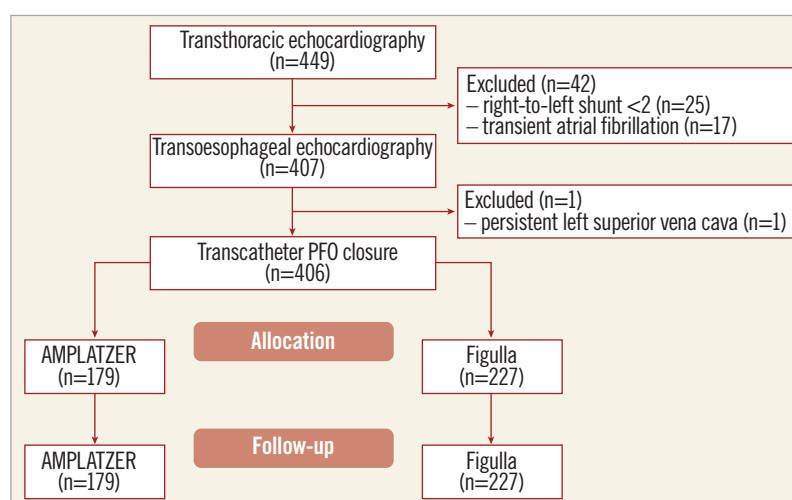


Figure 2. Flow chart of the study. Initially, 449 patients with a clinical history potentially consistent with patent foramen ovale (PFO) were screened by transthoracic echocardiography. Of these, 42 were excluded because of an excessively mild right-to-left shunt (n=25) or because of an electrocardiographic demonstration of episodes of atrial fibrillation (n=17). After TEE to confirm the diagnosis of PFO, one more patient was excluded because of persistent superior vena cava. Overall, 406 patients underwent transcatheter PFO closure, 179 with the AMPLATZER PFO Occluder and 227 with the Occlutech Figulla device.

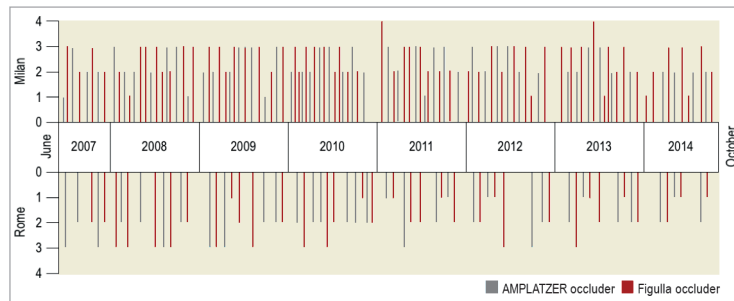


Figure 3. Time distribution in each centre of the transcatheter patent foramen ovale closure procedures using either the AMPLATZER occluder or the Figulla device showing the balance between groups and centres and over time. Overall, 406 patients underwent transcatheter patent foramen ovale closure with the study devices between June 2007 and October 2014. An AMPLATZER occluder or a Figulla device was variably used in 111 and 155 patients, respectively, in Milan, and in 68 and 72 patients, respectively, in Rome.

in terms of age, gender, interatrial shunting grade and septal anatomy, clinical indication to PFO closure, device size and hospital site. There were no differences concerning cardiovascular risk factors except for a higher incidence of hypertension and smoking habit among patients treated with an AMPLATZER occluder device. A previous clinical ischaemic stroke was present in 34% and a transient ischaemic attack in 66% of the patients. Anatomic evaluation of the fossa ovalis showed coexisting septal atrial aneurysm in 111 (27.5%) patients.

PROCEDURE OUTCOME

Cumulative procedural success was 99.5%; there was a 25 mm AMPLATZER device late displacement and a 16/18 mm Figulla embolisation, successfully managed via percutaneous device retrieval. Device embolisation occurred in both cases in a patient with a tunnel-like PFO and incomplete alignment of the device discs to the atrial septum after implantation, thus favouring

occluder dislocation and embolisation. Periprocedural complications are reported in **Table 2**. Notably, no ischaemic events occurred during or after the procedure.

ECHOCARDIOGRAPHIC FOLLOW-UP

Overall agreement between echocardiographers was rather high ($r=0.94$). A contrast TTE was performed in all patients within 24 hours after the procedure showing residual shunting in 89 (22%) patients overall, 43 (24%) in the AMPLATZER group and 46 (20%) in the Figulla group (**Figure 4**). All devices were correctly positioned and no thrombi were detected. Six-month contrast TTE was performed in all patients and showed a reduction of

Table 1. Baseline characteristics of the study patients.

	All (n=406)	AMPLATZER (n=179)	Figulla (n=227)	p-value
Women	243 (60%)	116 (65%)	127 (56%)	0.10
Age (years)	48.1±13.3	47.6±13.7	47.51±2.9	0.53
Active smoking	48 (12%)	31 (17.5%)	17 (7.5%)	0.01
Hypertension	81 (20%)	49 (27.5%)	32 (14%)	0.01
Hyperlipidaemia	134 (33%)	61 (34%)	73 (32%)	0.30
Diabetes mellitus	4 (1%)	2 (1%)	2 (1%)	0.81
Previous ischaemic stroke	138 (34%)	60 (33.5%)	78 (34.5%)	0.86
Previous transient ischaemic attack	268 (66%)	119 (66.5%)	149 (65.5%)	0.86
Recurrent ischaemic events	132 (32.5%)	57 (32%)	75 (33%)	0.80
Thrombophilia	69 (17%)	31 (17.5%)	38 (17%)	0.88
Valsalva right-to-left shunt Grade 2	118 (29%)	50 (28%)	68 (30%)	0.82
Valsalva right-to-left shunt Grade 3	288 (71%)	129 (72%)	159 (70%)	0.66
Atrial septal aneurysm	111 (27.5%)	53 (29.5%)	58 (25.5%)	0.36
Atrial septal bulging (mm)	4±5	5±5	4±4	0.26

Table 2. Procedural data and periprocedural complications.

		All (n=406)	AMPLATZER (n=179)	Figulla (n=227)	p-value
Procedural time (min)		29.41±1.9	30.6±10.7	28.9±10.2	0.87
Fluoroscopic time (min)		4.6±2.3	4.9±2.2	4.3±2.3	0.47
Interventional centre	Milan	266 (66%)	111 (62%)	155 (68%)	0.18
	Rome	140 (34%)	68 (38%)	72 (32%)	
Device size					
AMPLATZER	18 mm	41 (10%)	41 (23%)	–	–
	25 mm	113 (28%)	113 (63%)	–	–
	30 mm	14 (3.5%)	14 (8%)	–	–
	35 mm	11 (2.5%)	11 (6%)	–	–
Figulla	16/18 mm	73 (18%)	–	73 (32%)	–
	23/25 mm	118 (29%)	–	118 (52%)	–
	27/30 mm	36 (9%)	–	36 (16%)	–
	31/35 mm	0 (0%)	–	0 (0%)	–
Device embolisation		2 (0.5%)	1 (0.6%)	1 (0.4%)	0.59
Vascular complications		6 (1.5%)	4 (2.2%)	2 (0.9%)	0.48
Pseudoaneurysm		3 (0.7%)	1 (0.6%)	2 (0.9%)	0.84
Arteriovenous fistula		2 (0.5%)	2 (1.1%)	0 (0%)	0.38
Major haematoma (>5 cm)		1 (0.2%)	1 (0.6%)	0 (0%)	0.91

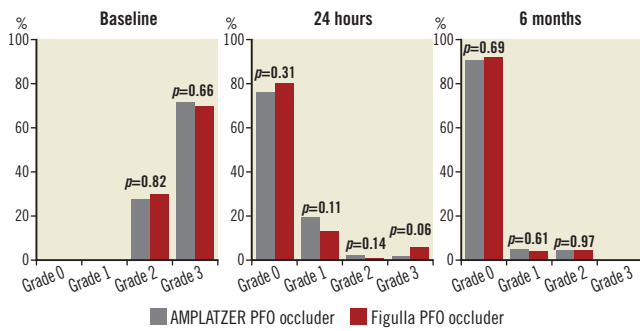


Figure 4. Comparison of right-to-left shunt as assessed by echocardiography in the two study groups at baseline, 24-hour and six-month follow-up following transcatheter patent foramen ovale closure. At baseline, all patients had a Grade 2 or 3 shunt. At 24 hours, different degrees of residual shunting were found in 89 (22%) patients overall, 43 (24%) in the AMPLATZER group and 46 (20%) in the Figulla group. At six-month follow-up, echocardiography showed a reduction of shunting and complete closure in 26 out of the 43 AMPLATZER patients and in 27 out of the 46 Figulla patients ($p=0.96$). No patients had Grade 3 shunt anymore. Residual shunts at six months were Grade 1 in nine (5%) AMPLATZER patients and in nine (4%) Figulla patients ($p=0.61$) and Grade 2 in eight (4.5%) AMPLATZER patients and 10 (4.5%) Figulla patients ($p=0.97$).

shunting and complete closure in 26 out of the 43 AMPLATZER patients and in 27 out of the 46 Figulla patients ($p=0.96$). Residual shunts at six months were Grade 1 in nine (5%) AMPLATZER patients and in nine (4%) Figulla patients and Grade 2 in eight (4.5%) AMPLATZER patients and 10 (4.5%) Figulla patients (**Figure 4**). **Table 3** shows baseline and procedural data in patients with and without residual left-to-right shunt at six-month follow-up. The two groups of patients did not differ significantly according to any of the explored variables. Patients with residual shunts at six months continued aspirin treatment and were scheduled for yearly follow-up thereafter.

CLINICAL FOLLOW-UP

No patient was lost to follow-up. No death, recurrent embolic event or aortic erosion occurred during follow-up (**Table 4**). Atrial fibrillation was observed in four AMPLATZER patients and one Figulla patient immediately after device deployment or during the first 30 days; accordingly, supraventricular arrhythmias were more frequently observed in the AMPLATZER group (17%) compared to the Figulla group (9%) ($p=0.02$). Two thirds of arrhythmic events were periprocedural or occurred during hospital stay, whereas the remaining were observed during the one-month Holter monitoring. In all cases, arrhythmias were resolved by pharmacological treatment.

Discussion

This study is the largest clinical and contrast-enhanced echocardiography comparative assessment of two similar devices for

Table 3. Baseline and procedural data in patients with and without residual left-to-right shunt at six-month follow-up.

		Residual shunt (n=36)	No shunt (n=370)	p-value
Women		17 (47%)	226 (61%)	0.11
Age (years)		47±13.3	47.8±13.3	0.67
Active smoking		5 (14%)	40 (12%)	0.57
Hypertension		8 (22%)	73 (20%)	0.72
Hyperlipidaemia		11 (31%)	123 (33%)	0.74
Diabetes mellitus		1 (3%)	3 (8%)	0.25
Recurrent ischaemic events		10 (27%)	122 (33%)	0.52
Baseline Valsalva right-to-left shunt Grade 2		11 (31%)	107 (29%)	0.84
Baseline Valsalva right-to-left shunt Grade 3		25 (69%)	263 (71%)	
Atrial septal aneurysm		12 (33%)	99 (27%)	0.39
Atrial septal bulging (mm)		5±5	4±3	0.15
Procedural time (min)		31.6±11.4	28.8±9.7	0.23
Fluoroscopic time (min)		4.3±2.1	4.6±2.4	0.42
Interventional centre		Milan	21 (58%)	0.34
		Rome	15 (42%)	
Device size	AMPLATZER	18 mm	5 (14%)	0.86
		25 mm	8 (22%)	
		30 mm	2 (5.5%)	
		35 mm	2 (5.5%)	
	Figulla	16/18 mm	6 (17%)	
		23/25 mm	9 (25%)	
		27/30 mm	4 (11%)	
		31/35 mm	0 (0%)	

transcatheter PFO closure, namely the AMPLATZER and Figulla occluders, with a 12-month follow-up. Our results show that high procedural success with a very low complication rate may be achieved using both these devices.

Despite the value of PFO percutaneous treatment for the prevention of thromboembolic events in patients with cryptogenic stroke^{14,15}, some procedural and device-related complications may occur. Newer devices, with a lower left disc metallic mass and easier deployment and retrieval have been designed and tested, each with clinical and technical advantages and disadvantages.

Table 4. Clinical follow-up.

	All (n=406)	AMPLATZER (n=179)	Figulla (n=227)	p-value
Death	0 (0%)	0 (0%)	0 (0%)	-
Ischaemic stroke	0 (0%)	0 (0%)	0 (0%)	-
Transient ischaemic attack	0 (0%)	0 (0%)	0 (0%)	-
Aortic erosion	0 (0%)	0 (0%)	0 (0%)	-
Supraventricular arrhythmias	50 (12.5%)	30 (17%)	20 (9%)	0.02
Paroxysmal atrial fibrillation	5 (1.2%)	4 (2.2%)	1 (0.4%)	0.24

The Figulla device has been designed with these specific novel technological properties, giving the device lower metallic mesh on the left atrial side and higher flexibility, allowing ideal septal alignment¹⁶. Krizanac et al showed good biocompatibility with rapid and complete neoendothelialisation in a swine model, and the first clinical trial by the same group showed the feasibility and safety of transcatheter PFO closure with the Figulla device^{4,17}. A previous single-centre case control study by Saguner et al reported, in a small sample comparison between Figulla (n=20) and AMPLATZER (n=20) devices in PFO treatment, a 15% incidence of procedural complications in the Figulla group¹⁸. In particular, the Figulla PFO device was associated with a higher residual shunt incidence at six months compared to the AMPLATZER (39% vs. 0%). However, these data were not confirmed by Aytemir et al, who evaluated early to midterm results after Figulla device implantation in 85 patients with PFO and in 58 patients with atrial septal defect closure, showing no residual shunt in the PFO group¹⁹. In another similar study by Van den Branden et al, among 82 consecutive patients who underwent PFO (n=48) and atrial septal defect (n=34) closure, the reported procedural success was 100% with a low complication rate²⁰. Previous studies comparing rather distinct PFO devices differ in assessed endpoints and follow-up duration, thus allowing limited comparison with our study⁷⁻¹⁰.

In a previous study, Pac et al reported similar procedural success and complication rates between Figulla and AMPLATZER occluders in a single-centre study enrolling 75 consecutive patients with atrial septal defect²¹. Additionally, they reported more periprocedural residual shunt that disappeared after six months. Percutaneous PFO closure has a success rate close to 100%, eliminating the RLS shunt in 90% of patients^{1,22,23}. However, the presence of moderate to severe residual shunts has been described in 2-10% of patients^{1,24,25} and related to an inadequate design of the device, multiple septal fenestration or interatrial septal aneurysm. In our series, significant residual shunt following PFO closure was observed in 4% of all patients, occurring equally among the AMPLATZER and Figulla device groups. The clinical importance of these residual shunts has been previously elucidated and, while small residual shunts do not appear to have clinical significance²⁶, the presence of more than a moderate grade shunt after PFO closure appears to be related to increased risk of recurrent stroke during the follow-up². Grade 1 shunts during Valsalva manoeuvre immediately after closure device implantation resolved spontaneously during the follow-up period in 75% and 70% of cases in the AMPLATZER and the Figulla group, respectively. Similarly, grade ≥ 2 shunts showed a 35% reduction in the Figulla group but no changes in the AMPLATZER group. We believe that the progressive reduction of RLS severity and its resolution over time after Figulla device deployment might be explained by differences in design between the two devices, with the Figulla occluder requiring a more complete endothelialisation process to avoid shunting from the right to left atrium. Notably, according to our data, none

of the patients or procedural characteristics seems to help identify those at risk of having a residual shunt.

The increased prevalence of supraventricular arrhythmias observed among AMPLATZER patients may likewise be explained by the differences in design between the two devices or may simply be due to chance. Certainly, Holter monitoring is an inherently limited method for arrhythmia assessment but there is no other practical or ethical way to assess real-world PFO patients without specific risk factors or clues pointing towards supraventricular arrhythmias. Moreover, it has been previously shown that arrhythmias represent a constitutional feature of the PFO syndrome²⁷ and that PFO closure using different occluder devices does not appear *per se* to be an inductor of post-procedural arrhythmias²⁸.

Limitations

Lack of randomisation represents the main limitation of this study. However, the choice of the device was unsystematic being due to the alternating availability of the devices and physician preference prior to the procedure. Additionally, despite the fact that the main baseline characteristics were substantially comparable in the two groups of patients, hypertension and active smoking were more frequent in the AMPLATZER group. The duration of follow-up was relatively short to assess any differences in events with a low rate of occurrence such as major adverse clinical events. Differences in supraventricular arrhythmias between the two groups were found on a single Holter monitoring at one month and it cannot be excluded that a longer follow-up would provide different findings. Moreover, TEE would possibly have improved the detection of residual RLS, although with higher costs, higher complexity and higher risks as trade-off. However, our study was exploratory and not specifically directed to the assessment of residual shunt; TEE may not be superior to TTE in detecting RLS due to difficulties in performing an appropriate Valsalva manoeuvre. Among the several anatomic features that have been associated with PFO outcomes in cryptogenic stroke, our study only reports on atrial septal aneurysm and atrial septal bulging. However, there is currently no evidence that a specific high-risk anatomic feature excludes the role of PFO in cryptogenic stroke. On the contrary, in such circumstances PFO closure is even more compelling. However, it should be acknowledged that the unmatched prevalence among the study groups of high-risk anatomic characteristics other than those reported may unevenly increase the risk of events, especially in the long term. Finally, lack of an *a priori* sample size calculation is another limitation of our study, as previously stated.

Conclusions

In our study, transcatheter percutaneous PFO closure was achieved safely and effectively with the AMPLATZER and the Figulla devices. Acute procedural success was high. Clinical results at 12-month follow-up were comparable between the two groups, and no relevant differences in residual shunt were found as evaluated by contrast TTE.

Impact on daily practice

In patients with presumed paradoxical embolism through a patent foramen ovale (PFO) who are at increased risk of recurrent thromboembolic events, transcatheter closure of the atrial communication represents a valid alternative to lifelong medical treatment. Percutaneous PFO closure has been shown to be safe and effective with several occluders based on different technologies. We compared the two most used nitinol PFO closure devices, which differ by their braiding techniques and quantity of the meshwork material present. Good results in terms of safety and efficacy achieved with both the AMPLATZER and the Figulla occluders suggest that differences in the structure and design of the devices do not have a significant impact on clinical success.

Conflict of interest statement

The authors have no conflicts of interest to declare.

References

1. Windecker S, Wahl A, Chatterjee T, Garachemani A, Eberli FR, Sciler C, Meier B. Percutaneous closure of patent foramen ovale in patients with paradoxical embolism: long-term risk of recurrent thromboembolic events. *Circulation*. 2000;101:893-8.
2. Wahl A, Meier B, Haxel B, Nedeltchev K, Arnold M, Eicher E, Sturzenegger M, Seiler C, Mattle HP, Windecker S. Prognosis after percutaneous closure of patent foramen ovale for paradoxical embolism. *Neurology*. 2001;57:1330-2.
3. Onorato E, Melzi G, Casilli F, Pedon L, Rigatelli G, Carrozza A, Maiolino P, Zanchetta M, Morandi E, Angeli S, Anzola GP. Patent foramen ovale with paradoxical embolism: mid-term results of transcatheter closure in 256 patients. *J Interv Cardiol*. 2003;16:43-50.
4. Krizanac F, Sievert H, Pfeiffer D, Konorza T, Ferrari M, Figulla HR. Clinical evaluation of a novel occluder device (Occlutech) for percutaneous transcatheter closure of patent foramen ovale (PFO). *Clin Res Cardiol*. 2008;97:872-7.
5. Post MC, Van Deyk K, Budts W. Percutaneous closure of a patent foramen ovale: single center experience using different types of devices and mid-term outcome. *Acta Cardiol*. 2005;60:515-9.
6. Braun M, Glied V, Boscheri A, Schoen S, Gahn G, Reichmann H, Haass M, Schraeder R, Strasser RH. Transcatheter closure of patent foramen ovale (PFO) in patients with paradoxical embolism. Periprocedural safety and mid-term follow-up results of three different device occluder systems. *Eur Heart J*. 2004;25:424-30.
7. Musto C, Cifarelli A, Fiorilli R, De Felice F, Parma A, Nazzaro MS, Guerra E, Fiorilli F, Violini R. Comparison between the new Gore septal and Amplatzer devices for transcatheter closure of patent foramen ovale. Short- and mid-term clinical and echocardiographic outcomes. *Circ J*. 2013;77:2922-7.
8. Hornung M, Bertog SC, Franke J, Id D, Taaffe M, Wunderlich N, Vaskelyte L, Hofmann I, Sievert H. Long-term results of a randomized trial comparing three different devices for percutaneous closure of a patent foramen ovale. *Eur Heart J*. 2013;34:3362-9.
9. Darsaklis K, Freixa X, Asgar A, Ibrahim R, Basmadjian A, DeGuise P, Garceau P. A novel system for transcatheter closure of patent foramen ovale: clinical and echocardiographic outcome comparison with other contemporary devices. *Can J Cardiol*. 2014;30:639-46.
10. Aral M, Mullen M. The Flatstent versus the conventional umbrella devices in the percutaneous closure of patent foramen ovale. *Catheter Cardiovasc Interv*. 2015;85:1058-65.
11. Mullen MJ, Hildick-Smith D, De Giovanni JV, Duke C, Hillis WS, Morrison WL, Jux C. BioSTAR Evaluation Study (BEST): a prospective, multicenter, phase I clinical trial to evaluate the feasibility, efficacy, and safety of the BioSTAR bioabsorbable septal repair implant for the closure of atrial-level shunts. *Circulation*. 2006;114:1962-7.
12. Mügge A, Daniel WG, Angermann C, Spes C, Khandheria BK, Kronzon I, Freedberg RS, Keren A, Denning K, Engberding R, et al. Atrial septal aneurysm in adult patients. A multicenter study using transthoracic and transesophageal echocardiography. *Circulation*. 1995;91:2785-92.
13. Pristipino C, Anzola GP, Ballerini L, Bartorelli A, Cecconi M, Chessa M, Donti A, Gaspardone A, Neri G, Onorato E, Palareti G, Rakar S, Rigatelli G, Santoro G, Toni D, Ussia GP, Violini R; Italian Society of Invasive Cardiology (SICI-GISE); Italian Stroke Association (ISA-AIS); Italian Association of Hospital Neurologists, Neuroradiologists, Neurosurgeons (SNO); Congenital Heart Disease Study Group of Italian Society Of Cardiology; Italian Association Of Hospital Cardiologists (ANMCO); Italian Society Of Pediatric Cardiology (SICP); Italian Society of Cardiovascular Echography (SIEC); Italian Society of Hemostasis and Thrombosis (SISSET). Management of patients with patent foramen ovale and cryptogenic stroke: a collaborative, multidisciplinary, position paper. *Catheter Cardiovasc Interv*. 2013;82:E38-51.
14. Capodanno D, Milazzo G, Vitale L, Di Stefano D, Di Salvo M, Grasso C, Tamburino C. Updating the evidence on patent foramen ovale closure versus medical therapy in patients with cryptogenic stroke: a systematic review and comprehensive meta-analysis of 2,303 patients from three randomised trials and 2,231 patients from 11 observational studies. *EuroIntervention*. 2014;9:1342-9.
15. Kent DM, Dahabreh IJ, Ruthazer R, Furlan AJ, Reisman M, Carroll JD, Saver JL, Smalling RW, Jüni P, Mattle HP, Meier B, Thaler DE. Device Closure of Patent Foramen Ovale After Stroke: Pooled Analysis of Completed Randomized Trials. *J Am Coll Cardiol*. 2016;67:907-17.
16. Haas NA, Happel CM, Soetemann DB, Hanslik A, Moysich A, Kececioglu D, Laser KT. Optimal septum alignment of the Figulla Flex occluder to the atrial septum in patients with secundum atrial septal defects. *EuroIntervention*. 2016;11:1153-60.
17. Krizanac F, Sigler M, Figulla HR. Transvenous closure of patent foramen ovale. Preliminary results with a new self-expanding

nitinol wire mesh in a Swine model. *Cardiol Res Pract.* 2009;2009:943453.

18. Saguner AM, Wahl A, Praz F, de Marchi S, Mattle HP, Cook S, Windecker S, Meier B. Figulla PFO Occluder versus Amplatzer PFO Occluder for percutaneous closure of patent foramen ovale. *Catheter Cardiovasc Interv.* 2011;77:709-14.

19. Aytemir K, Oto A, Ozkutlu S, Kaya EB, Canpolat U, Yorgun H, Sahiner L, Kabakci G. Early-mid term follow-up results of percutaneous closure of the interatrial septal defects with Occlutech Figulla devices: a single center experience. *J Interv Cardiol.* 2012;25:375-81.

20. Van Den Branden BJ, Post MC, Plokker HW, Ten Berg JM, Suttorp MJ. Percutaneous atrial shunt closure using the novel Occlutech Figulla device: 6-month efficacy and safety. *J Interv Cardiol.* 2011;24:264-70.

21. Pac A, Polat TB, Cetin I, Oflaz MB, Balli S. Figulla ASD occluder versus Amplatzer Septal Occluder: a comparative study on validation of a novel device for percutaneous closure of atrial septal defects. *J Interv Cardiol.* 2009;22:489-95.

22. Greutmann M, Greutmann-Yantiri M, Kretschmar O, Senn O, Roffi M, Jenni R, Luescher TF, Eberli FR. Percutaneous PFO closure with Amplatzer PFO Occluder: predictors of residual shunts at 6 months follow-up. *Congenit Heart Dis.* 2009;4:252-7.

23. Bruch L, Parsi A, Grad MO, Rux S, Burmeister T, Krebs H, Kleber FX. Transcatheter closure of interatrial communications for secondary prevention of paradoxical embolism: single center experience. *Circulation.* 2002;105:2845-8.

24. Diaz T, Cubeddu RJ, Rengifo-Moreno PA, Cruz-Gonzalez I, Solis-Martin J, Buonanno FS, Inglessis I, Palacios IF. Management of residual shunts after initial percutaneous patent foramen ovale closure: a single center experience with immediate and long-term follow-up. *Catheter Cardiovasc Interv.* 2010;76:145-50.

25. Schwerzmann M, Windecker S, Wahl A, Nedeltchev K, Mattle HP, Seiler C, Meier B. Implantation of a second closure device in patients with residual shunt after percutaneous closure of patent foramen ovale. *Catheter Cardiovasc Interv.* 2004;63:490-5.

26. Spies C, Strasheim R, Timmermanns I, Schraeder R. Patent foramen ovale closure in patients with cryptogenic thromboembolic events using the Cardia PFO Occluder. *Eur Heart J.* 2006;27:365-71.

27. Berthet K, Lavergne T, Cohen A, Guize L, Bousser MG, Le Heuzey JY, Amarenco P. Significant association of atrial vulnerability with atrial septal abnormalities in young patients with ischemic stroke of unknown cause. *Stroke.* 2000;31:398-403.

28. Gaspardone A, Giardina A, Iamele M, Gioffrè G, Polzoni M, Lamberti F, Remoli R, Sgueglia GA, Papa M, Iani C. Effect of percutaneous closure of patent foramen ovale on post-procedural arrhythmias. *J Am Coll Cardiol.* 2013;62:2449-50.