

A curly case: dissecting giant arteriovenous anomaly - left main coronary artery shunting to superior vena cava

Maarten de Mulder^{1,2*}, MD, PhD; Tadek R. Hendriks³, MD; Peter L. de Jong⁴, MD, PhD; Alexander J.J. IJsselmuiden¹, MD, PhD

1. Department of Cardiology, Albert Schweitzer Hospital, Dordrecht, The Netherlands; 2. Department of Cardiology, Thoraxcenter, Erasmus University MC, Rotterdam, The Netherlands; 3. Department of Radiology, Albert Schweitzer Hospital, Dordrecht, The Netherlands; 4. Department of Thoracic Surgery, Thoraxcenter, Erasmus University MC, Rotterdam, The Netherlands

This paper also includes supplementary data published online at: http://www.pconline.com/eurointervention/89th_issue/132

A 52-year-old female patient with an unremarkable history was admitted to our institution with a non-ST-elevation myocardial infarction (NSTEMI) and underwent coronary angiography (CAG) the following day.

The right coronary artery (RCA) was normal. The left main coronary artery (LMCA) was very large, had a tortuous course and seemed to fistulise to the right atrium (RA). The left anterior descending (LAD) and circumflex (Cx) also originated from this LMCA and had only minor wall irregularities. During the procedure, a dissection emerged proximal in this arteriovenous fistula, large ST elevations appeared, the patient developed ventricular fibrillation and was resuscitated (**Figure 1A**). As regular coronary stents were too small, the dissection was covered with an Express™ 6.0×18 mm stent (Boston Scientific, Marlborough, MA, USA) provided by the interventional radiologist, after which the patient stabilised. Several days later, the patient was extubated and a coronary CT scan demonstrated that the LMCA anomaly had a maximum diameter of 14 mm and shunts to the superior vena cava (SVC), approximately 3 cm above the RA (**Figure 1B**). The chest pain at presentation was probably the first symptom of a spontaneous dissection. In the absence of a trigger, the “steal phenomenon” appears less likely. In order to avoid recurrence, on day 12 the patient underwent a thoracotomy where the fistula was closed (**Figure 1C**). Thirty-four days after initial admission the patient was discharged in a good condition.

Coronary fistulas are rare and may be prone to dissection due to their ectatic course. In this case close cooperation between cardiologist, radiologist and cardiac surgeon was essential.

Conflict of interest statement

The authors have no conflicts of interest to declare.

Supplementary data

Moving image 1. Coronary angiogram demonstrating the arteriovenous fistula with blushing of contrast into the superior vena cava and right atrium, catheter tip into the left main coronary artery with dissection flap, and left anterior descending and circumflex coronary artery.

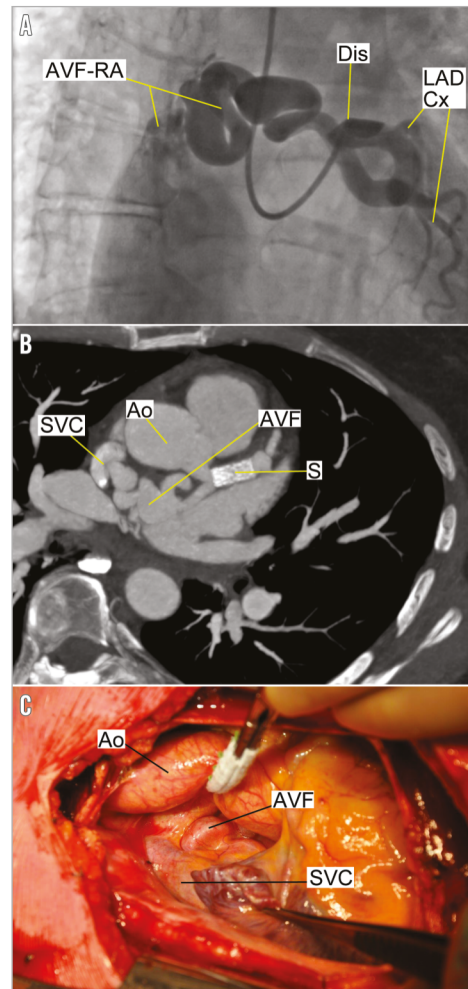


Figure 1. Visualisation of the arteriovenous anomaly. A) Angiogram demonstrating the arteriovenous fistula with blushing of contrast into the superior vena cava and right atrium (AVF-RA), catheter into the left main coronary artery with dissection flap (Dis), and left anterior descending (LAD), and circumflex (Cx) coronary artery (Moving image 1). B) CT angiography with the arteriovenous fistula (AVF) with stent (S), superior vena cava (SVC) and aorta (Ao). C) Perioperative view of the aorta (Ao), the arteriovenous fistula (AVF) and superior vena cava (SVC).

*Corresponding author: Department of Cardiology, Albert Schweitzer Hospital, P.O. Box 444, 3300 AK Dordrecht, The Netherlands. E-mail: m.demulder@erasmusmc.nl